12559.
United States
College of Physicians of Philadelphia

CLASS NO.

Lewis Library

Sam'l Lewis M.D.

Presented by

Pathological Soc. of Phila.

Digitized by the Internet Archive
in 2014

https://archive.org/details/transactionsofpa1718path

# TRANSACTIONS

OF THE

# PATHOLOGICAL SOCIETY

# OF PHILADELPHIA.

VOLUME XVII.

*CONTAINING THE REPORT OF THE PROCEEDINGS FROM OCTOBER, 1893, TO MAY, 1895.*

EDITED BY

ALFRED STENGEL, M.D.,

RECORDER OF THE SOCIETY.

COLLEGE OF PHYSICIANS
LIBRARY.
DEC 9 1896
OF PHILADELPHIA.

PHILADELPHIA:
PRINTED FOR THE SOCIETY BY WM. J. DORNAN.
1896.

2813

# CONTENTS.

List of Former Presidents . . . . . iv
List of Officers and Committees elected 1893 . . . v
List of Officers and Committees elected 1894 . . . vi
List of Members . . . . . vii
List of Corresponding Members . . . . . xvii

Addresses of Presidents . . . . . 1
Diseases, etc., of the Osseous System . . . . . 7
Diseases, etc., of the Digestive System . . . . . 9
Diseases, etc., of the Vascular and Hæmatopoietic Systems 71
Diseases, etc., of the Organs of Respiration . . . . 114
Diseases, etc., of the Genito-urinary System . . . . 123
Diseases, etc., of the Nervous System . . . . . 159
Tumors not otherwise Classified . . . . . 172
Miscellaneous . . . . . 209

12559

# FORMER PRESIDENTS.

SAMUEL D. GROSS, M.D., LL.D., D.C.L. Oxon., LL.D. Cantab., elected 1857.

RENÉ LA ROCHE, M.D., elected 1858.

ALFRED STILLÉ, M.D., elected 1859, '61, and '62.

EDWARD HARTSHORNE, M.D., elected 1860 and '63.

J. M. DA COSTA, M.D., elected 1864, '65 and '66.

JOHN H. PACKARD, M.D., elected 1867 and '68.

S. WEIR MITCHELL, M.D., elected 1869.

JOHN ASHHURST, Jr., M.D., elected 1870.

JAMES H. HUTCHINSON, M.D., elected 1871 and '72.

WILLIAM PEPPER, M.D., elected 1873.

H. LENOX HODGE, M.D., elected 1876.

S. W. GROSS, M.D , elected 1879.

JAMES TYSON, M.D., elected 1882 and '83.

E. O. SHAKESPEARE, M.D., elected 1884.

J. C. WILSON, M.D., elected 1885 and '86.

F. P. HENRY, M.D., elected 1887 and '88.

HENRY F. FORMAD, M.D., elected 1889 and '90.

ARTHUR V. MEIGS, M.D., elected 1891 and '92.

J. H. MUSSER, M.D., elected 1893 and '94.

# OFFICERS AND COMMITTEES

OF THE

# PATHOLOGICAL SOCIETY OF PHILADELPHIA.

(Elected at the annual meeting, October 12, 1893.)

---

**President.**

J. H. MUSSER, M.D.,

**Vice-Presidents.**

E. L. VANSANT, M.D.,
E. LAPLACE, M.D.,
F. A. PACKARD, M.D.,
JOHN B. DEAVER, M.D.

**Secretary.**

CHARLES W. BURR, M.D.

**Treasurer.**

T. S. WESTCOTT, M.D.

**Recorder.**

ALFRED STENGEL, M.D.

**Curator.**

A. A. ESHNER, M.D.

**Business Committee.**

H. W. CATTELL, M.D.,
W. C. POSEY, M.D.,
L. WOLFF, M.D.,
H. R. WHARTON, M.D.,
J. A. SCOTT, M.D.

**Committee on Morbid Growths.**

J. McFARLAND, M.D.,
H. W. CATTELL, M.D.,
M. V. BALL, M.D.,
ALFRED STENGEL, M.D.,
C. W. BURR, M.D.,
H. B. CARPENTER, M.D.,
W. M. L. COPLIN, M.D.

**Committee on Publication.**

F. A. PACKARD, M.D.,
J. P. C. GRIFFITH, M.D.,
F. P. HENRY, M.D.,
JAMES TYSON, M.D.

# OFFICERS AND COMMITTEES

OF THE

# PATHOLOGICAL SOCIETY OF PHILADELPHIA.

(Elected at the annual meeting, October 11, 1894.)

---

**President.**

J. H. MUSSER, M.D.

**Vice-Presidents.**

J. B. DEAVER, M.D.,
J. GUITÉRAS, M.D.,
W. E. HUGHES, M.D.,
H. R. WHARTON, M.D.

**Secretary.**

A. A. ESHNER, M.D.

**Treasurer.**

T. S. WESTCOTT, M.D.

**Recorder.**

ALFRED STENGEL, M.D.

**Curator.**

D. RIESMAN, M.D.

**Business Committee.**

C. W. BURR, M.D.,
W. S. CARTER, M.D.,
S. M. HAMILL, M.D.,
A. HAND, Jr., M.D.,
J. A. SCOTT, M.D.

**Committee on Morbid Growths.**

W. S. CARTER, M.D.,
J. McFARLAND, M.D.,
ALFRED STENGEL, M.D.

**Committee on Publication.**

J. DALAND, M.D.,
F. P. HENRY, M.D.,
F. A. PACKARD, M.D.,
JAMES TYSON, M.D.

# LIST OF MEMBERS.

Members marked O. M. are those originating the Society.

ELECTED.

1894 Abbott, A. C., 218 St. Mark's Square.
1887 Allyn, Herman B., N. E. corner Fortieth and Locust Streets.
1889 Anders, J. M., 1603 Walnut Street.
1894 Arnold, John P., 3906 Walnut Street.
1861 Ashhurst, John, Jr., 2000 DeLancey Place.
1891 Ashton, Thomas G., 1533 Pine Street.
1895 Ashton, William E., 2011 Walnut Street.

1887 Baker, G. F., 1818 Spruce Street.
1891 Ball, M. V., 529 Pine Street.
1888 Balliet, Tilghman M., 3705 Powelton Avenue.
1883 Barton, Isaac, 111 North Sixteenth Street.
1885 Beates, Henry, Jr., 1504 Walnut Street.
1871 Bennett, Wm. H., 2105 Spruce Street.
1887 Berens, Bernard, 2002 Chestnut Street.
1894 Bevan, D., 1015 South Third Street.
1894 Beyea, H. D., 237 South Thirteenth Street.
1892 Birney, D. B., 1810 DeLancey Place.
1893 Bochroch, Max H., 968 North Eighth Street.
1886 Bodamer, George A., 1507 Girard Avenue.
1892 Boger, John A., 2213 North Broad Street.
1857 Boker, Charles S., 229 South Thirteenth Street. (O. M.)
1895 Bolton, B. Meade, Room 715, City Hall.
1895 Bolling, Robert H., Chestnut Hill, Phila.
1893 Boyer, H. P., 1338 Spruce Street.
1896 Booth, Arthur W., Episcopal Hospital.
1857 Brinton, John H., 1423 Spruce Street. (O. M.)
1895 Brubaker, A. P., 105 North Thirty-fourth Street.
1893 Bryan, J. Roberts, 4200 Chestnut Street.
1887 Burr, Charles W., 1327 Spruce Street.

ELECTED.

1893 Carpenter, H. B., 1523 Locust Street.
1893 Carter, W. S., 221 South Thirty-sixth Street.
1887 Cattell, H. W., 3455 Woodland Avenue.
1887 Chrystie, Walter, Bryn Mawr, Pennsylvania.
1866 Cleemann, Richard A., 2135 Spruce Street.
1872 Cohen, J. Solis, 1431 Walnut Street.
1883 Cohen, S. Solis, 219 South Seventeenth Street.
1896 Coley, Thomas Luther, 704 Franklin Street.
1890 Coplin, W. M. L., 310 Catharine Street.
1871 Curtin, Roland G., 22 South Eighteenth Street.

1894 Da Costa, J. Chalmers, 2050 Locust Street.
1857 Da Costa, J. M., 1700 Walnut Street. (O. M.)
1885 Daland, Judson, 319 South Eighteenth Street.
1857 Darrach, James, 5020 Green Street, Germantown. (O. M.)
1890 Davis, C. N., 1931 Spruce Street.
1882 Davis, G. G., 255 South Sixteenth Street.
1893 Davisson, Alexander H., 2024 Pine Street.
1895 Donnellan, P. S., 1028 Spruce Street.
1894 Dougherty, S. W., German Hospital.
1889 Deaver, H. C., 1629 Oxford Street.
1885 Deaver, J. B., 1634 Walnut Street.
1882 Dercum, F. X., 810 North Broad Street.
1888 Downes, Andrew J., 1725 Girard Avenue.
1889 Downs, Norton, 102 West Walnut Lane, Germantown.
1877 Drysdale, T. M., 1305 Locust Street.
1866 Duer, Edward L., 1606 Locust Street.
1876 Dulles, C. W., 4101 Walnut Street.
1883 Dunmire, G. B., 1618 Spruce Street.
1860 Dunton, W. R., 5059 Germantown Avenue, Germantown.

1896 Edsall, David, 330 South Sixteenth Street.
1891 Eshner, A. A., 224 South Sixteenth Street.

1893 Farr, W. W., 5800 Green Street, Germantown.
1892 Fenn, William B., 4417 Smick Street, Manayunk.
1881 Fenton, T. H., 1319 Spruce Street.
1857 Fischer, Emil, 729 North Sixth Street. (O. M.)
1876 Fisher, Henry M., 317 South Twelfth Street.
1869 Ford, William H., 1622 Summer Street.

ELECTED

1894 Fox, L. Webster, 1304 Walnut Street.
1886 Freeman, W. J., 1720 Locust Street.
1889 Frese, Carl, German Hospital.
1895 Frazier, Charles Harrison, 133 South Eighteenth Street.
1880 French, M. S., 1437 Spruce Street.
1894 French, Samuel, Plymouth, Pa.
1890 Friebis, George, 1906 Chestnut Street.
1896 Fritz, Clarence H., 3932 Brown Street.
1885 Fussell, M. H., 189 Green Lane, Manayunk.

1895 Garitee, C. J., Episcopal Hospital.
1894 Gaylord, H. R., 4048 Chestnut Street.
1870 Getchell, Frank H., 1432 Spruce Street.
1894 Girvin, John H., 3912 Walnut Street.
1890 Gleason, E. Baldwin, 41 South Nineteenth Street.
1882 Godey, H. E., N. E. corner Nineteenth and Spruce Streets.
1886 Goodell, W. Constantine, 300 South Thirteenth Street.
1890 Grayson, C. P., 251 South Sixteenth Street.
1867 Grier, Matthew J., 1531 Spruce Street.
1883 Griffith, J. P. C., 123 South Eighteenth Street.
1894 Grove, J. H., 1504 Arch Street.
1874 Guitéras, John, 130 South South Thirty-ninth Street.
1890 Gummey, Frank P., 4774 Main Street, Germantown.

1884 Haehnlen, W. F., 1616 Walnut Street.
1893 Hamill, S. M., 1822 Spruce Street.
1893 Hand, Alfred, Jr., 211 South Seventeenth Street.
1885 Hare, Hobart A., 222 South Fifteenth Street.
1890 Hartzell, M. B., 3634 Chestnut Street.
1873 Hearn, W. Joseph, 1120 Walnut Street.
1870 Henry, Frederick P., 1635 Locust Street.
1880 Hewson, Addinell, Jr., 1508 Pine Street.
1896 Henry, John N., Children's Hospital, Twenty-second and Walnut Streets.
1894 Hiller, Hiram M., 350 South Sixteenth Street.
1894 Hughes, George M., 241 North Eighteenth Street.
1882 Hughes, W. E., 3726 Baring Street.

1890 Izard, William, Sixth and Penn Streets, Camden, New Jersey.

ELECTED

1890 Jamison, W. B., S. E. corner Fortieth and Brown Streets.
1890 Jarrett, Henry, Camden, New Jersey.
1895 Johnston, John A., National Soldiers' Home, Virginia.
1895 Jopson, J. H., 334 South Sixteenth Street.
1885 Jurist, L. J., 918 North Broad Street.

1895 Kelly, A. O. J., 1934 Pine Street.
1890 Ketcham, S. Rush, 1708 Green Street.
1888 Kirby, Ellwood, 1202 Spruce Street.
1894 Kirkbride, Thomas S., Jr., 1406 Spruce Street.
1890 Kneass, Samuel S., 261 South Fifteenth Street.
1895 Krusen, Wilmer, 158 North Twentieth Street.
1892 Kyle, D. Braden, 1517 Walnut Street.

1893 Lainé, D. T., 129 South Fifteenth Street.
1890 Laplace, Ernest, 1828 South Rittenhouse Square.
1894 Leach, W. W., 2118 Spruce Street.
1869 Leaman, Henry, 828 North Broad Street.
1888 Leidy, Joseph, 1319 Locust Street.
1887 Leopold, Isaac, 1520 Franklin Street.
1868 Lewis, Francis W., 2016 Spruce Street.
1875 Lewis, Morris J., 1316 Locust Street.
1894 Lincoln, Clarence W., 2520 Columbia Avenue.
1893 Lindsay, John, 340 South Fifteenth Street.
1886 Lloyd, James Hendrie, 3910 Walnut Street.
1894 Loeb, Ludwig, 1337 North Seventh Street.
1886 Longaker, D., 652 North Eighth Street.
1875 Longstreth, Morris, 1416 Spruce Street.

1887 Martin, Edward, 415 South Fifteenth Street.
1892 Massey, Frank, 2218 Pine Street.
1880 McClellan, George, 1352 Spruce Street.
1892 McFarland, J., 1314 Franklin Street.
1894 McKee, James H., 1519 Poplar Street.
1890 McKelway, George I., 1612 Locust Street.
1894 McLeod, George, Episcopal Hospital.
1864 Mears, J. Ewing, 1429 Walnut Street.
1873 Meigs, Arthur V., 1322 Walnut Street.
1882 Miller, D. J. M., 345 South Eighteenth Street.
1878 Mills, C. K., 1909 Chestnut Street.

ELECTED.

1884 Mitchell, J. K., 256 South Fifteenth Street.
1893 Mitcheson, R. S. J., 1522 North Fifteenth Street.
1896 Modell, D. A., 242 Fairmount Avenue.
1857 Morehouse, George R., 2033 Walnut Street. (O. M.)
1885 Morrison, William H., Holmesburg, Pennsylvania.
1887 Morton, S. W., 113 South Twentieth Street.
1890 Muehleck, G. A., 343 Wharton Street.
1869 Müller, August F., 4753 Green Street, Germantown.
1880 Musser, J. H., 1927 Chestnut Street.

1879 Neff, J. S., S. W. corner Twenty-third and Spruce Streets.
1894 Newcomet, W. S., 3229 Powelton Avenue.
1894 Noble, Charles P., 1637 North Broad Street.
1861 Norris, William F., 1530 Locust Street.

1894 O'Malley, James, 1104 Jackson Street.

1885 Packard, F. A., 110 South Eighteenth Street.
1893 Packard, F. R., 26 South Eighteenth Street.
1857 Packard, John H., 1926 Spruce Street. (O. M.)
1892 Pearce, F. S., 1407 Locust Street.
1896 Pease, H. D., 3700 Walnut Street.
1890 Pennock, W. J., 1407 North Seventeenth Street.
1891 Penrose, Charles B., 1331 Spruce Street.
1865 Pepper, William, 1811 Spruce Street.
1895 Perkins, F. M., 1428 Pine Street.
1885 Piersol, G. A., 4722 Chester Avenue.
1894 Pitfield, Robert L., 4788 Main Street, Germantown.
1893 Posey, W. C., 1829 Chestnut Street.
1890 Potts, C. S., 1712 Wallace Street.
1889 Price, Joseph, 241 North Eighteenth Street.

1885 Randall, B. A., 1806 Chestnut Street.
1894 Reckefus, C. H., 506 North Sixth Street.
1885 Reed, Boardman, Atlantic City, New Jersey.
1894 Rhein, J. H., 1330 Spruce Street.
1894 Riesman, David, 801 North Sixth Street.
1891 Ring, G. O., 1442 North Thirteenth Street.
1876 Roberts, John B., 1627 Walnut Street.
1884 Robertson, W. E., 912 North Fourth Street.

ELECTED.

1889 Robinson, William Duffield, 2012 Mount Vernon Street.
1891 Rosenthal, E., 517 Pine Street.
1894 Ross, George, German Hospital.

1896 Sailer, Joseph, 1924 Chestnut Street.
1894 Sangree, E. B., Nashville, Tenn.
1867 Santee, Eugene J., 605 North Eleventh Street.
1890 Sartain, Paul J., 212 West Logan Square.
1895 Schamberg, J. F., 831 North Broad Street.
1882 de Schweinitz, G. E., 1401 Locust Street.
1890 Scott, J. A., 121 South Eighteenth Street.
1874 Seiler, Carl, 1523 Chestnut Street.
1885 Shober, J. B., 112 South Seventeenth Street.
1889 Shoemaker, Harvey, 109 South Twentieth Street.
1895 Shumway, Edward A., 1640 Green Street.
1868 Sinkler, Wharton, 1606 Walnut Street.
1881 Skillern, P. G., 241 South Thirteenth Street.
1881 Skillern, S. R., 3509 Baring Street.
1894 Smith, Lawrence S., 133 South Eighteenth Street.
1894 Spellissy, Joseph, 736 Pine Street.
1896 Spiller, William G., 332 South Forty-second Street.
1890 Stahl, B. F., 1502 Arch Street.
1895 Steel, J. D., 4504 Chester Avenue.
1889 Stengel, Alfred, 332 South Seventeenth Street.
1889 Stevens, Arthur A., 318 South Sixteenth Street.
1886 Stewart, David D., 106 South Seventeenth Street.
1896 Stewart, Alonzo H., 250 North Twelfth Street.
1857 Stillé, Alfred, 3900 Spruce Street. (O. M.)
1884 Stritmatter, I. P., 999 North Sixth Street.
1869 Stryker, Samuel S., 3821 Walnut Street.
1894 Swan, John, 807 North Forty-first Street.

1895 Taylor, A. E., 334 South Sixteenth Street.
1894 Thomas, W. Hersey, Presbyterian Hospital.
1894 Thomson, Archibald G., 1426 Walnut Street.
1868 Thomson, William, 1426 Walnut Street.
1892 Toulmin, H. B., 4009 Chestnut Street.
1863 Tyson, James, 1506 Spruce Street.
1890 Tyson, T. Mellor, 1506 Spruce Street.
1892 Tunis, J. P., 129 South Eighteenth Street.

ELECTED.

1895 Vanderwoort, C. A., 3250 North Fifteenth Street.
1887 Vansant, Eugene L., 1929 Chestnut Street.

1891 Wallace, James, 121 North Sixteenth Street.
1890 Warder, Charles B., 1401 North Sixteenth Street.
1874 Warder, W. H., 1212 North Broad Street.
1895 Wendell, W. G., 4126 Chester Avenue.
1887 Westcott, T. S., 108 North Nineteenth Street.
1885 Wharton, H. R., 1725 Spruce Street.
1893 White, F., Elwyn, Pennsylvania.
1873 White, J. William, 1810 South Rittenhouse Square.
1893 Whiting, A. D., 1223 Spruce Street.
1868 Willard, De Forest, 1601 Walnut Street.
1889 Wilmarth, A. W., State Hospital for the Insane, Norristown.
1869 Wilson, James C., 1437 Walnut Street.
1891 Wilson, Samuel M., 1517 Arch Street.
1891 Wilson, W. R., 112 South Twentieth Street.
1895 Witmer, A. F., 322 South Fifteenth Street.
1890 Wolff, L., 333 South Twelfth Street.
1890 Wood, A. C., 214 South Fifteenth Street.
1865 Woods, D. Flavel, 1501 Spruce Street.

1892 Ziegler, Jacob L., Mt. Joy, Lancaster County, Pennsylvania.
1895 Zimmerman, Mason W., 1633 Chestnut Street.

## NON-RESIDENT MEMBERS.

Ashhurst, W. W., Chihuahua, Mexico.
Baines, A. B., Jr., 3013 Easton Avenue, St. Louis, Mo.
Breinig, P. B., Bethlehem, Pa.
Brooke, Benjamin, Jr., U. S. A.
Cerna, D., Galveston, Texas.
Dock, George, Ann Arbor, Mich.
Dunn, T. D., West Chester, Pa.
Edwards, W. A., San Diego, California.
Egbert, Joseph P., Wayne, Delaware County, Pa.
Eskridge, J. T., Denver, Col.
Fox, J. M., Torresdale, Pa.
Hamaker, W. D., Meadville, Pa.
Hamann, C. A., 517 Euclid Avenue, Cleveland, Ohio.
Harrison, W. H., Harrisburg, Pa.
Hatch, John L., 2010 Fifth Avenue, New York City.
Hileman, J. B., Altoona, Pa.
Hunt, James Ramsay,
Jamar, John H., Elkton, Md.
Muhlenberg, Frank, Reading, Pa.
Nancrede, C. B., Ann Arbor, Mich.
Osler, William, Johns Hopkins Hospital, Baltimore, Md.
Powell, W. M., Atlantic City, N. J.
Rahter, C. A., Harrisburg, Pa.
Slifer, Henry F., North Wales, Pa.
Smith, Allen J., Galveston, Texas.
Stiles, G. A., Conshohocken, Pa.
Taylor, L. H., Wilkes-Barre, Pa.
Wells, G. M., Wayne, Delaware County, Pa.
Wetherill, R. B., Lafayette, Ind.

## CORRESPONDING MEMBERS.

ELECTED

1866 Bumstead, Freeman J. Died 1879.

1859 Clark, Alonzo, Professor of Theory and Practice of Medicine in the College of Physicians and Surgeons, New York. Dead.

1859 Dalton, J. C., Professor of Physiology in the College of Physicians and Surgeons, New York. Dead.

1885 Dent, Clinton T., Assistant Surgeon and Lecturer on Practical Surgery at St. George's Hospital, Surgeon to Belgrave Hospital for Children, London, England.

1860 Ellis, Calvin. Died 1883.

1888 Fedeli, Gregorio, Rome, Italy.

1858 Flint, Austin, Sr. Died 1886.

1890 Gibbes, Heneage, Professor of Pathology in the University of Michigan, Ann Arbor, Michigan.

1858 Hammond, William A., Member of the National Academy of Sciences, New York.

1860 Isaacs, Charles E., Brooklyn. Died June 16, 1860.

1878 Jackson, J. B. S., Boston. Died 1879.

1886 Pye-Smith, P. H., Physician and Lecturer on Medicine at Guy's Hospital, London, England.

1860 Reeves, James E., Wheeling, West Virginia. Dead.

1861 Rokitansky, Carl. Died 1878.

1860 Watson, John, New York. Died June 3, 1869.

1859 Worthington, Wilmer, West Chester, Pennsylvania. Died 1873.

# REPORT.

## 1. ADDRESSES OF PRESIDENTS.

### 1. *Annual Address of the President to the Philadelphia Pathological Society.*

Read by Dr. A. V. Meigs.

During the past year there have been no great changes in the condition of our Society. Our work, however, has been continued in a manner creditable to the industry of our members. Nineteen meetings have been held, two of them being the conversational meetings as prescribed by the By-laws. Upon the first of these occasions it was our privilege to listen to an address by Dr. J. M. Da Costa upon "The Albuminuria and the Bright's Disease of Uric Acid and of Oxaluria." The meeting was largely attended, and the subject, which was admirably treated, elicited great interest among those who heard it At the spring conversational meeting, which was held upon the evening of April 27th, we were addressed by Dr. Frederick C. Shattuck, of Boston, upon the subject of "Arsenical Poisoning, with Special Reference to its Domestic Sources." It is, perhaps, hardly necessary to remind you that this source of poisoning has not attracted as much attention in our city as it has in some other localities, and therefore the address —which was both scholarly and temperate—was timely and most profitable to those who were so fortunate as to hear it. On December 22d the evening was devoted to a discussion of "The Pathology of the Blood," the subject having been opened by Dr. F. P. Henry and Dr. Alfred Stengel. Besides these, all of our regular stated meetings have been duly held, the total number, as already stated, being nineteen. About ninety-four pathological specimens have been exhibited during the year. After sketching thus briefly in outline the work accomplished by our Society during the past year, it may perhaps not be

unfitting that I should express to you my views of the value of the pursuit of pathological research to the practitioner of medicine, even if I accomplish this at the risk of seeming egotistical. My own career in medicine has so deeply impressed me with the inestimable value of pathological knowledge as an aid to diagnosis, prognosis, and the treatment of my patients that I cannot let slip the opportunity to express to a body of men, most of whom are a good deal my juniors, how important I consider our special branch of medicine. It is too much the custom to say that pathology is not practical, and that to the practitioner of medicine an understanding of it is not necessary or even that it has little value. Some comprehension of the principles of pathology is as necessary to the physician as is anatomy to the surgeon. No man can be as good a physician or can practise medicine as wisely and successfully when ignorant of pathology as he could after having acquired an understanding of the changes which are undergone by the tissues and organs as the result of the processes of disease. For my own part, I received my primary training in medicine at a time when little or no attention was bestowed upon instruction in pathology in the regular courses at our medical schools. Later, when I became a hospital physician, my own shortcomings in the direction of pathology were forced upon my attention so frequently that I felt myself constrained at last to try to learn something, at least, which would enable me to have some greater degree of understanding of the things that were placed under my eyes at the post-mortem examinations made of my own patients. Since, as a result of much labor and after having overcome many difficulties, I have acquired some comprehension of pathological processes, there is never a day that goes by without my perceiving that my diagnosis has been more comprehensive and my treatment of my patients better, owing to my knowledge of pathology. No one should ever cast at a pathological society or at the study of pathology the expression that it is not practical. In retiring from the office of President, as I shall do this evening, it is with mixed feelings of regret and pleasure—pleasure that I shall be relieved of a responsibility which I have often felt to be heavy, because I know that much more might have been accomplished to forward the interests of the Society than I have been able to do; and regret at yielding up an office that I have always felt it a great compliment to have been chosen to fill. In conclusion, permit me to return to you my thanks for the universal kindness and courtesy with which I have been treated while I have had the honor to be your presiding officer. *October* 12, 1893.

## 2. *Annual Address of the President to the Philadelphia Pathological Society.*

Read by Dr. J. H. Musser.

The By-laws of the Pathological Society seem to ordain that the President shall not be permitted to speak to the Society except once a year. They expressly state that at the annual meeting he shall sum up the work of the Society for the past year and make suggestions regarding its labors and the work of conducting them. In short, once a year the presiding officer is ordered to soothe or to scold, to drive or cajole, or in any way he sees fit to "dress up" the members of the Society. Now, the meetings of the Society during the past year have been so well attended, so full of scientific interest, so very enjoyable socially, that it would ill become the presiding officer to in any way make mention of the labors of the year save in terms of laudation. The pleasure of presiding over the meetings, upon one of which only was your officer unable to attend; the generous support, amounting on the part of the members to a strained leniency in overlooking the shortcomings of the chair; the sustained interest and enthusiasm exhibited by them, have inspired greater affection than ever before held by your chairman for the good old Society, the ardor of which affection will never cool. Any suggestions or scoldings, therefore, are inspired by the same spirit which prompts the chiding of a wayward child by a fond parent.

It is with much pleasure that your President offers his congratulations to you upon the unprecedented work of the past year. The membership has increased, the volume of *Transactions* has appeared without delay, the attendance upon the meetings of the Society has increased during the past year; while the number and character of the specimens and of the remarks thereon more than place the Society upon a level with any kindred organization in this or any country. The attendance upon the meetings is worthy of note. Not only was the presence of so many active laborers inspiring, but, in addition, the sustained interest in each meeting until an hour unusually late for medical societies.

*The Membership of the Society.* One year ago the membership was made up of 194 active and twenty-five non-resident members. During the year there were seven resignations; one was dropped for non-payment of dues and two died. During this time forty-one new members were elected. There are, therefore, 217 active members in the Society. Thirty-three of the new members have qualified; eight have thus far

not qualified, a duty they should perform at once, as they might be dropped from the roll of membership. Of the active members, twenty-five are life-members, a distinction which belongs to active members of twenty-five years' standing. Such members are exempt from the payment of dues. Our list of active members should increase. We should not rest until five hundred members are added to the rolls. The pathologist of each hospital in the city, the resident physicians of the hospitals, and all members of the profession whose labors are sweetened by close touch with medical science should be members of the Society. The young men of the profession should labor with us, for here facts can be given, the gaining of which does not imply a large clinical experience. Moreover, at this period of their career they have the time to engage in scientific work and thereby lay the foundation for future preferment in pathological and clinical fields. It should become an unwritten law in our hospitals that no applicant should be added to the pathological or clinical staff who has not performed a full complement of work in the Pathological Society, thereby earning its endorsement. The chairman personally knows that the commendations of officers and prominent members of this Society were of great service in securing appointments in days gone by. Finally, the Society forms a training-ground for young men who are hoping to indulge in forensic efforts, as time and opportunity permit, in the later years of their professional life. This is all the more truly the case when we remember that theories are not exploited at our meetings. Facts alone are presented, thereby, by necessity, the member acquiring precision and brevity, such important requisites in scientific communications. Because we deal with and search for facts only, unconsciously we cultivate a medical conscience which rejects impressions that are not true. We thereby develop an attitude of mind which in diagnosis and in therapeutics accepts only that which can be seen—the truth—and rejects the unseen and theoretical—an attribute so essential when weighing therapeutic problems, which always abound in complexity.

*The Meetings.* Twenty meetings were held during the year—eighteen regular, one conversational, and one special. The attendance at the meetings is recorded from the slips on which the name of each attending member is subscribed before he enters the Society room. Members very often neglect to register. Notwithstanding this, the unusual average attendance of twenty-eight to each meeting can be reported. This does not include the guests, of whom five to fifteen were in attendance at each meeting. The special meeting at which the subject of the prevention of tuberculosis was held was crowded. Very interesting reports

at this meeting were made by Drs. Hughes, Packard, Ball, Allyn, Martin, Davis, and by Professors Guitéras and Coplin. The regulations adopted by the Board of Health were in the line of thought of the resolutions of this Society. Similar meetings should be held and pathological questions involved in preventive medicine discussed.

Dr. S. Flexner, associate in pathology in Johns Hopkins, delivered the annual address. You all recall how ably and clearly he portrayed to a large audience the dire effects of auto-intoxicants and infections on the organs and structure of the body and the wide range of view which he opened up for us in chronic visceral inflammations. It was most gratifying that our members could join in the discussion with intelligence and spirit to a degree equal to that of any society in the country, and that they could report observations confirmatory of the statements of Professor Flexner. To two of our members these labors in this field were rewarded by the honor of bestowal upon them of the Boylston prize. A most enjoyable reception followed the meeting. The By-laws provide for two conversational meetings. It seems to your chairman that a conversational meeting should be an event in our pathological work in this city. It should be looked forward to and worked up with vigor and exactness. Most of us are so busily engaged that it is difficult with so many duties to concentrate our energies as becomes the importance of a conversational meeting. The chairman should, therefore, advise that the By-laws be so changed that the conversational meeting becomes an annual gathering only, which might include guests from many centres of pathological study to listen to a formal address. Let us make the conversational meeting an epoch of our winter's medical life in this city by one sustained, vigorous effort.

*The Contributions.* They numbered 127, and were varied and valuable. Recall the wonderful specimens of mediastinal disease, the exhaustive series illustrating morbid changes in the œsophagus; the specimens of renal disease and of cerebral and spinal disease, as well as groups of specimens which illustrated common as well as rare forms of pathological changes. Not only were the specimens well worthy of study, but many of the papers accompanying the specimens were gems, and already have been, and as time goes by will be, referred to by writers and teachers. The chair will refrain from invidious distinction, but begs the members, and particularly the younger members, to study the exhaustive reports of many cases presented, which often included a concise statement of the observations of others. In passing it may be said that the scientific reputation of the prominent men of this city is largely based upon their reports of single cases or groups of cases to this

Society. Time forbids, although the subject would be of great interest, a culling of the *Transactions* for the cases or reports which have become in a sense classical in medical science. Latterly, the specimens have been accompanied by written reports, in accordance with a By-law of the Society, the wisdom of which any member can see upon reflection. The rule will be enforced. It is hoped specimens presented will also be attended by a microscopical report of the specimen as well as an exhaustive pathological history. The chair would like to see provision made for more rapid examinations of specimens and the opportunity given each member to make such examinations. Could not the seats and tables be arranged to further this?

*The Transactions.* The final volume was delivered this year and the material for the new volume is well in hand. The *Transactions* should be published in our medical press, and the Society should insist that a way be found for such publication, even if an additional expenditure of money is required. Whether we shall employ a stenographer or further aid the recorder, the Society or its business committee should determine at once. Let us not allow another meeting to pass without a definite policy. The weekly or monthly publications of the Proceedings would be a stimulus to each worker; it would keep before the medical world the labors of this city in medical science, and thereby enhance its value as a medical centre, and in this manner promote the interests of its celebrated schools. Again, the chair insists upon the publication of the *Transactions* in this manner, and will contribute to a fund to be raised for this object.

Finally, shall we enlarge the scope of membership of the Society? Your President would extend the hand of fellowship to all interested in pathology. With restrictions, he would invite members of the dental and veterinary professions to a seat in the body. No ill can come from generous and broad fields of action in science; much good may arise.

The President humbly apologizes for trespassing on your time and patience in this desultory manner. Love for the subject has made him bold, is his only excuse. Again, accept hearty congratulations upon your prosperity and sincere wishes for the continuance of the scientific and social happiness which this prosperity augurs.

*October* 11, 1894.

## II. OSSEOUS SYSTEM.

### 1. *Carious odontoid process of axis and ulcerative destruction of transverse ligament.*

Exhibited by Dr. J. Dutton Steele.

I exhibit this specimen through the courtesy of my chief, Dr. Laplace, and of Dr. Coplin, who conducted the autopsy.

J. W., was admitted to the surgical wards of the Philiadelphia Hospital in January, 1893.

He gave a history of six months' duration of an adenitis of the cervical glands on both sides, which had gone on to pus-formation and had opened spontaneously before admission.

His neck showed sinuses situated about the angles of the jaw. All these were very superficial except one, which opened in the region of the mastoid process on the right side and ran backward and inward for two and one-half inches. However, no diseased bone could be found. The patient carried his head very stiffly and complained of vague pains in the occipital and frontal regions and over his shoulders.

There was no deformity, however, and the diagnosis of cervical Pott's disease was never considered.

He suffered from an increasing orthopnœa, which seemed to be explained by the failing compensation of an incompetency of the mitral valves.

In the afternoon of April 20, 1894, the patient complained of pain upon swallowing and dryness of his throat. There also seemed to be some difficulty on speaking. At 9 P.M. he was found by the nurse, whom he had summoned by pounding upon the floor, sitting upon the side of his bed.

His speech was very indistinct, but he succeeded in saying that he had suddenly lost the power of motion in his right arm and leg about ten minutes before.

When I saw him he was in bed, supported in a sitting posture, his head drooped forward, his teeth were clinched, and his respiration was very shallow and feeble.

The right arm was limp, while the left was quite rigid.

His pupils were equal. He lived fifteen minutes after he was first seen. An autopsy was secured and performed thirty hours after death.

When the brain was removed, pus was seen to issue from the foramen magnum. The odontoid process of the axis was carious, denuded of its periosteum, and projected forward so as to press upon the medulla.

The transverse ligament of the atlas had given away, apparently eroded by an ulcerative process, about one-quarter inch from its attachment on the right side, thus allowing the odontoid process to become displaced in the manner above stated. The membranes of the base of the brain just above the foramen magnum showed a circumscribed area of purulent meningitis.

From the appearance of the medulla it seemed as if the pressure, while finally diffused enough to cause death, had been greatest and probably first exerted at a point just below the anterior pyramids on the right side.

It would seem as if this might explain the paralysis of the right arm and leg.

The brain was somewhat œdematous, but otherwise showed nothing abnormal. The two hemispheres were markedly asymmetrical, the left anterior lobe projecting at least one-half inch further forward than the right.

The right ventricle was relaxed and the right auricle was distended; valves of the right side were normal.

The left auricle was empty and the left ventricle contracted and empty. The mitral valve leaflets were thickened and rigid, but showed no signs of recent inflammation. There was some old pleurisy and hypostatic congestion of both lungs.

The other organs showed nothing of interest. *May* 25, 1894.

## III. DIGESTIVE SYSTEM.

### 1. *Primary cancer of the gall-bladder.*

Exhibited by Dr. W. E. Hughes.

The patient was a man of 55 years, who had led a sedentary life, had never used alcohol to excess, but was a high liver and rather obese. Three years ago he had a typical attack of biliary colic. This was followed by another, and within a year he had a third, which was never fully recovered from. He was subsequently continuously in poor health and weak, with disturbed congestion and sometimes slight pain centering in the region of the gall-bladder. Three weeks before death there was a new attack of jaundice with no fever.

The post-mortem examination showed parenchymatous nephritis, a growth in the region of the gall-bladder slightly involving the liver. There were no secondary growths anywhere. In the centre of the growth on the gall-bladder there were fifty stones. The common duct was patulous to within a short distance from the duodenum, where there was an impacted stone, which was the probable cause of the jaundice. When this was removed the duct was entirely patulous.

Dr. Deaver said the case recalled to him Richardson's paper, in which small stones are regarded as the exciting cause of malignant disease; and he held the view that an early operation is advisable. He would himself operate after one attack in appendicitis, after two in hepatic colic, though he considered this an advanced view.

The President could recall no report of a case so extraordinary as the one presented. The gall-bladder is frequently enlarged, but more often smaller. The cases usually occur in the female sex. Fever was usually present in his series of cases, but usually due to pus. Jaundice occurred in 68 per cent. or 69 per cent., but long before death, not, as here, but a few weeks before. *October* 12, 1893.

### 2. *Cancer of the cæcum.*

Exhibited by the President and Dr. Curry.

The man had marked symptoms of intestinal obstruction, which was first complete, but afterward somewhat relieved. There was pain in the cæcal region. Some distention and peristaltic waves in the lower part of the colon. In the right iliac region was a tumor, which was hard but tympantic, and simulated a phantom tumor. The peristaltic wave moved rapidly over a large area and simulated stomach peristalsis, but this could be excluded. The age, emaciation, and intestinal obstruction indicated cancer, and a week before death the tumor could be felt, and per rectum an induration felt at the brim of the pelvis on the right.

The condition of the patient had not admitted of operation.

Post-mortem there was found a cancer of the cæcum and an ulcer just above the ileo-cæcal valve, communicating with an abscess behind the cæcum, which latter is a rare condition except in appendicitis.

Dr. Deaver asked whether it was difficult to decide if the large or small intestine was involved. Intubation of the colon was possible in his experience if a flexible tube were used, and this would help to determine the point at which the obstruction exists. The quantity of water that the bowel will hold could also be tested—five or six quarts being the normal.

The president remarked that the diagnosis was made by the tumor and peristalsis, with pain in the region of the cæcum.

*October* 26, 1893.

---

### 3. *Impacted gall-stone—Dilatation of biliary ducts.*

Exhibited by Dr. M. H. Fussell.

I owe the opportunity of demonstrating this specimen to Dr. James Sibbald, of Wissahickon, whose patient the woman was until her death. The history of the case is brief: A sudden, severe attack of pain ten years ago, the pain being in the region of the gall-bladder and radiating to the right shoulder. This attack of pain was followed by deep jaundice. Since this first attack the patient had been continuously jaundiced. On several occasions Dr. Sibbald demonstrated gall-stones

in the feces. On my examination, three days before death, the patient was found to be deeply jaundiced, had constant vomiting, and much abdominal tenderness. There was a large, tender, resistant mass just in the region of the gall-bladder. On the third day she vomited large amounts of matter, which appeared to be changed blood. There was no bright red blood and no clots. She died suddenly. Section, twenty-four hours after death. The skin and all the tissues were deeply jaundiced. On pressing upon the abdomen a dark, granular substance flowed from the mouth and nostrils which appeared like changed blood. On opening the abdomen the left lobe of the liver was found to occupy the entire epigastric region. The great omentum was matted and thickened. There was a complete perihepatitis. The stomach and duodenum contained perhaps a quart of greenish-black matter, similar to that which was vomited before death. The gall-bladder could not be seen. On handling, an abscess was broken open which lay between the stomach and liver and which was evidently the position of the gall-bladder. This abscess was the size of an orange. Stomach: This organ was greatly dilated. The pylorus not thickened nor contracted. There was no sign of a growth. On the lesser curvature the stomach-wall was adherent to the under surface of the liver. The adhesion was the size of a pea and was situated one inch from the pylorus, and formed a complete funnel-like cavity in the stomach. There was no rupture through this funnel. In the duodenum the opening of the bile-ducts was seen to be as large as a pea, and led into the greatly distended, common, cystic, and hepatic ducts, the common duct being one and one-fourth inches broad. The dilated cystic duct was completely obstructed at a point corresponding to the neck of the gall-bladder. This point of obstruction was in immediate contact with the abscess cavity above described. One-half inch below the opening of the common duct there was a second opening which led into the greatly dilated pancreatic duct. No gall-stone was found. The hepatic ducts were greatly dilated, many of them being the size of a very large pencil. Evidently a stone had been lodged in the duodenal end of the common duct The vomiting preceding death had dislodged the stone, and the great quantity of changed bile had flowed into the bowel and stomach and was vomited. This so much resembled blood that it was thought to be such even at the post-mortem. An examination, however, revealed the above state of affairs instead of a perforation, as was expected.

The President remarked that he had seen the gall-ducts enormously swollen and visible under the surface of the liver.

*October* 26, 1893.

### 4. *Cancer of the pylorus.*

Exhibited by Dr. Vansant.

Irish domestic. Single; white.

*Family history:* Cause of grandparents' deaths not known. Father died of septicæmia following the bite of a cow; mother of old age. Had two sisters and one brother. One sister died of dropsy and the brother of heart-disease. One sister is living and well.

No history of phthisis nor malignant disease in the family.

*Previous history:* Has always been temperate in her habits and was always healthy when a child, the only disease she has had being measles. When 20 years of age she sustained a fracture of the femur, but recovered perfectly.

Was never sick in bed until the present time. Has always worked hard at manual labor. Denies any alcoholic or specific history.

*History of present disease:* The patient had been apparently well until three weeks before admission. At that time she was seized with vomiting, accompanied by severe pain in the right chest and right hypochondriac region.

The vomiting became persistent, and continued to occur two or three times daily until the date of her admission, the vomited matter being often dark green and very offensive.

Constipation, which had been habitual with the patient, increased steadily and was not relieved by the ordinary remedies, so that for seven days before admission there had not been a movement of the bowels.

The patient was brought to the hospital on September 9, 1893. Temperature 100°, pulse 90, respiration 26 on admission.

*Inspection:* Large, well-developed, but emaciated woman; weight about 140 pounds. The skin was of sallow complexion; cheek-bones prominent; eyes sunken; distresssd expression of countenance, the skin covering forehead and at angles of the mouth being drawn as if in pain. Dorsal decubitus, the thighs being flexed on abdomen. The inferior maxilla protruded somewhat, the teeth preventing union of upper and lower lips with mouth closed. The conjunctival and buccal mucous membranes were both markedly pale. Chest well developed, good expansion on both sides, apex-beat not visible. Abdomen slightly distended, painful on changing position.

On palpating the abdomen the patient evinced great tenderness and pain, the latter being most marked over the epigastrium and right iliac

fossa, but present also along the ascending, transverse, and descending colon. The pain was much increased by pressure.

On account of the exquisite tenderness present, deep palpation was impossible on admission.

Turpentine stupes were applied over the abdomen and a saline purge given, which resulted in four liquid movements. During the next twenty-four hours the patient vomited once, the contents measuring thirty ounces, being dark brown in color and containing clumps of semi-solid material, resembling altered blood. The diet on admission consisted of milk and beef-tea.

The pain over the abdomen was considerably relieved by counter-irritation, and physical examination more easily and less painfully performed.

Gastric tympany extended from epigastrium to sixth interspace, to axillary line, to margin of tenth rib. On deep palpation a hard mass about the size of a fist could be plainly felt in the epigastrium, being to the left of the median line, about two inches below the ensiform cartilage. The mass was movable to a certain extent, more to the right than to the left.

The tumor was hard, resisting, not expansile, moderately painful to the touch, and a pit, or depression, could be felt on its left anterior surface. The edge of the liver could be felt at the costal margin, but the organ was not enlarged. A nodular mass about the size of a walnut could be felt at its lower margin over the site of the gall-bladder. The abdominal walls were thin and lax, and the remaining viscera were apparently normal.

Physical examination of the heart and lungs revealed nothing abnormal. Examination of the urine on admission showed it to be of specific gravity 1018, slightly acid in reaction, pale straw-color, with a small amount of pinkish, curdy sediment. Chemical and microscopical analysis failed to detect anything abnormal, although repeatedly examined during the course of the disease.

She was put upon a supporting treatment and the bowels were kept freely opened, the stools being thin and dark brown in color.

The patient continued to vomit, usually twice in twenty-four hours, the vomited matter measuring thirty fluidounces or thereabouts, and much resembling beef-tea in color and consistency. Specimens of the vomit showed it to be neutral in reaction with absence of free HCl. Three weeks after admission the stomach became more irritable, and nutritive enemas were resorted to; cracked ice, sp. frumenti four fluid-drachms, soda-water four fluidounces, being given by mouth every three hours.

The patient became rapidly emaciated, but suffered little pain over the seat of the tumor, which at this time could be very plainly palpated and seemed to have increased somewhat in size. Ten minim doses of sp. chloroformi every three hours were tried in the hope of checking the emesis, but without success.

On October 19th, forty days after admission and nine weeks after the appearance of the first symptoms, the temperature dropped to subnormal, the pulse became rapid and fluttering, stupor and coma developed, and the patient died in extreme exhaustion. The autopsy revealed the following: Body of an emaciated female, post-mortem rigidity little marked. Right second toe twisted over the third, apparently old dislocation. Some post-mortem discoloration over the general posterior surface.

Abdominal cavity fairly moist. Omentum and abdominal walls contained considerable fat.

Amount of pleural fluid normal. Lungs free from adhesions.

Pericardium free and barely moist.

*Heart:* The right auricle and ventricle filled with fluid blood and contain a few chicken-fat clots. The aortic and pulmonary valves are sufficient. Left ventricle is firmly contracted, containing one small clot. Slight thickening of the valves throughout. Left ventricle wall 2.5 cm. thick; right ventricle wall 0.5 cm. thick; mitral valve 10 cm. in circumference; tricuspid valve 11 cm. in circumference; weight 10 ounces.

*Lungs:* Left crepitant throughout. Small amount of emphysema at outer edges. Right lung presents a similar condition. Weight of left, 7 ounces; right, 8½ ounces.

*Spleen:* Firm. Fibrous tissue well developed. Weight, 2.5 ounces.

*Supra-renal capsules* apparently normal.

*Kidneys:* Left, weight, 3½ ounces. Small cyst on convex surface. Cortex and pyramids in good proportion. Some fibrous tissue present. Right, weight, 5 ounces. Similar to left, but fibrous tissue more marked.

*Stomach:* Somewhat dilated and containing about twenty fluidounces of thin, curdy liquid. Walls not injected, gray in color, and rugæ not prominent.

Pyloric orifice constricted, barely admitting a grooved director. Surrounding the pylorus is a hard, cancerous mass, with marked ulceration around the edges, in contact with and encroaching upon the adjacent liver structure.

The carcinoma does not extend into the duodenum.

Retroperitoneal glands carcinomatous, principally behind the cardiac portion, which, however, is not involved nor constricted.

A large, carcinomatous gland joins the head of the pancreas to the duodenum, but the former is not involved.

*Liver:* Slightly cirrhotic and anæmic, otherwise normal. Bile-duct patulous.

*Vessels:* The descending aorta showed a number of marked calcareous plates. These were just behind the cancerous glands.

*Intestines:* In the lower part of the ileum the mucous membrane is intensely congested, otherwise normal.

*Uterus and internal genital organs* atrophied.

*Pathological diagnosis:* Scirrhus carcinoma of pylorus and retroperitoneal glands. Fibrous atrophy of abdominal organs.

Dr. McFarland recalled a case in which no cancerous tissue could be found, though there was a large fungus mass at the pylorus. It was composed entirely of fibrous tissue with fungus material externally.

*October* 26, 1893.

---

5. *Large abscess of the liver secondary to dysentery.*

Exhibited by Dr. H. W. Cattell.

A. J., male, aged 51, a German by birth, and a coppersmith by occupation, was admitted October 28, 1893, to the X Hospital. He served on the U. S. S. "Alert" on the Chinese station, and had also lived in the southern part of the United States.

At the time of his admission and afterward the following notes were taken by the resident: Temperature 100.6° F. Feels chilly; pain in side; a cough, but no expectoration; has had retention of urine.

*General appearance:* Weight, 190 pounds. Flush on cheeks. Pupils contracted. Mucous membranes good color. Tongue dry and fissured; breath foul. Pulse rapid, regular, good volume and strength; arteries highly atheromatous; finger-nails clubbed.

30*th.* Chest is well formed, antero-posteriorly enlarged. Costal angle good. Movements limited on right side. Percussion note over right apex and entire left lung is good. Over lower lobe of right lung there is increased tactile fremitus; dulness on percussion, blowing, and tubular breathing.

Heart-sounds clear at base and apex. Patient has been troubled with a serous diarrhœa, bowels moving from ten to thirteen times daily.

*November 2d.* Tongue thickly coated with a white fur; moist. Sordes on teeth and lips; pulse is rapid, regular, good volume; compressible. Over right lower lobe there is a flatness on percussion; bronchial breathing still marked. Bronchophony, crepitant and subcrepitant rales. Tactile fremitus much increased. Diarrhœa has not much improved.

*4th.* Tongue dry, fissured. Temperature, 101.3°. Respiration, 44. Pulse, 106. Pulse is rapid, regular, good volume and strength. Signs much the same over right lower lobe, but over right apex there is increased tactile fremitus. Bronchial breathing. Bronchophony.

*6th.* Temperature, 101°. Pulse, 120. Respiration, 40. Anteriorly, dulness begins at third rib; absolute flatness at fourth rib on right side. Midaxillary line, dulness begins at fifth rib. Posteriorly, dulness at about 8 cm. below spine of scapula. Over this region breathing distinctly tubular with occasional crackling râles.

Bronchophony. Examination for tactile fremitus unsatisfactory. At right apex breathing is broncho-vesicular, but percussion note is of good resonance. Left lung negative. Heart sounds clear at base and apex. Pulmonary diastole accentuated. Abdomen distended and tympanitic. Tenderness, but no gurgling, in right iliac fossa.

Liver-dulness from fourth interspace to 2½ inches below costal margin. Splenic dulness not obtainable and edge not felt. Abdomen symmetrically enlarged; marked tympany. No tenderness noted. Face dusky; head bathed in perspiration; tongue thickly coated by moist, brown fur. Pulse regular, much stronger and better volume. Whole middle and lower lobe of lung on right side involved. Much less movement on right side posteriorly. Percussion note almost flat in the lower half of axilla and from middle of scapula down. Most intense tubular breathing in posterior axilla with bronchophony. General condition improved.

*7th.* About 6.10 patient, who had been covered by profuse sweat all day, grew suddenly cyanosed. Dyspnœa was quite marked. Pulse rapid and feeble. The temperature-chart shows a hectic type, running down to normal and then up to 102° or less. The examination of the urine was negative. Death soon followed. The condition of abscess was, therefore, not suspected during life, and the diagnosis of pneumonia was made.

The autopsy (Cattell, No. 602) was made twenty-two hours after

death, on November 8, 1893. Only the notes bearing upon the abscess are given.

Body of a fairly well-nourished male; large amount of fat over the abdomen; muscles atrophied. Slight rigidity and post-mortem lividity.

No injection of conjunctiva with bile. Neck short and thick; head square.

*Abdomen:* On opening abdomen a large amount of fat noticed. Stomach is dilated to twice its normal size or even more. Intestines filled with gas; fecal matter in the large intestines. No peritonitis.

The striking feature of the organs of the abdominal cavity was the extension of right lobe of the liver upward and toward the median line, the diaphragm extending to the centre of the third rib. Anteriorly nothing abnormal is noted. The liver substance shows some slight increase of connective tissue near the falciform ligament. On introducing the hand posteriorly to the right lobe of the liver, a few recent adhesions were readily broken up, and over 500 c.c. (by measure) of a thick, sanious pus with numerous flakes of whitish material were removed, and the hand slipped readily into a large abscess the size of a child's head. Under the microscope the fluid showed fatty detritus, leucocytes, some large cells, possibly amœbæ, fatty crystals, etc.

The liver weighed 3420 grammes. Abscess occupies almost the entire upper, right, and posterior surface of the right half of the right lobe, the wall being thicker in front than behind. Edges could be felt plainly fluctuating. Fluid in cavity was of anchovy sauce or tomato-soup color and a higher specific gravity than that first removed. Some marble-sized metastatic abscesses in left lobe in centre, but none on the surface of this lobe. At the lower border of the liver there is a small, circular area of softening, which is slightly umbilicated, also several other portions of this lobe are undergoing degeneration.

The inside wall of the abscess was roughened, the vessels toward the centre of the liver standing out prominently, as is sometimes seen in large, tubercular cavities. The walls looked as if a reddish-brown, thin plaster had been thrown upon the surface and the whole had been painted with anchovy sauce.

Entire large intestines occupied by numerous healing ulcers; none in small intestines, the gastro-intestinal mucous membrane being smooth. The ulcers are irregular, the bottom being occupied by a pseudo-membrane. The edges are in spots undermined. No tubercles on peritoneal surface.

The right thoracic cavity contains about 400 c.c. (by measure) of

fluid. Lung is firmly adherent to right chest and pressed upward, the thoracic cavity being (as will be remembered) diminished by the abnormal position of the right lobe of liver. Right lung is in a condition of atelectasis. An encysted pleurisy at apex, containing fluid. Weight of right lung 600 grammes; no points of crepitation discovered. Amount of connective tissue slightly increased. The lung, entire, floats, but lower lobe sinks readily in water. No signs of pneumonia.

Left lung œdematous; congested; no signs of pneumonia. Weight of left lung 600 grammes; slightly crepitant.

Dr. Scott recalled two cases of abscess of the liver with rupture into the lung, in both of which there was anchovy sauce expectoration, in which amœba were found. Both cases were recognized and laparotomy done with recovery.

Dr. Westcott said he saw, two years ago, a case of great enlargement of the liver with a secondary catarrhal pneumonia, in which there was doubt as to diagnosis. Liver-cells were seen in the pus of the intestinal discharges.

Dr. Meigs remarked upon a case he had a year ago which was operated upon and in which no amœbæ were found. In that case sections showed on the inner wall of the abscess cavity cells which could not be regarded as liver-cells. Further, the man had had constipation, yet ulcers were present in his large intestine. *November* 9, 1893.

---

6. *Cancer of the œsophagus following a stricture, due to the taking of lye, with recent metastasis to the liver.*

Exhibited by Dr. Henry W. Cattell.

C. W., æt. 66 years, born in Germany, gave a negative family history. He says that he has always had good health except that he has been treated on several occasions for gastritis.

Was accustomed to free use of stimulants.

About eighteen months ago he drank, by mistake, some concentrated lye, taking, however, only one swallow. He was sent at once to the Pennsylvania Hospital, where he remained four months. Since that time he has not been able to swallow solid food, and frequently vomited liquid food. He swallows at present with difficulty. His voice is not affected. He has lost considerable in weight and strength.

Externally on the right side of the larynx and a little posteriorly to it there is an apparent induration. It moves upon swallowing and seems to be attached to the larynx. Heart and vessels, lungs, kidneys, urine, digestive system, and nervous system are negative.

I am indebted to Drs. Lichty and Carpenter for the above notes.

At the post-mortem the stricture was discovered 2 to $2\frac{1}{2}$ inches from the entrance of the œsophagus into the stomach. It was at once noted that there was a new growth, represented by a fringed edge, which was especially prominent on the lower border. The entire stricture and new growth is represented by a flat, tubular swelling, $2\frac{1}{4}$ inches across after the œsophagus had been opened by $1\frac{1}{4}$ to $1\frac{5}{8}$ inches in the longitudinal direction.

The remaining portion of the œsophagus presented nothing abnormal. Larynx and trachea normal.

Scattered throughout the liver on the surface were discovered eight or nine small, umbilicated, nodular, grayish-yellow spots of a new growth, somewhat broken down in the centre, but of small size, the largest one not being over a hazel-nut in size. Still fewer are the nodules in the mass of the liver-substance itself.

The surrounding tissue is not infiltrated, and judging from their widely scattered positions and their small size it would seem that they are of very recent origin.

Dr. Carter has kindly prepared a slide of one of the nodules from the liver, which confirms the macroscopic diagnosis of cancer.

*November* 9, 1893.

---

### 7. *Cirrhosis of the liver in a boy; malarial origin(?).*

Exhibited by Dr. Alfred Stengel.

A. B., a boy of 17, was admitted to the University Hospital with the following history: He had been a healthy lad until some six months or a year before. His family history was negative, no evidence of hereditary disease being obtainable. He himself had worked in a swampy region in Delaware for several summers, and had had an attack of malarial fever which he described as being unusually severe. There was an indistinct history also of an attack or attacks of protracted diarrhœa.

When the boy came under observation his abdomen was found to be

greatly swollen, and this was determined to be due to the presence of liquid. The spleen could be felt projecting below the ribs, and was found to be hard and indurated. The patient's skin was of a sallow, almost ashen color, and the limbs were decidedly emaciated. The heart was displaced upward to the third interspace, and there were anæmic murmurs. Examinations of the blood were repeatedly made, and showed a moderate reduction of corpuscles and 75 per cent. of hæmoglobin. There were no malarial organisms.

The patient was placed upon medical treatment, including arsenic and remedies directed to the removal of the liquid, but only temporary and slight improvement occurred. Finally tapping was resorted to, and a large quantity of clear, serous liquid was removed from the abdomen. Palpation, after the removal of the liquid, revealed no additional conditions; the edge of the liver could not be felt, though the organ appeared to be about normal in size; the spleen was more palpable than before, extending to the level of the umbilicus. Subsequently, under arsenical treatment, the boy's general condition improved greatly, and it was thought for awhile that the remaining dropsy would subside, but reaccumulation occurred and repeated tappings became necessary. Finally he left the hospital, and shortly afterward died.

I was fortunate enough to obtain a post-mortem examination. The structures of interest were the peritoneum, the liver, and spleen. The peritoneal membrane was everywhere thickened, and the parietal layer presented a dense, white sclerotic appearance. The intestinal reflections were little involved, and the condition was apparently such as would result from long-standing overdistention. The bloodvessels of the mesentery and the venous radicals of the portal system generally were greatly distended. The liver was small and its capsule thickened. The ligaments of attachment were unusually strong and contracted; the surface of the organ was highly irregular and typically hobnailed. On section the appearance was that of atrophic cirrhosis, the parenchyma being of a light yellow color and thrown into prominence by the contraction of interstitial bands of connective tissue. The spleen was enormously enlarged, being about 22 cm. in length, 15 cm. in width, and 12 cm. in thickness. The capsule was tensely distended, and the external surface therefore quite smooth. On section the splenic pulp was found to be dark colored. The substance was unusually firm and the trabecular connective tissue was prominent.

Microscopic examinations were made of the liver and spleen, with the discovery in the former of the ordinary appearances of atrophic cirrhosis, in the latter great hyperplasia of the trabecular and fixed

connective tissue generally, and numerous deposits of hæmatogenous pigment.

The nature of this case was one that excited great interest from first to last. When the boy was admitted to the hospital it was at once recognized that he was suffering with extreme ascites and splenic enlargement. The history at this time gave us no clue to antecedent causes with the exception of malaria. The occurrence of infantile cirrhosis of the liver, to which Palmer and others have called attention, led to the suspicion that the patient had this condition; but there was no evidences of a positive character with the exception of the ascites and splenic enlargement. The most searching investigation revealed no evidences of inherited syphilis, and there was no evidence of alcoholism. The earlier history of the case was moreover of indefinite character, and beyond ascites there was but little indication of circulatory obstruction. Our attention therefore was fixed upon the history of malaria, and the experience of tropical writers who have described forms of malarial hypertrophy of the spleen with prominent ascites was recalled. The appearance of the boy was not unlike that seen in chronic malaria; the enlargement of the spleen was in conformity with the suspicion entertained. The absence of malarial organisms in the blood and the discovery that the condition of the blood was not greatly deteriorated rendered the diagnosis extremely doubtful.

After the abdomen had been several times emptied of its liquid, the condition of the liver became apparent, though the size was seemingly but little altered and the edge could not at any time be well determined; undoubtedly, however, there was induration, and the granular condition of the anterior surface was sometimes palpable.

In view of the lesions discovered post-mortem, there was still much doubt regarding the etiology of the case. It is unquestionably true that infectious conditions may play a prominent part in the production of interstitial changes in various organs, as the kidney, the heart, and the spleen. Changes in the liver are doubtless also frequently due to infections, since, in instances of death from acute infectious fevers, some hyperplasia of the interstitial tissues is not uncommonly seen. The frequency of these diseases, however, makes it difficult to determine their exact relation to cirrhosis. It would seem that marked cirrhosis is rarely caused by hæmatogenous infection, though exception to this must be made in favor of tuberculosis and syphilis, which do occasion considerable interstitial hepatitis. The relation of malaria to cirrhosis is of particular interest in this case. The forms of enlargement of the liver of the tropics have not as yet been accurately classified, but certain of

them are undoubtedly instances of connective-tissue hyperplasia due to malarial infection. I have had an opportunity to examine but one case of this character, an instance of Chagres fever of malignant type in a person who had lived for many years in Central America and who arrived in Philadelphia only a few days before his death. In this instance the liver was greatly enlarged and the surface was smooth. Microscopically, however, there was extreme interstitial hepatitis, though it was uniform in distribution and did not exhibit the tendency to contraction observable in ordinary cirrhosis. Cases of typical atrophic cirrhosis supposed to be due to malarial infection have been recorded, and it is possible that in the present instance such may have been the case. It is certain that the boy suffered with malarial fever for several years in succession, and it is not unlikely that the malarial infection had persisted continuously for several years. All other conditions which might have occasioned the cirrhosis could be excluded, and even the infectious fevers (typhoid and scarlet fever, etc.), which might conceivably have occasioned the disease, had not existed. Careful microscopic examinations of the liver and spleen showed no malarial organisms in the blood-corpuscles within the capillaries.

*November* 23, 1893.

---

8. *Gall-stones.*

Exhibited by Dr. Carter.

The patient was a man, 89 years of age, who had always had good health until he was 85, when he had a fall. Since then he has had several attacks of jaundice, which appeared only at rare intervals at first, but latterly were frequent, and for some time before his death he was deeply jaundiced.

On post-mortem examination the gall-bladder was found dilated and filled with stones. There were two stones impacted in the common duct, which was greatly dilated. *November* 23, 1893.

9. *Stomach from a case of creosote-poisoning.*

Exhibited by Dr. Coplin.

The case was a hysterical young woman of 21 years, who drank two ounces of creosote. The stomach exhibited superficial necrosis of the epithelium. Dr. Coplin thought the creosote was carbolized.

Dr. Wolff thought the stomach presented the appearance of carbolic-acid-poisoning, and the odor present was that of carbolic acid.

*December* 14, 1893.

---

10. *Typhoid fever with acute parenchymatous nephritis*

Exhibited by Dr. J. M. Swan.

The patient from whom these specimens were taken was admitted to the wards of the Presbyterian Hospital after having been sick four weeks. The character of the illness was not determined from any questioning of the family, and the patient was too ill to be questioned herself. She was a female mulatto, æt. 20 years, semi-conscious, and suffered from dyspnœa, pain in left side, short cough, fever, sweats, and some diarrhœa. The temperature was 104°. A number of pleural friction-sounds were heard over each base. The abdomen was greatly distended and tympanitic, and measured 36 inches in circumference. After being in the hospital five days the patient died, and on autopsy the heart was found arrested in diastole, the muscles pale and flabby, showing evidences of cloudy swelling. The intestines showed a large number of healed and healing ulcers, transverse to the lumen of the tube, and in one place in the ileum there was very nearly a perforation, only the peritoneal covering of the bowel being left, as you can readily see. The kidneys were large, congested, dripped blood on section, and, as is noticeable in this specimen, showed the changes of acute parenchymatous nephritis. The urine, examined two days before death, showed neither albumin nor tube-casts, and, as it was not subsequently examined, no knowledge of the kidney condition was had until the autopsy. Death was caused by heart-failure from the distended, transverse colon pressing on the diaphragm, thus impeding the action of that organ.

Dr. Meigs spoke of the importance, in typhoid fever, of ascertaining if

other lesions are present. One of his cases, a woman who had been sick two or three weeks, died at the end of a week's treatment. The autopsy showed the sigmoid dragged across the abdominal cavity and glued to the colon by fibriod adhesions. The kidneys, at the summits of the cones, were white and were harder than normal, and the cortex red. Previously he had noted that contraction or fibrosis begins in the medullary portion, and the microscopic examination in this case showed fibroid change in the medullary portion and especially at the tips of the cones. This seems to show that the fibroid disease does begin in the medullary portion.

The President agreed with Dr. Meigs as to the importance of investigation as to other lesions in typhoid, particularly in its bearing upon prognosis. He also referred to renal typhoid, in which there are commonly irregular fever and chil s, usually during the last week.

*December* 14, 1893.

---

11. *Meckel's diverticulum.*

Exhibited by Dr. Carter.

The specimen was taken from the body of a child of 4 years, and showed a Meckel's diverticulum, situated 25 inches above the ileo-cæcal valve. *December* 28, 1893.

---

12. *Ileum and colon from a case of acute infectious colitis.*

Exhibited by Dr. Lainé.

This specimen was obtained from a child, æt. 2 years, who died on the tenth day of the disease. The symptoms from the beginning were absolute disgust for all food, constant nausea, diarrhœa, fifteen to twenty passages a day (blood present in most of them and mixed with large quantities of mucus), the temperature ranging from 101° to 105°.

This same trouble was observed among five children belonging to different families in the neighborhood, none of whom had had any communication with each other. They were all taken down at the same time and with about the same symptoms Four of the children had a cough and evidences of a mild bronchitis, and two of the older members of the families were suffering from la grippe at the time.

The parents were in comfortable circumstances. The hygienic surroundings were perfect. The child had never been ill before, and had always enjoyed good health. The case was seen in consultation by Professor Wilson, who agreed on the diagnosis of an acute infectious colitis. The medication consisted in the administration of stimulants and food, such as cream in water, egg-water, and gum-arabic water, which were taken in very minute quantities. Washing out the colon had a decided effect in checking the number of movements for several hours, but beyond this all the usual remedies tried were absolutely fruitless in their results. On post-mortem examination the only changes found in the intestinal canal were patches of hyperæmia on the mucous membrane of the colon—no unusual condition in children who die from diarrhœal troubles; and the most noticeable pathological change found was an intense congestion of the ileum, extending about twelve inches from the ileo-cæcal valve. No ulcerations were present, either superficial or deep. The solitary glands and Peyer's patches were intensely congested and infiltrated. The enlargement of the mesenteric glands was general. The stomach and small intestines were empty and the mucous membrane very pale. The important point in the case is the fatal termination of an apparently simple colitis occurring in the middle of winter, out in the country and among people whose hygienic surroundings were perfect.

The existence of an epidemic of the same character in the neighborhood points conclusively to the infectious origin of the trouble, and apparently in some way connected with our recent epidemic of influenza.

Dr. Hughes considered diarrhœa in children as due to a specific cause. True dysentery is rare in children, while the pseudo-variety is often met with. In adults he had always found the amœba coli in dysenteries. The enlargement of the glands in this case he considered of no importance.

Dr. Detweiler said that in cases of intestinal disease observed by him in young children the glands were always enlarged and Peyer's patches often resembled the appearance in the first stage of typhoid fever.

Dr. Lainé said he laid no stress upon the enlargement of the glands.

*January* 11, 1894.

### 13. *Carcinoma of stomach and liver.*

Exhibited by Dr. M. V. Ball.

M. K., æt. 53 years, coal miner by occupation, Welshman by birth. Family history negative; always enjoyed good health up to two years ago, since which time distressing eructations of gas, occurring at different times in the day and varying with the kind of food. Vomiting of gastric contents only two or three times, and never accompanied with blood.

Pain was only noticed when eructations occurred. Emaciation and discoloration of skin commenced about nine months ago. No fever. Urine contained no albumin. Gastric contents examined microscopically showed carcinoma cells. Diagnosis of carcinoma of stomach.

Death occurred after extreme emaciation with coma for several days, œdema of legs, and retention of urine and jaundice. Autopsy showed lungs filled with coal-dust; heart normal. Liver greatly enlarged, extending over middle line and covering stomach and downward below the ribs. It was infiltrated with a cancerous growth affecting nearly every portion of the organ.

The stomach showed on posterior wall an epithelial growth, circumscribed and situated about half-way between pyloric and œsophageal ends, not occluding the pylorus or causing stricture of the same.

A few mesenteric glands were involved. *February* 8, 1894.

---

### 14. *Cancer of the stomach and pulmonary tuberculosis.*

Exhibited by Dr. Judson Daland.

G. S., æt. 65 years, English laborer, admitted October 23, 1893. Family and previous history entirely unimportant; no hereditary disease in family; no alcoholism; no syphilis.

On admission it is noted that the patient is a man of small stature, emaciated, complexion sallow. Symptoms consist of cough and gradual loss of strength. Physical signs show markedly emphysematous lung, with some bronchitic râles over both lungs. No other signs.

*December* 16*th*. Patient complains of weaknesss, of anorexia, and of

increasing loss of weight. Examination shows only emphysema and bronchitis, with large right heart. Abdominal palpation, done on account of suspicion of abdominal disease from emaciation and sallowness present, revealed nothing. Urine negative.

*29th.* Examination shows area of dulness, with increased resonance and fremitus, but with decreased breath-sounds from second right rib to eighth rib, and from sternum to anterior axillary line; probable collapse; emphysema of high grade over all the rest of both lungs, with universal bronchitic râles.

Dilatation of right heart, with probable tricuspid systolic murmur.

No abdominal condition noted.

*January 2d.* Patient growing steadily weaker; temperature about normal, at times going to 100°, and at intervals of six to eight days going to 96°.

No expectoration; moderate cough; appetite poor; bowels constipated, except diarrhœa for two days about January 3d. Urine negative.

No vomiting at any time. No pain, except for ten days before death, when the patient occasionally complained of pain in the lumbar region, but this was not severe. Death apparently from exhaustion, with subnormal temperature, at 10 P.M., January 11, 1894.

*Autopsy* showed carcinoma of the cardiac end of the stomach and tuberculosis of the right lung. The tuberculous process in the lung was evidently secondary to the cancer, and may have been acquired in the hospital. *February* 8, 1894.

---

## 15. *Cirrhosis of liver.*

Exhibited by Dr. D. J. Milton Miller.

T. R., æt. 36 years, weaver, very hard drinker, admitted to the Episcopal Hospital December 13, 1893. Had been feeling unweil for the past two months, with symptoms of indigestion. One week ago the abdomen began to swell, and his nose bled twice. On admission there was a small degree of ascites, but his principal complaint was of a flatulent dyspepsia. The urine contained a small amount of albumin; specific gravity 1020. There was no jaundice. Epigastric and mammary veins enlarged. Liver area reduced in size; dulness ceased one inch above costal margin in right mammary line. Under treatment, ascites

rapidly disappeared and the general condition improved. On January 10, 1894, β-naphthol, ten grains t. d., was ordered with the hope of relieving the marked flatulence from which he suffered. Ten days later he became delirious and passed large quantities of black urine—black, almost, as ink. This, on standing, deposited a heavy sediment, filling one-quarter of the glass. The microscope showed this deposit to be composed of blood-corpuscles, some entire, some more or less disintegrated. β-naphthol was withdrawn, diluents administered, and at the end of the week the urine was free from blood. During this attack of hæmaturia there were several severe nose-bleeds. After this fluid again accumulated in the abdominal cavity, necessitating tapping on the 8th of February, when 118 ounces of yellowish, clear fluid were removed.

On February 9th delirium appeared again. On the 15th the patient was attacked with facial erysipelas, to which he succumbed on February 17th.

Autopsy by Dr. McFarland.

Sanguineous fluid in abdomen. Where the trocar and canula had been inserted the muscle was infiltrated just beneath the parietal layer of the peritoneum.

Stomach dilated. Spleen enlarged, 8 x 14 x 2½ inches. Liver weighed 1 pound and 14 ounces. It presented the appearance of a typical hob-nailed liver. Its surface is studded with yellow granulations from a pin-head to a pea in size. Capsule adherent. Left kidney weighed 8 ounces. Somewhat pig-backed in appearance. Presents the appearance of cloudy swelling. Right kidney weighed 7 ounces. Identical in appearance with the left. Other organs normal. What was the cause of the hæmaturia on January 20th? As hemorrhage from the kidney is not a symptom of hepatic cirrhosis, at least as a result of portal obstruction, and as in this patient there did not seem evidences of a toxæmia profound enough to have produced changes in the blood, it is reasonable to attribute this symptom to the toxic effect of β-naphthol—a drug which sometimes produces hæmaturia.

Dr. McFarland called attention to the wound made by the trocar. In this case the trocar passed through the rectus muscle and caused a hemorrhagic condition of the muscle and an ulcer on the inner side. The man contracted erysipelas on the same day, but the connection of the two is uncertain.

Dr. Wolff said, in regard to the hæmaturia, that he had used beta-naphthol in large doses without producing hæmaturia. Neisser and Levine, however, spoke of this condition. The reason for its causing it here probably was the disease of the liver. The hydrocarbons are

sulphonated by the liver, and hence the beta-naphthol probably acted thus because of the disease of the liver. This is a fact of much practical importance. *March* 8, 1894.

---

16. *Carcinoma of œsophagus; abscess of lung; pyopneumothorax.*

Exhibited by Dr. D. J. Milton Miller.

B. F., laborer, æt. 53 years, admitted to the Episcopal Hospital December 29, 1893. Family history negative. Patient has been a hard drinker. For a long time before admission had suffered from pain about the lower part of the chest anteriorly. About six weeks before he came into the hospital he began to have difficulty in swallowing solid food. Such food would "stop half-way" and would be regurgitated in a few minutes. Liquids could only be made to reach the stomach by swallowing with great slowness, otherwise they would be rejected in from three to five minutes. The sensation of pain, as described by the patient, was always in the lower part of the thorax, just above a line drawn through the base of the ensiform cartilage. Cough and shortness of breath had been present for two months. Examination of the lungs revealed signs of a general bronchitis and emphysema, prolonged expiration, and moist and dry râles. There was distressing cough, particularly at night, with thin, muco-purulent sputum. At no time was the expectoration purulent, nor did he ever bring up large quantities after periods of freedom from expectoration. There was no cachexia, although the cutaneous and mucous surfaces were pale. The cervical glands were not enlarged. Fever was not present during his stay in the hospital, except just before the fatal termination. The patient was fairly well nourished, and his condition quite good, beyond some weakness and the constant pain and cough, which prevented sleep. The simplest œsophageal bougie failed to pass the stricture, but was always arrested at a distance of from 14 to 16 inches from the lips. His condition did not improve, though he did not complain much. He took considerable nourishment—three to four pints of milk daily and the whites of two or three eggs.

Four weeks after admission he was suddenly seized with a chill, great dyspnœa, and had abundant fatty, blood-tinged sputum. On the following day, when I saw him, the difficulty in breathing was intense. The right chest was tympanitic to the sixth rib laterally; below this point

absolutely flat. Over the latter area, absent breath-sounds; above it they were greatly diminished, with numerous fine, moist râles. Heart is placed slightly to the left. The aspirating needle was at once introduced and fifty ounces of semi-purulent fluid withdrawn, to the patient's great relief. He rallied for a short time, but again began to sink, and died the next morning, February 7, 1894.

At the autopsy, complete collapse of the right lung was found. The right pleural cavity contained about fifty ounces of semi-purulent fluid. At the base, close to the mediastinum, there was a pleural fistula communicating with an abscess of the right lung. This abscess was the size of a small orange, and rested upon the diaphragm. It was bounded posteriorly by considerable lung-substance, but anteriorly, on its left side, and when it rested upon the diaphragm its walls were thin and membranous.

At the lower end of the œsophagus, just before its entrance into the stomach, was a cancerous growth involving the entire circumference of the gullet and occupying about 2½ inches of its length. On section, the inner surface of this growth was found to be ulcerated and softened, and through its substance was a sinuous passage, its diameter not greater than a lead-pencil. Posteriorly and slightly to the left the growth had perforated into the mediastinum, and from thence communicated with the abscess in the right lung. The left lung was slightly emphysematous, and showed considerable œdema. The organs were normal. *March* 8, 1894.

---

17. *Congenital absence of the gall-bladder.*

Exhibited by Dr. Augustus A. Eshner.

The subject from which were obtained the specimens to be presented had been under the care of my friend, Dr. C. F. Pettibone, upon whose invitation I undertook the post-mortem examination and by whose courtesy and with whose co-operation this report is made. The case occurred in a rhachitic colored child, 2 years old, who had never walked unsupported and had presented no symptoms suggestive of any anatomic peculiarity referable either to the biliary apparatus or to other structures. The child had just gotten its first tooth; its ribs were beaded; its chest flattened laterally; the top of its head but slightly convex and its forehead square. It had not yet been taken from its mother's

breast and had presented no noteworthy derangement of the digestive apparatus. The child was the outcome of the first pregnancy of the mother, and no family history of syphilis was obtained, although the previous wife of the father had had two miscarriages. The little patient came under observation on account of a slight but rather persistent cough, with occasional dyspnœa at night. The bowels were moved several times daily, and the stools were pale. There was no jaundice. Upon physical examination no impairment of the pulmonary percussion-resonance was detected, but numerous fine râles were heard posteriorly and at the bases of the lungs. The heart appeared somewhat displaced downward and to the right, but the action was rhythmic and the sounds clear.

The child was lost to observation for a short time, and nothing was heard of it until information came that it had died and a certificate of death was asked for. Upon post-mortem examination the epicardium was found to be injected and the pericardial cavity to contain an abscess of clear fluid. The heart was large and distended with blood. Its cavities were dilated, but the valves and orifices presented no abnormality. Both lungs were involved in an extensive, widely distributed broncho-pneumonia, with, in places, some compensatory emphysema. The angulation and hyperplasia at the junction of the true ribs with their cartilages was particularly marked upon the inner surface. The kidneys presented a striking pallor of the medullary pyramids. A small supernumerary spleen was present. The bronchial and mesenteric glands were enlarged. The ileum was free from ulceration. The liver appeared of normal size and condition. It presented a whitish nodule at its anterior margin, histological examination of sections from which shows the remains of hepatic parenchyma in part in a state of fatty degeneration, together with hyperplasia of connective tissue, accumulations of round cells, and in places homogeneous loss of structure-changes that I take to be of syphilitic origin. The sections that I exhibit show the presence of the hepatic, portal, and biliary vessels, No gall-bladder could, however, be found, either attached to or detached from the liver, or even contained within the structure of this organ. and, as I show you, the usual fissure for the gall-bladder is wanting and there is nothing suggestive of the previous presence of this viscus. Unfortunately, the relations of the hepatic artery, the portal vein, and the hepatic ducts were not attentively observed *in situ*. The usual papilla was found in the duodenum, marking the point of entrance of the choledoch and pancreatic ducts, and from this point a duct could be traced upward for a short distance, but the ducts issuing from the

liver could not be isolated. The portal vein is perfectly evident and displays no abnormality. There is every reason to believe that the blood-supply of the liver was normal and that the functional activity of the organ was in no way interfered with. The case thus clearly resolves itself into one of agenesis of the gall-bladder.

That absence of the gall-bladder is not incompatible with life is demonstrated not only by cases of this kind, in which there is a congenital deficiency of that viscus, and by the cases in which it is wanting as a result of pathological causes post-natal or as a result of surgical interference, but also by the further fact that it is normally wanting in some animals, as, for instance, the elephant, the rhinoceros, the camel, the goat, the deer, some species of fish, some birds, and some rodents.[1] Its *congenital* absence in man seems, however, to be a rare condition. In a partial survey of the literature of the subject I have been able to find but few cases of the kind. The number becomes swelled if cases be included in which the gall-bladder was absent obviously or probably as the result of obliterative processes of one kind or another. I append in chronologic sequence a brief summary of the cases that I have gathered. There are a few others to which I have not had access.

Huber[2] reports having found an absence of the gall-bladder in the dead body of a woman 60 years old. The place of the viscus seemed to be supplied by a preternaturally large hepatic duct, which opened into the duodenum in the usual situation, and the coats of which were greatly thickened, and whose lining membrane presented a villous appearance, with numerous small spots believed to be follicles. The biliary ducts were likewise enlarged.

Cholmeley[3] records the case of an infant that was noticed to be sallow at birth and soon afterward became intensely icteric. The stools were white and pasty. Death took place at the age of five weeks, being preceded by convulsions. Upon post-mortem examination the usual depression in the liver for the gall-bladder was found present, but the viscus itself was replaced by a narrow, impervious cord. The pancreas was enlarged and indurated. It is stated that the transmission of bile into the duodenum was prevented by pressure of the pancreas on the common duct. Cholmeley cites from Morgagni an instance in which the gall-bladder was wanting, but in which two livers were present.

[1] The gall-bladder may be viewed as but an elaboration of structure dependent upon some differentiation of function, representing, as it were, but a diverticulum of the union of the biliary ducts of the liver.

[2] The Philosophical Transactions of the Royal Society of London, vol. ix., from 1744 to 1749, p. 649. London, 1809.

[3] Medical Transactions of the College of Physicians of London, 1820, vol. vi. p. 50.

Gaultier[1] has reported the case of a man, æt. 60 years, with jaundice, who died of tuberculosis, and in whom no trace of a gall-bladder could be found. The duodenum, however, was adherent to the liver by means of fibrous bands. In the bowel opposite the point of entrance of the choledoch duct a large biliary calculus was found. This duct passed directly into the liver without presenting any diverticulum corresponding to a cystic duct.

Baker[2] found the gall-bladder wanting in a subject that came into the dissecting-room. A puckered appearance of the liver in the usual situation of the gall-bladder suggested the destruction of this viscus by some suppurative process.

Bergmann[3] has reported the case of a woman who had long been insane, and in whom after death the left lung was found replaced by two insignificant fleshy masses, the liver enlarged, and the gall-bladder replaced by a small fibrous mass. From the liver a membranous canal passed to the duodenum.

Bergmann cites a case recorded by L'Emery[4] of absence of the gall-bladder, the bile passing from the liver to the duodenum through the numerous small ducts.

Canton[5] has reported the case of a woman, 65 years old, dead of some "disease of the brain," and in whom the gall-bladder was wanting, although a shallow groove for its accommodation was present in the usual situation. The liver was reduced in size. The right and left hepatic ducts were of usual size and diameter, uniting at an angle below the transverse fissure of the liver to form a common choledoch duct of unusual length and calibre, and whose lining membrane presented the characters of the mucous wall of the gall-bladder.

Canton refers also to a case, reported by E. Wilson, of a fœtus born at term that lived but a few hours and presented a number of peculiarities, the most noteworthy of which was an absence of the gall-bladder. Reference is also made to two specimens in the Museum of the Royal College of Surgeons, in one of which the gall-bladder and the hepatic duct are absent, and in the other of which the gall-bladder was replaced by fibrous tissue.

Thomas[6] has reported the case of an infant, 5 months old, that had presented jaundice from the second or third day of life. The child was

[1] Journal de Médecine hebdomadaire, July 11, 1829, tome iv. No. 41, p. 61.

[2] North American Archives of Medicine and Surgical Science, February, 1835, vol. i. No. 5, p. 307.

[3] Hannover'sche Annalen für die gesammte Heilkunde, 1836, B. i. p. 553.

[4] Mém. de l'Acad. des Sci., 1701.

[5] Lancet, 1847, vol. ii. p. 406.

[6] Medical Times, July, 1848, vol. xvii. No. 458, p. 171.

able to suckle, but vomited a little daily. The bowels were irregular; the stools were white or clay-colored. A week before death anasarca and ascites developed. Upon post-mortem examination not even the rudiments of gall-bladder or cystic or hepatic ducts could be found. The liver weighed 14 ounces. Microscopically its cells were found filled with yellow, granular matter, without much fat. The mesenteric glands were enlarged. Two glands in the longitudinal fissure were softened.

Trimble[1] reports the case of a woman, 55 years old, who for several months had presented epigastric pain, nausea, occasional vomiting, furred tongue, pyrosis, anorexia, constipation, emaciation, and ascites. After death there were found inflammatory adhesions about the pancreatic and choledoch ducts. The liver was reduced in size, and in one situation attached to the pancreas. Here it was of cartilaginous hardness, and on section was found to contain a gall-stone imbedded in the common choledoch duct. Careful examination failed to disclose the presence of even a vestige of the gall-bladder.

In 1860 Simpson,[2] before the Edinburgh Obstetrical Society, reported the case of a child 4 weeks old presenting a condition with features both of erysipelas and scleroderma. In the sixth week vomiting suddenly set in, and was soon followed by death. Upon post-mortem examination there were found present evidences of peritonitis. The gall-bladder could not be found, and there was no depression corresponding to its usual site. The common choledoch duct opened into the duodenum in its usual situation. The duct could be traced backward to the transverse fissure, where it broke up into the hepatic ducts.

In 1865 Sands,[3] before the New York Pathological Society, reported finding in the dissecting-room, in a tuberculous male subject about 20 years old, a liver without a gall-bladder and without a fissure for its lodgement. The liver was small, weighing 1¾ pounds, and its quadrate lobe was wanting.

Lynche[4] has recorded the case of an infant, 11 months old, in which icterus made its appearance a few days after birth, the stools presenting a dead-white appearance. Later on the child manifested a tendency to hemorrhage. After death the liver was found to be large, weighing 1 pound and 2 ounces. The hepatic ducts were small, but there was no trace of a gall-bladder, whose place appeared to be taken by an enlarged cystic duct.

[1] New Jersey Medical Reports and Transactions, 1850, vol. iii. p. 303.
[2] Edinburgh Medical Journal, 1861, vol. vi. part ii. p. 1045.
[3] New York Medical Journal, June, 1865, vol. i. p. 222.
[4] Medical Press and Circular, 1875, n. s., xx. p. 362.

Rambault and Schachmann[1] have reported the case of a paretic dement who after death presented, in addition to the classic lesions of paretic dementia, a small liver with absence of the gall-bladder, the fossa for this viscus being replaced by a shallow fissure. There was no indication of a cystic duct. The hepatic ducts presented no abnormality. During life there had been no symptoms suggestive of the absence of the gall-bladder.

It will be seen, even on superficial analysis of the cases collated, that in most of them the absence of the gall-bladder was associated with conditions that point to obliteration of a previously existing viscus rather than to a condition of agenesis such as I conceive to have been present in the case now reported. *April* 12, 1894.

---

18. *Carcinoma of the liver and stomach.*

Exhibited by Dr. John Zimmer for Dr. Musser.

A. E., aged 63 years, white, American, widower, laborer.

*Family history.* One sister died of mammary carcinoma, another of hepatic carcinoma; otherwise negative.

*Previous history.* No specific history; uses alcohol and tobacco to excess: otherwise negative.

*History of present condition.* First subjective symptoms appeared about the first part of January, 1894. Had pain, more or less constant, over the front of chest; some dyspnœa, digestive disturbances, obstinate constipation, and gradual failure of strength, accompanied by loss in weight.

Observations made February 16, 1894, are as follows:

*Lungs.* Emphysematous; otherwise negative.

*Heart and vessels.* Radials are decidedly thickened. Heart-sounds weak and irregular; otherwise normal.

*Liver.* Percussion develops flatness, beginning at fourth interspace in mid-clavicular line and continuing downward for 16 cm. In axilla it begins at upper border of sixth rib and extends downward to margin of ribs, a distance of 18 cm. Posteriorly dulness begins at angle of right scapula. In the median line anteriorly dulness extends to within 3 cm. of umbilicus and is 10 cm. below the tip of xiphoid.

[1] Bulletin de la Société Anatom. de Paris, 1882, lvii. ann., 4e sér., tome vii. p. 499.

On palpation a large nodular body is felt just above and to the left of the umbilicus, and on deep palpation several nodules are felt projecting from this tumor.

Abdomen slightly distended. Bowels obstinately constipated.

Examination of urine negative; specific gravity 1018; acid.

Legs are slightly œdematous. Face suggestive of cachexia. Conjunctivæ slightly icteroid.

Subjective symptoms are distress in stomach, more marked after eating, and a dull pain in region of umbilicus. The abdominal tumor is quite tender on pressure.

Under the use of restricted diet and silver nitrate patient's gastric symptoms were much improved. Blood-examination, 4,400,000 and 60 per cent. on March 15, 1894.

Temperature fluctuated from 98° to 100° until about March 6, 1894, when it became distinctly hectic in type.

On March 20th patient became suddenly much weaker, and there were frequent attacks of vomiting, rapid and running pulse, and pain in epigastric region. Temperature 95°.

For next three days was unable to retain anything in the stomach. Temperature fluctuated from 95° to 97¾°. Pulse weak and irregular. Patient never rallied from this state of collapse, and died March 23, 1894.

*Post-mortem* performed at 4 P.M. of same day by Dr. Jameson.

*Abdomen.* Abdominal cavity contains about two quarts of a yellow-colored fluid. The diaphragm is everywhere firmly adherent to the liver on the right side. Gall-bladder not distended and free from adhesions.

*Heart.* Mitral leaflets show some thickening, and a few patches of atheroma. Sinuses of Valsalva are atheromatous.

*Lungs.* Left lung shows pronounced emphysema; otherwise negative. Right lung shows pneumonic consolidation of the entire lower lobe; otherwise negative.

*Kidneys.* Show evidence of a chronic interstitial nephritis.

*Spleen.* Normal.

*Duodenum.* Normal.

*Stomach.* Between stomach and pancreas there is a patch of recent peritonitis covered with plastic lymph. This area is almost as large as the palm of the hand. On the postero-inferior wall of the stomach is an ulcer showing necrosis of the tissues of the outer coat of the stomach This ulceration is continuous with the patch of peritonitis, and is apparently the cause of it. The stomach contains a small amount of fluid

On the posterior wall opposite the œsophageal opening there is a cancerous mass about two and one-half inches in diameter and one-half inch in thickness. In the centre of this tumor there is a depression, less than one-quarter inch in diameter, which seems to communicate with the area of ulceration above noted. The continuation of the opening cannot be demonstrated with certainty.

*Pancreas.* The pancreas is adherent to a mass of enlarged glands which are bound to the transverse fissure of the liver. The body of the organ seems to have escaped involvement.

*Liver.* Weight four and one-half kilogrammes, or a little over nine pounds. The length is very little increased; the increase in size is in thickness. The surface of the organ shows more than a dozen large secondary cancerous nodules, the largest being almost three inches in diameter. The centre of the large nodules is depressed. The color in the centre is yellow, and toward the periphery it becomes pink. Between the large masses there are innumerable small ones of various sizes.

*Small intestines.* In lower portion of the ileum there is a neoplasm one-quarter inch in diameter lying immediately under the mucous membrane, and another one-half inch in diameter immediately under the peritoneum.

*Large vessels.* Show some areas of atheroma.

Dr. Guitéras remarked upon the rarity of tubular epithelioma of the liver. *April* 12, 1894.

---

## 19. *Gall-stones.*

Exhibited by Dr. W. S. Carter.

These specimens, which were given to me by Dr. Dunton, of Germantown, are from a married woman, aged 45 years, who died from a fractured skull with cerebral hemorrhages, the result of an accident.

Her friends say they never knew her to have a sick day in her life. Her bowels had been regular, and she had never had any jaundice or bilious attacks. She never complained of any pain, but drank intoxicating liquors every time she got her money—about every two weeks.

Outside the cranial cavity nothing of interest was found except this dilated gall-bladder, which contained twenty-seven stones of varying sizes. The bladder is dilated and the wall thickened. Ducts were patulous. On microscopic section we find something of greater interest. In

the walls of the bladder are numerous collections of round cells in the muscular coat; evidently they are the beginning of abscess-formations. The surface is denuded of its epithelium, but I cannot say that this was not done at the autopsy. *May* 10, 1894.

---

20. *Amœbic abscess of liver.*

Exhibited by Dr. J. D. Steele.

F. B., aged 48 years, born in Ireland, resident in Philadelphia for twenty years past. Nothing of interest in family or personal history up to the time of his last illness. When attacked he was working on some street improvements. Twelve days before admission he was overheated, and soon afterward attacked by diarrhœa. His stools were at first watery and contained fecal matter, but soon were smaller and consisted of blood and mucus. Upon admission he showed the following symptoms:

Frequent stools, small in amount, and consisting entirely of blood and mucus; considerable pain and tenderness in his abdomen, and some tenderness in left iliac fossa, considerable prostration, with some slight elevation of temperature.

Physical examination showed a mitral murmur, but beyond that nothing of interest in the thoracic organs. The liver extended from seventh rib to costal margin on the right mammary line. The stools were not examined for amœba coli. Under appropriate treatment the signs of acute inflammation of the rectum gradually disappeared, and eight days after admission the stools did not contain blood or mucus, and averaged two in the twenty-four hours.

From this date on they were thin, semi-liquid, light-brown, and contained lumps of fecal matter, but no blood or mucus. The temperature ranged from 98° in the A.M. to 100° or 101° in the P.M., and the chart strongly suggested a septic process.

On the twenty-fifth day after admission the patient complained of considerable pain over liver in front, with tenderness on pressure. Liver wss somewhat enlarged, commencing at the seventh rib and extending three fingers' breadth below the costal margin, in the mid-clavicular line. The right lobe steadily increased in size, and five days later the upper limit reached the fourth interspace above and extended four and one-half inches below the costal margin in the mid-clavicular line. There

was slight distention of abdomen with some tenderness and tympanites. At 2.30 P.M. of same day the patient suddenly went into collapse. There was marked distention of the abdomen, and great tenderness over its whole extent. Some vomiting of bile-stained material occurred. There was dulness over the hepatic area in front, excluding the possibility of air in the peritoneal cavity.

The symptoms of profound collapse persisted, and the patient died four hours later.

*Autopsy.* When the abdomen was opened a sero-purulent fluid welled out, containing flakes and masses of thick coagula. There were many recent adhesions between the great omentum and the intestine. The intestines near the cæcum were matted together by rather older adhesions. Appendix firmly adherent and points into the pelvis. The hepatic flexure of the colon, lesser curvature of the stomach, duodenum, and right kidney are firmly adherent to the under surface of the right lobe of the liver. The pus in the right upper quadrant of the abdomen is rather thicker than elsewhere. The abdominal cavity contains 2.5 quarts of this sero-purulent material. The right lobe of the liver is much enlarged by an enormous abscess that showed a point of recent rupture in its upper wall. The upper border of the liver reaches to the fourth rib.

*Right pleural cavity.* The costal and parietal layers of the pleura are united by recent adhesions. These are very firm between the lung and the diaphragm. The lung is compressed on this side and congested, but shows no evidence of abscess formation.

*Cæcum.* Walls thickened, and in the surface of the mucous membrane are four ulcers with greatly infiltrated edges. These are covered by a thick grayish slough. Appendix is patulous and apparently free from disease.

The colon showed numerous grayish ulcers covered with mucus and with undermined edges. The ulcers increase in number as the colon nears the sigmoid flexure. In the sigmoid six inches from the rectum is a large round ulcer with infiltrated edges, which are undermined and overhang the ulcer. Similar ulcers are found through the sigmoid flexure and rectum. Liver weighs 2240 grammes. Surface of left lobe is rough and scarred, showing some interstitial change; on section its parenchyma is harder than normal. The right lobe is almost entirely taken up by an abscess cavity measuring 13 cm. in diameter, and containing about a pint of thick, creamy white pus. Microscopical examination of this pus and the scrapings of the rectal ulcers showed amœba coli. The point of rupture of the abscess was in its upper wall.

*November* 8, 1894.

21. *Appendicitis caused by lodgement of a pin in the appendix, with secondary multiple abscess of the liver.*

Exhibited by Drs. De F. Willard and James Hendrie Lloyd.

D. S., a boy, aged 9 years, had been in the Home for Crippled Children for four years for spinal caries. There never had been abscesses nor evidence of secondary tubercular disease in any organ. The patient's general health was good.

The present disease began with vomiting, which was not associated at first with marked abdominal pain. There was an irregular range of temperature. On the third day abdominal pain was complained of, vomiting continued, and the patient's condition indicated more serious disease than was at first suggested by the rather mild initiatory symptoms. On the fourth day it became evident that peritonitis had set in; the belly became distended and exceedingly painful; the patient lay with both legs drawn up and with a pinched, anxious expression. Toward the evening of that day collapse seemed to be threatened; the pulse became rapid, thin, and wiry; the temperature rose as high as 103°, and the child was supported with difficulty. Because of delay in obtaining requisite permission operation was not resorted to until the sixth day, when it was already evident that it was too late. The incision was made over the region of the appendix; pus and flakes of lymph were evacuated. The appendix was not removed. The abdomen was full of a thick purulent fluid. The child rallied after the operation, but lived for less than a day.

At the *autopsy* the condition ordinarily seen in purulent peritonitis was found. The peritoneum was intensely inflamed over most of its extent; the intestines were matted together in places by adhesions; a thick pus was present in abundance, but the appendix at first sight did not present the appearance of marked change. The liver was swollen, and on the surface of the left lobe were seen deposits of pus beneath the capsule; at one point one of these deposits had ruptured, probably in course of removal of the organ from the body, and was pouring out a thick yellow pus. On incision, the left lobe especially was found honeycombed in parts with sinuses and deposits containing pus and communicating with one another. On close inspection, after removal from the body, the appendix was found perforated at a point near its base; around this perforation were signs of inflammation. On laying it open

the appendix was found to contain a large black pin, with its head toward the cul-de sac and its point projecting from the opening. Especial care was taken to examine the bodies of the carious vertebræ *in situ*, approaching them from within. They were well covered with healthy-looking tissues, and there were no signs of a beginning abscess from them. A specimen of the pus from the liver was examined by Dr. Jump, the assistant physician, but no bacilli of tubercle were found in it.

It seems probable that the course of events was as follows: the pin caused an irritation and finally a perforation of the appendix; the peritonitis was secondary to the perforation; the abscess in the liver was caused by the absorption of pus from the ulcerated appendix. The question of whether the peritonitis could have been secondary to the abscess in the liver, and have been caused by a rupture of one of its purulent deposits, may be raised. Also the question, on the other hand, whether the multiple abscess of the liver could have been caused by absorption of pus from the inflamed peritoneal surfaces. These are purely pathological questions; the practical point here is that all this extensive infection came within a week from the inflammation caused by a foreign body in the appendix. We do not think that the chronic indolent carious process in the vertebral bodies had anything to do with the condition here described.

Dr. Packard reviewed an autopsy in which he had assisted which was similar in every respect except that there was no peritonitis, and the subject was an adult woman.

Dr. Scott remarked that the fact that the child had Pott's disease is important, because of the fact that much appendicitis is tuberculous.

Dr. Hughes thought there might be general peritonitis without more local trouble or disease of the appendix than there is here.

The President considered the cause was probably, first: ulcer of the appendix due to the pin, then abscess of the liver, and finally peritonitis.

Dr. Lloyd said there certainly was no evidence of beginning tubercular dissemination in the case. In regard to the rapidity of pyæmic abscesses, he considered them more rapid than has been stated.

Dr. Willard said there was a great deal of inflammation in the region of the appendix. As to the appendix itself, a black hole through it was at once seen. He thought the abscesses were subsequent to the perforation of the appendix. *November* 22, 1894.

## 22. *Intussusception with rupture of the bowel and abscess of the peritoneum.*

Exhibited by Dr. Charles H. Miner.

W. M., a painter, aged 45 years, born in Maryland, admitted November 9, 1894.

*Family history.* His father died at sixty-five years of general debility. His mother died at forty-two years of erysipelas. He had five brothers and three sisters. One brother died when three years old; the others are living and healthy. Patient has been married twelve years. He has five children, who are all living and healthy.

*Personal history.* He had the usual diseases of childhood. He had diphtheria when thirty-six years old; he had malaria and an attack of lead-colic fifteen years ago. Had influenza last year. His habits were good, and he denies specific infection.

*Present illness,* he says, commenced four months ago with a mild attack of lead-poisoning, but he kept on working till September, when he had lost flesh and strength and developed a constant fever. He was then treated for lead colic and acute cystitis. He passed urine in small amounts and at frequent intervals. The symptoms of lead-poisoning soon disappeared, he says, but the fever and loss of appetite and strength continued. For the last three weeks he has had a chill every day, associated with a rise of temperature and a profuse sweat. He complains of fulness and distress after eating, flatulence, and constipation. Before admission he took mercury and iodide, and finally large doses of quinine.

On admission the patient was emaciated, the mucous membranes anæmic, and the skin pigmented, especially over the face and forearms. The pupils are equal and react to light and distance. The tongue is red, clean, and moist. The pulse is regular, small, weak, and very comprehensible. The chest is fairly well formed. The costal angle is obtuse, with a depression of the xiphoid process. The respiratory movements are normal. Examination of the lungs is negative. The apex-beat is in the fifth interspace, mid-clavicular line. There is pulsation of the vessels of the neck. The heart-sounds are weak, sharp, and clear. The hepatic dulness extends from the sixth rib to the costal margin. The specific dulness is not obtainable. The abdomen is somewhat distended, is tympanitic, and tender in the lower half. Just

above the symphysis there is dull tympany on percussion and a sense of resistance on pressure, as though the bladder was large and distended.

The urine is red in color and acid, with a specific gravity of 1025, and contains no albumin or sugar. The blood-cells are normal in size, color, and outline. The pigment is about normal in amount. There were no intracellular bodies discovered, and no apparent leucocytosis. The blood-count showed 4,800,000 red blood-cells, and there was 80 per cent. of hæmoglobin. On examination of the rectum a hard nodular mass was found above the prostate and close to the bladder, which was felt the more when deep pressure was made above the symphysis pubis. The rotation of a sound in the bladder gave the sensation of a rough thickened membrane. The testicles are normal, and there is no enlargement of the inguinal glands. He has external hemorrhoids, which occasionally bleed. The examination of the rectum is painful, but he does not complain of any pain or tenderness when pressure is made against the mass. The bowels after admission were loose; the movements liquid, light yellow in color, and did not contain any blood or mucus. Later the bowels were constipated, but there has been no obstruction. The fever was intermittent. The evening temperature ranged between 100° and 103°. He had no marked chills till ten days after admission, when they occurred every third or fourth day and increased in severity. On the 3d of December he complained of a sharp pain in the abdomen, followed by vomiting and a rise of temperature to 103°.

He developed an acute peritonitis, and rapidly went into a condition of collapse and died the next morning.

The following notes were made by Dr. H. W. Cattell at the autopsy:

The body of an emaciated male of 45 years, weighing 145 pounds. Abdomen tense; testicles normal; no scar discovered on penis. Conjunctiva is clear; no rigor mortis. Practically no post-mortem lividity.

On superficial examination of the abdominal cavity there is seen to be about 1500 c.c. of a cloudy liquid, having a strong fecal odor. The peritoneum shows signs of inflammation recent in character, and is especially marked in a thick pyogenic membrane on the anterior portion of the liver. The intestines are so matted down that it is impossible to distinguish the normal relations of the parts. On careful dissection the sigmoid flexure and rectum are found to be intact and take no part in the tumor hereafter to be described. The bladder and ureters were normal. The intestines are distended with gas and liquid feces. A point of perforation is seen just above the right inguinal region. On dissection this is seen to arise from a pyogenic, but well-

organized connective-tissue membrane, the size of a fœtal head. The walls of the mass are formed by various loops of intestines, new membrane, and the normal parts in this region. The entrance of the bowel into this tumor is distinct from the bowel which goes out from it. The cavity is fairly well filled with fecal material and with an organized shred-like membrane markedly infiltrated with small, rounded, solid substances resembling grains of sand. About a foot above the point of entrance of the ileum into the above-described tumor is apparently a healed intussusception, the lumen being held in place in part by a wall of new connective tissue. About the same distance from the point of exit is a gangrenous and apparently slightly twisted intussusception, the mass lying in close juxtaposition to the right lobe of the prostate. The prostate being slightly enlarged, the ileo-cæcal valve is about four inches from this point. A normal vermiform appendix comes off from the caput coli, which has been slightly pushed up by the above-described mass and runs underneath the ileum in almost a straight line toward the vertebral column, a distance of about three inches, the tip pointing toward the spleen. On section the mucous membrane is seen to be normal. Lungs and heart are practically normal. The spleen is enlarged and shows a number of small calcareous masses scattered throughout the splenic substance. The right adrenal is slightly pigmented. The kidneys are anæmic, with perhaps slight parenchymatous nephritis. Liver shows graying of veins. Pancreas normal.

The President said he had seen this case six weeks before admission. He then had moderate emaciation, with intermittent fever. There were no marked evidences of tuberculosis at that time. The rectum was not then examined. After admission to the hospital his rectum was examined and a mass discovered which was nodular and hard. The coexistence of fever then suggested tuberculosis of retroperitoneal glands. A sound in the bladder seemed to strike a nodular mass. At autopsy the conditions named were found. The fecal concretions were extremely hard. It seemed as if the intussusception might have occurred during an attack of lead-colic. *December* 13, 1894.

23. *Perforating gastric ulcer in a man of 50 years.*

Exhibited by Dr. RIESMAN.

The patient from whom this specimen was removed at autopsy was in the care of Dr. Bauer, of this city, who has kindly furnished me the clinical history.

The patient was a large, well-built man, 50 years of age, a German by birth. He had always been in good health and had all through life indulged freely in the pleasures of the table, both liquid and solid. Two years ago he began to complain of dyspeptic symptoms and had at irregular intervals excessive flatulence and vomiting. These attacks were always attributable to indiscretions in diet and yielded readily to calomel and soda. In the summer of the present year he paid a visit to Germany, and, at the suggestion of Dr. Bauer, spent a few weeks at Carlsbad. He returned at the end of August, feeling, as he expressed it, "like a well man." One Saturday night, a week or more after his arrival in Philadelphia, he was seized with pain in the stomach and gaseous distention. A carminative relieved him considerably; he was much better the following day, but unable to leave the house. On Monday the pain returned and was very severe in the region of the liver; the abdomen became distended, signs of shock developed, and death took place at 2 A.M., Tuesday, in collapse.

There had not been during the two years of dyspeptic disturbances any vomiting of blood, nor any noteworthy pain—nothing, in fact, indicating the existence of a gross and serious lesion.

The autopsy was made thirty-two hours after death.

*Autopsy.* Body of a middle-aged male, of more than average height, well nourished. No jaundice; marked abdominal distention.

*Abdominal cavity.* There is a great deal of subcutaneous fat. The peritoneal cavity is filled with gas, which escapes with a loud, whistling noise through the opening in the peritoneum. The gas smells strongly of $H_2S$. The peritoneum, both parietal and visceral, is of an intense red color, due to the injection of the bloodvessels and small hemorrhages. A large quantity of dirty-brown, thin, opaque, non-purulent fluid is present, the larger amount being collected under the diaphragm in the left hypochondriac region. The fluid is not offensive and seems to contain but little if any blood. The intestinal coils are adherent to each other, the adhesion being in the main due to stickiness; in a few places to false membranes. In places small patches of greenish-yellow lymph

are seen, one of considerable size being found on the anterior surface of the stomach just below the lesser curvature. The intestines are not remarkably distended with gas. The omentum is curiously rolled up on itself, a condition which seems to have probably been brought about by the sudden escape of gas. The appendix is normal. The diaphragm extends to the fourth rib on the right and to the fifth on the left side.

On lifting the anterior edge of the liver the cause of the peritonitis becomes at once visible. Just to the left of the pylorus, and a little more toward to the upper than the lower edge, there is a sharply defined circular perforation in the stomach, about $\frac{3}{4}$ cm. in diameter. The gastric contents are issuing from the opening in the form of a thin slate-colored liquid. The perforation corresponds in position almost exactly with the longitudinal fissure of the liver, and is just to the left of the gall-bladder. There is no inflammatory reaction in the immediate vicinity of the opening, but on the under surface of that portion of the left lobe of the liver, which directly overlies the perforation, there is a dark, blackish stain, but no inflammation.

The perforation viewed from the peritoneal surface seemed to be, if such a thing be possible, an old one; it had a distinctly fibrous margin, from which in all directions fibrous bands are seen to radiate. The opening is sharply cut, regular, and appears as if punched out. The perforation is just within the pylorus, its diameter being a trifle *smaller in the gastric than in the serous surface.* There is here, *i. e.*, on the gastric aspect of the perforated ulcer, no second inflammatory reaction whatever. The wall of the stomach is thickened toward the pylorus; a few ecchymoses are present. The *kidneys* were in a state of cloudy swelling. The other organs presented nothing of special interest.

*Pathologic diagnosis.* Perforation of gastric ulcer; acute septic peritonitis with effusion; cloudy swelling of kidney.

*Microscopic examination.* The wall of the stomach in the neighborhood of the ulcer shows an absence of glandular structure; in order not to destroy the appearance of the ulcer pieces have as yet not been removed from its margins.

*Remarks.* Gastric ulcer may occur at any period of life, from infancy to old age, but is most common between the ages of twenty and forty, and in the female sex. It is not rare in men, and in them seems to become frequent at a somewhat later period in life than is the case in women.

Regarding the seat of ulcer the statistics of Welch[1] show that the lesser curvature and the posterior wall are far more frequently selected by the ulcerative process than any other part. In men the preference

is, according to Stoll,[2] for the pylorus, as we note in this case; in women for the lesser curvature. Perforation occurs in about 6.5 per cent. of cases (Welch), but is three times more common in women than in men. In acute ulcers perforation occurs much more frequently, Leith[3] estimating the proportion as more than 30 per cent. Rupture is concurrent in ulcers of the anterior wall, a fact generally attributed to the greater movement of that part of the stomach, the formation of adhesions being thereby prevented.

The immediate cause of perforation is usually mechanical distention of the stomach with food or gas or a violent strain. In this case there is a distinct history of excessive flatulence shortly before death. The shelving character of the ulcer indicates that the corroding process had advanced almost, if not quite, down to the serous coat.

The fibrous edges show that an unsuccessful attempt was made in healing, and also that the ulcer is of rather long standing. In view of this it is surprising not to find any adhesions to a neighboring viscus; but this may be readily explained by the fact that the pylorus is the most movable part of the stomach.

The edge of the ulcer is very sharply defined, and there is, contrary to what we would expect, a total absence of shreds of peritoneum, the remains of the delicate diaphragm that formed the base of the ulcer. This peculiarity has also been noted by Orth.[4]

In regard to the primary cause of this ulcer it would be difficult to give a positive opinion. The etiology of gastric ulcer is admittedly obscure, so many theories are offered that the choice of one to fit a particular case becomes embarrassing.

At the present time it is pretty well recognized that two factors play a paramount part in the pathogenesis of the ulcer: First, a weakened condition of a localized area of mucous membrane; and, secondly, the digestive action of the gastric juice. The first-named factor is probably the *sine qua non*, but exactly how such a vulnerable state is brought about remains to a large extent a mystery. Most recent writers attribute it to a local disturbance in the circulation, in its essence an obstruction of the arteries. This obstruction has been ascribed by Virchow[5] to embolism or thrombosis. In regard to embolism, experiments, particularly those of Soltau Fenwick, seem to show that only a small proportion of emboli find their way into the gastric arteries, and then as a rule chiefly into the cardiac branches. Nor have emboli, or a possible source of emboli, been found in any significant number of instances of true gastric ulcer. Leith, in three cases studied with admirable care, found obliterating endarteritis, a thrombus occluding the main vessel

leading to the ulcer. But, as he himself admits, the possibility of the ulcer having preceded and caused the thrombosis cannot be gainsaid, although it is unlikely.

It is scarcely necessary to dwell upon all the theories that have been advanced since Cruveilhier[6] and Abercrombie[7] first described the round ulcer and attributed it to inflammation. The most important point in connection with the peptic ulcer is, after all, not the primary cause, but the failure to heal. In experiments upon animals it has been found that, no matter how produced, whether by artificial emboli, as in Fenwick's[8] experiments, or by direct mechanical injuries, by ligation of vessels, or by the introduction of corrosive substances, the ulcers healed rapidly, as a rule in from ten to fifteen days. When in addition to the local injury, the general health of the animal was reduced to a low level by bleeding (Quincke and Daettwyler[9]) or by the production of hæmoglobinæmia (Silbermann[10]), healing was delayed, and in one instance perforation took place. Ulcers created experimentally differ, therefore, very markedly from those arising spontaneously in man, in that they habitually tend to heal promptly, while the typical peptic ulcers do not. It is, indeed, as Welch pertinently remarks, more difficult to explain why ulcers in the stomach do not heal than it is to understand how they are produced.

If we examine microscopically the edge of a typical ulcer we shall find no round-cell infiltration, no dilatation of the bloodvessels. At times the latter are seen preternaturally empty, as in case of ulcers of the œsophagus reported to this Society by Prof. Guitéras.[11] We miss, therefore, about the ulcer the signs of the inflammatory process, without which healing cannot take place. It may possibly be said that the ulcer does not heal because there is no inflammation.

This proposition does not, however, elucidate the non-healing completely, but advances the solution of the question a step further. For we now ask why there is no inflammation in response to loss of so much substance, the place of which would elsewhere be speedily filled? It has been surmised (Ziegler, ii. p. 515) that the causes are similar to those which originally give rise to the ulcer, a hyperacid gastric juice or unfavorable circulatory condition, or both combined. Letulle[12] believes that the ulcer is able to spread on account of a hyaline degeneration in the connective-tissue cells that are formed about it.

In regard to hyperacidity, it is now known that it is far from being constant. Kugel (quoted by Stoll[13]) found it only in 22 per cent. of cases; Rosenheim[14] in two out of eight. At times the HCl is below normal, and, in a few instances, has been entirely absent.

If we study the clinical course of cases of gastric ulcer, we find as an almost invariable occurrence that the patient gives a history of long-continued dyspepsia. May this condition not play an important part in preventing the cicatrization of the ulcer? These dyspeptic disturbances are characterized by the imperfect and perverted digestion of the food, principally of the proteids. The faulty digestion leads to the formation of poisonous compounds of the nature of peptones, although probably not all of the toxic substances are chemically peptones. Peptones, as the beautiful experiments of Buchner[15] and Gabritchewsky[16] have shown, exercise a peculiar influence upon tissues. They are, as it is called, negatively chemotactic, *i. e.*, they are unable to cause a round-cell infiltration.

It is at present admitted by most pathologists that chemotaxis plays an important part in inflammation, perhaps it is indispensable, and that only such irritants as possess the power of positive chemotaxis, of provoking an out-crowding of cells, are capable of exciting the inflammatory process.

Furthermore, it is possible, according to the views of Metchnikoff[17] and of Leber,[18] that the advection, if not the primary formation of the new bloodvessels in the healing of wounds, is entirely under the influence of the chemotactic or a similar force. Reasoning on these facts, as peptones do not possess chemotactic properties, the question suggests itself: May not the peptone, like bodies formed in excess by disordered digestion, or perhaps by the peptonizing action of the gastric juice at the site of the ulcer, be the cause of the non-healing?

## Bibliography.

1. Welch: Pepper's System of Medicine, vol. ii.
2. Stoll: Deutsch. Archiv für klin. Medicin, Bd. 53, Heft 5 und 6.
3. Leith: Edinburgh Hospital Reports, 1894, vol. ii.
4. Orth: Pathologie der Verdaungsorgane, p. 738.
5. Virchow: Virch. Archiv, Bd v. Quoted by Leith, Welch, and others.
6. Cruveilhier: Anatomie path. du corps humain. Quoted by Leith.
7. Abercrombie: Pathological and Practical Researches on Diseases of the Stomach.
8. Fenwick, S.: Journal of Pathology and Bacteriology, vol. i. p. 149.
9. Quincke and Daettwyler: Cor. Blätter f. Schweizer Aerzte, 1875, S. 101. Quoted by Leith.
10. Silbermann: Deutsch. med. Woch., 1886, 29, S. 497. Quoted by Leith and by Ewald.
11. Guitéras: International Medical Magazine, November, 1894.
12. Letulle: L'Inflammation, p 432.
13. Stoll: Loc. cit.
14. Rosenheim: Deutsch. med. Woch., 1888, 22.
15. Buchner: Centlbl. f. Bakteriologie und Parasitenkunde, 1891, 416, 666.
16. Gabritchewsky: Ann. de l'Instit. Pasteur, 1890, iv.
17. Metchnikoff: Comparative Pathology of Inflammation. Translated by F. A. and E. H. Starling, p. 189.
18. Leber: Die Entzündung, 1891, p. 505.

*December* 13, 1894.

### 24. *Adenoma and fibroma of the stomach.*

Exhibited by Dr. Alfred Stengel.

*Polypoid Adenoma of the Stomach.* This specimen was taken from the body of a woman who was a patient of Dr. J. C. Wilson, at the German Hospital. The symptoms and general appearance of the patient were those of pernicious anæmia. The age of the patient was 65 years or more. Her condition steadily grew worse despite treatment.

*Post-mortem.* The general appearances of pernicious anæmia were discovered, and in addition the condition of the stomach noted above. The size of the organ was not materially abnormal. On opening it there was found a rather granular appearance of mucous membrane, typifying the form of gastritis sometimes called granular. In the fundus of the organ was found a small polypoid elevation about 1.5 or 2 cm. in length and 0.5 to 0.75 in thickness. This was attached to the wall by one end and partially along the side; the other end was free for a certain distance. Microscopically this growth was found to consist of a rich mass of glandular acini, resembling the normal gastric tubules, but having no apparent typical structure.

*Fibroma of the Stomach.* The specimen exhibited was removed post-mortem in a case in which gastric symptoms had not been striking. There was found on the outer wall of the stomach and beneath the serous coat a small nodular spherical tumor, about the size of a walnut. This was quite firmly attached and seemed to spring from the subserous connective tissue. On section it was found to be of dense hardness, and microscopically was fibromatous in character without any smooth muscle-tissue. The absence of the muscle-fibres is specially noted, as cases have been recorded of myomata having this situation and the general characters here presented. The tumor appears to be a pure fibroma.

*December* 13, 1894.

---

### 25. *Mucous casts from the bowel.*

Exhibited by Dr. H. B. Allyn.

The specimen presented came from a young married woman, about ten days or two weeks after confinement with her first baby. She was a neurotic patient, but not to an extreme degree, and had herself under

good control. The only known disease was mitral insufficiency. She passed through pregnancy and labor without embarrassment; final delivery, however, was with forceps, owing to uterine inertia.

The cast exhibited followed an injection of glycerin to overcome constipation. When I first saw it, it was about six or eight inches long, and looked very much like an umbilical cord, except that all blueness due to veins was absent. The tissue was very friable, and has become much broken and disintegrated since its expulsion. The structure of this, as of other casts I have examined, is a homogeneous base filled with leucocytes and occasional blood-cells, free nuclei, epithelial cells, and fecal matter.

This second specimen was sent to me by Dr. R. M. Girvin, who tells me that the patient suffered with extreme abdominal tenderness during pregnancy and after confinement, the tenderness being greatest over the right ileo-cæcal region. Although there was no fever or evidence of peritonitis, the abdominal tenderness was so great that walking across the room was painful, and the patient could not bear to have the bed-clothing touch her.

Another patient has passed at intervals, during several weeks, gelatinous material from the bowel. The portions I saw were faintly yellow in color, thin, and flimsy like broad ribbon. Since the casts have been noted in the stools there has been tenderness in the epigastrium, but especially in the left hypochondrium. On some days the patient would be comparatively or wholly free from pain, but usually tenderness could be elicited by pressure along the upper portion of the descending colon. At times she had severe paroxysmal pain in the regions described. This pain occurred at night, usually waking her out of sleep, and lasting several hours, leaving the patient exhausted the next day. After such a paroxysm of pain the stools on the following day contained the mucous casts described. I am not sure whether or not this was the invariable sequence. The pain was relieved by hot applications, but often continued with diminished severity on the following day. The bowels had been costive since these attacks began. The patient is aged 64 years, married, but having no children. No cause can be assigned for the attack in this instance, unless it be chilling of the surface while suffering temporarily from indigestion. No stricture of the rectum could be felt. She has a double mitral lesion, but suffers no apparent inconvenience from it.

In still another case, occurring in a young married woman under 30 years of age, mucus has been passed for a number of years, following a confinement in which the bowels were allowed to remain constipated

for two weeks; ulceration and resulting stricture followed. This patient was of neurotic temperament. There has been some improvement in the mucous colitis and proctitis since the stricture was dilated and stretched. The symptoms in this case were pain, tenesmus, constipation alternating with diarrhœa, and depression of spirits. The uterus was partly retroverted.

The best description of this disease I have seen is by a former member of this Society, Dr. W. A. Edwards. From his papers it is evident that the disease occurs almost exclusively in females. Whitehead reports 100 cases, only 4 of which were in men; while Field says that 80 per cent. of the recorded cases occur in women.

While the precise cause of this affection is not known, the cases reported can be described as cases in which there has been disease of the intestinal or genito-urinary tract, associated with a hysterical or, at least, neurotic temperament.

Dr. Miller recalled a case of typhoid fever in a child aged 12 years, in which case considerable amounts of casts were passed during convalescence. This continued four or five weeks without pain.

Dr. Coplin asked if the casts had been stained for fibrin by the Weigert method.

The President remarked upon the occurrence of pain in these cases as in fibrinous bronchitis.

Dr. Allyn, in reply to Dr. Coplin, stated that no staining had been done. *December* 27, 1894.

---

26. *Carcinoma of the colon.*

Exhibited by Dr. W. E. Hughes.

The primary growth was in the sigmoid flexure. There was a growth in the rectum not involving the mucous membrane, and several others above, similarly situated beneath the mucous membrane and probably in the muscular coat. The colon was dilated above and the lumen somewhat narrowed below. The wall of the whole colon above the growth and even that of the appendix was thickened. Secondary growths were present in the fissure of the liver and at the hilus of the spleen.

The President said that the tumor was in the region of the kidney when that organ is displaced, and, in the absence of symptoms referable to the bowel, it was an interesting question what the exact seat of the growth was. *January* 10, 1895.

### 27. *Old hydatid cyst of the liver.*

Exhibited by Dr. W. E. Hughes.

Negro, aged 30 years. He had a family history of phthisis, and had, himself, apical phthisis which was breaking down, but he was not much emaciated. He was going about the hospital when suddenly, and without warning, he was attacked with extreme dyspnœa, with weak heart-action, and cyanosis, without any lung signs. He died in forty-five minutes.

*Post-mortem.* The left lung was universally adherent, with spots of cheesy pneumonia in the upper lobe; and the same, less marked, was present in the right lung, with a subacute pleuritis. There was one spot against the pericardium, two inches in diameter, of extremely acute inflammation. Just here the phrenic and vagus nerves would be caught. The heart-muscle looked healthy, with a suspicion of myocarditis on the right side, which was somewhat distended. The inflammation of the nerves was the only cause of heart-failure evident. There were no pulmonary thrombi. In the intestines there were typical ulcers which had never given rise to any symptoms. In the lower part of the right lobe of the liver was a hydatid cyst about an inch and a half in diameter. The wall was rumpled and there were septa inside, and the contents the usual gelatinous material.

Dr. Abbott asked as to the relative frequency in whites and negroes. He had found more in negroes in Baltimore.

The President said he had claimed in a recent article that hydatid disease is growing more frequent. He said he had seen more cases recently than he did formerly when he saw more autopsies.

*January* 10, 1895.

---

### 28. *Diminutive liver from an infant.*

Exhibited by Dr. Augustus A. Eshner.

The liver that I have the pleasure of presenting has been placed in my hands by Dr. R. E. Müller, of this city, who has also kindly furnished me with such clinical and pathological data as were attainable. The specimen came from a male infant, delivered at term with forceps after a labor lasting forty-eight hours, and weighing 7 pounds 1 ounce

at birth. The mother was a German, thirty-two years old, with a justo-minor pelvis, who had led a dissolute life for many years, but denied that she had ever previously been pregnant. She had been in the habit of lacing tightly, even during the pregnancy. There was no history of syphilis or tuberculosis. For the first two days of life the infant was fed on sugar water, as the mother was unwilling to put it to breast on account of the nipples being sore. On the third day the child was given the breast, but it refused to nurse. It was then fed with sterilized cow's milk sweetened with milk-sugar. Forty-eight hours after birth the face and chest of the child were observed to be icteric, and soon afterward the conjunctivæ and the extremities also. An effort was made to collect the urine for study, but without success. The stools had a greenish color on the second day. The child wasted rapidly and died on the eighth day of life. The umbilical cord had been carefully ligated, but the ligature had not fallen off.

At the post-mortem examination it is said that no abnormality was found, save the general icteric discoloration of the tissues and the diminutive size of the liver. The ductus venosus was patulous. The dimensions and weight of the liver were not noted at the time of its removal, but, after having been preserved in alcohol for some time, the transverse diameter was found to be three and a half inches, the antero-posterior diameter two and three-quarters inches, and the vertical diameter one and three-eighths inches; the weight was two and one-quarter ounces.

The specimen appears to be an unusual and unique one. I have been unable to find reference to a parallel observation. In conformation, in fissuration and lobulation, and in histologic structure, it presents the appearances of a normal viscus, its only peculiarity, so far as I can discern, consisting in its striking diminutiveness.

Malformations of the liver are said to be on the whole rather uncommon. Ziegler states that the liver may be entirely absent, though rarely. Although the liver progressively increases in size from the period of its first appearance in the process of development, its relative size, as compared with the weight of the body, begins early to gradually and progressively diminish. Thus, in the first month of fœtal life the weight of the liver represents one-half of the entire weight of the body, at birth the ratio is 1 : 18 or 20, and in adult life 1 : 36 to 40. In the specimen presented this ratio is 1 : 50. I have been unable to obtain any definite figures as to the dimensions of the liver at the various periods of development. At birth the organ is said to extend almost to the level of the umbilicus. The average figures for the adult liver

are given as 11 inches for the transverse diameter, 7 inches for the antero-posterior diameter, and 2.5 inches for the vertical diameter. The weight of the adult liver varies from 50 to 60 ounces.

In the specimen exhibited the right lobe is the larger, as it should be normally at birth and thereafter. Until the fourth month of fœtal life the two lobes are about of equal size, but after this the left is the smaller. The comparatively large size of the fœtal liver is due to the large quantity of blood sent through the organ by way of the umbilical vein.

I am at a loss for an explanation of the abnormality in the size of the organ shown. I am scarcely willing to make the tight lacing an active factor. *January* 10, 1895.

---

29. *Gastric cancer with perforation, and death from hemorrhage.*

Exhibited by Dr. Frederick A. Packard.

The patient from whom this specimen was removed was seen with his physician about two hours before his death. He had been suffering for two years with marked dyspepsia, and for several months had been losing flesh and vomiting at long intervals after eating. When I saw him he was in collapse, with cold, clammy extremities, pinched features, and marked pallor of the mucous membranes. Beside his bed was a basin containing a full quart of grumous, dark material, that had been vomited a few minutes before our arrival. He was almost pulseless at the wrist, and the abdomen was distended and tympanitic with complete absence of liver-dulness. His chief complaint was of intense thirst. A diagnosis of pyloric cancer with rupture was made. Some of the vomited fluid was taken for examination, and showed many red blood-cells, starch granules, and torula cells, with Teichmann's hæmin crystals. Upon heating with glacial acetic acid some of the dried vomitus mixed with sodium chloride.

Two hours after our visit the man died. At autopsy there was found marked injection of the whole peritoneum, with the serous coat of the intestines dry, lustreless, and thinly coated with sticky lymph. On the anterior surface of the stomach about one inch from the pyloric ring there is a perforation 0.75 cm. in diameter, clear cut, and freely patulous. On opening the stomach the viscus was found to be greatly dilated, and containing fully a quart of material similar to that vomited a short time before death. The point of rupture previously mentioned was situated in the centre of a small crater-like ulcer with indurated

edges. The sections of the edges of the ulcer show typical structure of epithelioma. The gall-bladder contained a small quantity of glairy yellowish mucus and about twenty faceted white gall-stones, which were found to consist almost entirely of cholate of lime without any cholesterin.

From the amount of blood vomited just before death with that found in the stomach at autopsy, it is a question whether the rapid loss of blood was not the immediate cause of death rather than the perforation into the peritoneal cavity. *January* 24, 1895.

---

30. *Primary carcinoma of the gall-bladder.*

Exhibited by Dr. A. O. J. Kelley.

F. J. F., aged 67 years, female, married, the mother of four children. No specific history of any kind during early life. When a young woman she had repeated attacks of abdominal pain, never followed by jaundice; pain was always sharp and agonizing. In later life these attacks became less frequent, and she had had none the last ten years of her life. In 1892 had diphtheria, followed by paralysis more or less general; entire recovery. In 1893 dysentery for four weeks. Since that time pain in the right lumbar region, accompanied by frequent and painful micturition. Pain on micturition was almost constant, but was more annoying than severe. There was no loss of flesh, and never any jaundice. About Christmas, 1894, the pain in the lumbar region increased; since then continually confined to bed. Gradually the abdomen began to distend. Four weeks before death a mass could be felt very distinctly on the right side below the edge of the ribs. This mass was thought to be the edge of the liver, and was not present (at least very careful examination failed to reveal it) before. Ascites developed. Suddenly, on January 27th, collapse occurred, and she died of general peritonitis.

The autopsy was performed about twelve hours after death. The body was that of a well-developed, well-nourished woman, apparently about five feet three or four inches in height. Panniculus adiposus quite marked. Rigor mortis present. Abdomen very much distended. Upon incising the peritoneum a rather cloudy straw-colored liquid and shreds of lymph escaped. In all this fluid amounted to about seven or eight quarts. Lungs normal, heart normal. The liquid having been drained from the abdominal cavity, all that was visible as far down as

the level of the iliac spines was the large omentum, thick and nodular (as you see); the parietal peritoneum, especially that lining the under surface of the diaphragm, was white, thick, and here and there nodular. Lifting the omentum the intestines were found slightly distended, congested, and bound together by delicate shreds of lymph, readily broken up. Spleen normal, kidneys normal, uterus and adnexa normal. The liver, gall-bladder, pancreas, stomach, duodenum, large intestine (transverse colon), were all so firmly united that it was with extreme difficulty they could be dissected. However, the stomach was found normal, the duodenum normal, the transverse colon normal, the pancreas normal. After having been dissected loose from surrounding tissues the gall-bladder was found to be whitish-gray, apparently of about its normal size, or somewhat diminished. Upon incising it its walls were found to be a finger thick, while the interior was much diminished in size, contained a small amount of pus, and the gall-stones, eleven in all, which I herewith present. These stones did not all lie side by side in a common cavity, but two of the larger ones were more or less confined in pockets of their own, while the largest of them all occupied that portion of the bladder nearest the cystic duct. The liver, except that portion in connection with the gall-bladder, was normal.

Here is a case, then, evidently of primary carcinoma of the gall-bladder, and as such is interesting for many reasons, not alone pathologically, but clinically. Clinically, I think it especially interesting. Of the most frequent symptoms and signs of carcinoma of the gall-bladder, pain, jaundice, emaciation, cachexia, and the presence of a tumor, she presented the single one of pain, and that in the right lumbar region, and, toward the end of her life, a tumor. Of course, one cannot suppose that the tumor grew to the size which it ultimately reached in a few weeks; but certain it is that four weeks prior to the patient's death most careful examination failed to reveal the presence of any tumor. Cachexia, emaciation, and jaundice, she had none. The absence of jaundice is readily explained by the anatomical findings, the tumor being non-metastatic in the liver, and affecting the liver simply by continuity of structure, and occluding only the cystic duct, the occlusion being by a gall-stone. The rules and methods laid down for our guidance in matters of diagnosis are, in most cases, most explicit; but we must often confess our inability to make more than a general diagnosis, as in this case, of abdominal tumor with some connection with the liver; certainly a positive diagnosis passed beyond the realm of human diagnostic acumen.

Most interesting is the question of the etiology. In these days of bacilli one hesitates, but acknowledges the relation—the causative

relation—which gall-stones bear to carcinoma of the gall-bladder. In the classis which our worthy President, Dr. Musser, read before the Association of American Physicians, he reports a hundred cases of carcinoma of the gall-bladder in which gall-stones were rated as present sixty-nine times. Courvoisier reports them present seventy-four times out of eighty-four. Brodwoski found them present in all of forty cases which he examined. And the assertion that they are overlooked is probably well founded. To quote from Dr. Musser: "Gall-stones are found in cancer of the gall-bladder. The clinical history and the anatomical appearances appear to show that they formed prior to the formation of the cancer. Cancer occurs without gall-stones, and, *vice versa*, gall-stones occur without cancer. The frequent association of calculi and carcinoma, and the undoubted fact of their formation prior to the morbid growth, warrant the belief that their presence is as much a causal factor as are irritants in other situations, *e. g.*, in the lip, etc." Can we speak of predisposition, and say in a person predisposed to carcinoma the gall-stones act as the exciting cause? Or, again, will the bacteria help us; some form the gall-stones, others be instrumental in the production of the malignant new growth? Certainly an interesting question.

The microscopical section which I have prepared will illustrate the disease-process in various places.

In conclusion, I must express to Dr. Fussell my great indebtedness for the history of the case and the specimen. *February* 14, 1895.

---

31. *Carcinoma of the stomach.*

Exhibited by Dr. W. E. Hughes.

The most prominent clinical symptom was ascites, and the man had been a hard drinker. The trouble began like a chronic gastritis of alcoholic origin, and he never had vomiting like that of a dilated and cancerous stomach. He had pain all over right side, was icteroid in color, and, late in the case, developed the marked ascites. Physical examination revealed nothing of importance.

*Post mortem.* The lungs and heart were found healthy, though the latter was very small. The primary growth was near the pylorus, and looked like an ordinary encephaloid encircling the pylorus. There was a large ulcerated surface posteriorly. The growth probably pressed on

the common bile-duct, but not sufficiently to occlude it, and there was also pressure on the portal vein. The mesentery and peritoneum were secondarily involved.

The President spoke of the interest in connection with the clinical diagnosis, as gastric carcinoma is not infrequently confounded with cirrhosis of the liver. *February* 28, 1895.

---

32. *Calcareous excretion from the tonsil.*

Exhibited by Dr. Riesman.

The specimen was given to me for presentation by Mr. Sellers, a third-year medical student. The history, which he has kindly written for me, is briefly as follows: "The patient, J. B., of Georgetown, Texas, is a farmer, and a thoroughly reliable man in every respect. About a year ago he had severe pain about the ramus of the lower jaw, which after a time passed down to the region of the tonsil (side not given). The throat became very sore, the tonsil and pharynx being so swollen that the man could not speak for two hours. He had a severe coughing spell, during which the stone became dislodged from the tonsil. The drinking-water obtained from a well on the farm is strongly impregnated with lime."

The stone is almond-shaped, pale-brown in color, has a granular surface, and on one side has a deep longitudinal sulcus, giving the calculus the appearance of being folded. It is rather hard and resistant. Its length is 23 mm., the greatest width 14 mm., and the thickness 10 mm.; its weight is 2.03 grammes, or about 31 grains. It effervesces very slightly when treated with hydrochloric acid.

*Remarks.* This stone is one of the largest, although not the largest, reported in literature. Small concretions found in the crypts of the tonsils are comparatively frequent, but large masses are rare. Reid[1] records a case in which the stone was so large that it had to be crushed before removal; the fragments weighed 54 grains. Another large one is that of Buckner,[2] which weighed 33 grains and was 2 inches long.

The composition of the calculi is variable. According to Robin, quoted by Terrillon,[3] the constituents are phosphate of lime, 50; carbonate of

[1] Reid: Austral. Med. Gaz., 1885–6, v. 9. [2] Buckner: Cincin. Lancet-Clinic, 1883, x. 449.
[3] Terrillon: Arch. gén. de méd., 1886, ii. 129.

lime, 12.5; mucus, 12.5; and water, 25. In others, as in that of Baker,[1] oxalate of lime is present with the carbonate; and Meckel[2] speaks of cholesterin calculi. Gruening[3] found leptothrix masses, which, however, play a greater rôle in the small concretions from the crypts than in the large calculi.

The clinical history of cases of this kind is not of interest here. I may say, however, that in nearly all is there an antecedent history of throat trouble. Another point that impressed me as I looked over the literature is that the majority of patients who suffered from tonsillar calculi were past middle life. Of ten cases four were fifty years of age or older; two only were below thirty-eight; seven were males, three females. The origin of these stone formations is obscure. It has been suggested that they are calcified tuberculous masses, analogous to the calcareous tubercles in the lung.

As many of the patients give a history of previous attacks of tonsillitis, usually suppurative in character, it has seemed to me that the concretions might represent cold abscesses, the contents of which had become calcified. Whether the abscess is pneumococcic or staphylococcic in origin, or whether the process is a caseous necrosis of tuberculous nature, matters not. For some reason an attack of apparent quinsy subsides, the abscess contents become inspissated, and in time are infiltrated with lime-salts and converted into stones.

An acute attack of tonsillitis, perhaps excited by the presence of the calculus, causes suppuration of the enclosing tonsillar structure and the spontaneous liberation of the stone, or renders it palpable, so that it can be extracted.

Dr. Scott remarked that some of these stones in the tonsils are probably urates such as Dr. Allyn found in the pharynx. These occurred in gouty persons.

Dr. Riesman said some cases are recorded of smaller stones which were probably urates. *February* 28, 1895.

[1] Baker: Trans. Lond. Path. Soc., 1859–60; Lond. Lancet, 1860, i. 296.
[2] Meckel: Quoted by Terrillon, *v. supra.*
[3] Gruening: Burnett's System of Dis. of the Ear, Nose, and Throat. Phila., 1893, ii. 599.

33. *Primary carcinoma of the head of the pancreas with hour-glass contraction of the stomach, simulating during life pyloric stenosis.*

Exhibited by Dr. D. J. Milton Miller.

The patient, a single woman, a domestic, aged 53 years, first came under observation in the wards of the Episcopal Hospital, in February, 1894. At that time she gave a history of three months' illness, the principal symptoms of which were epigastric pain and occasional vomiting; the latter usually affording relief, and consisting of mucus and undigested food, and once of bright-red blood. The outlines of the stomach were apparently normal, and deep pressure in the epigastrium elicited pain, but there was no tumor. Günzburg's test revealed the presence of free HCl, but not in excessive amount, *i. e.*, the reaction, though well defined, was not intensely so. She has always been an excessive eater and a large drinker of tea, but never of alcohol. There was no family history of note. Under rest and a diet of peptonized milk she rapidly improved, and within three months was discharged, a diagnosis of chronic catarrhal gastritis having been made.

On November 3, 1894, she was readmitted into the Episcopal Hospital. It was then noted that she had lost considerable flesh and was quite anæmic. She reported marked increase in, and almost constant, pain and frequent vomiting—on several occasions of pure blood, or the so-called "coffee-grounds" material. There was no tumor discernible. The outlines of the stomach, as defined by auscultatory percussion, appeared to be normal, and remained so throughout the whole history of the case. Examination of the gastric contents after Ewald's test-meal gave a faint reaction with Günzburg's solution. The contents had a strongly acid odor, reacting promptly to blue litmus-paper. By the latter part of December a small, immovable, ill-defined, and very tender tumor could be felt in the epigastrium, two inches below the ensiform cartilage. Shortly after admission peptonized milk in small quantities was ordered, and daily lavage was practised. To effect this a large amount of water was used, and it was noticed that, although the washings were done in the morning, they contained quantities of food given the day before. This occurred even when no food or milk had been taken for twelve or fourteen hours. About the 20th of January, 1895, a light jaundice was noted. This grew more intense, and was accompanied by an increase in the hepatic dimensions and by the

development of an oval, elastic, and semi-fluctuating tumor at the tip of the ninth right rib; this was thought to be the gall-bladder.

Several examinations during the course of the disease failed to give constant evidence of the presence of free HCl. This was probably due, as the sequel will show, to the failure to thoroughly wash out the stomach on the night previous to the administration of the test-breakfast—a precaution that should never be omitted, if we desire correct results in chemical examination of the gastric contents. The salol-test for the motor function of the stomach was also employed, but with unsatisfactory results.

During the latter third of the patient's life the stools were frequently, but unsuccessfully, examined for evidences of fat. A microscopic examination, however, was not made. The urine, though tested on several occasions, contained neither sugar nor albumin.

By February 25th the epigastric tumor was more defined, and still very painful and immovable. Otherwise the patient's condition continued about the same. Sometimes vomiting daily for a period, and then a week or ten days elapsing with entire freedom from this symptom. Pure blood was never vomited while under observation, though the so-called "coffee-grounds" matter was ejected on several occasions. At this time Dr. D. D. Stewart kindly saw the case and consented to undertake an examination of the gastric contents with the view of determining the absence or presence of lactic acid. In order to eliminate all sources of error, the organ, at Dr. Stewart's suggestion, was thoroughly cleansed prior to the administration of Boas's flour soup. In doing this forty-eight quarts of water were used. In the withdrawn contents Dr. Stewart found a total acidity of 88; 0.05 of free HCl; sharp reaction with Günzburg's test, and no lactic acid. In the light of this examination a probable diagnosis of cicatricial stenosis from old ulcers was made.

From the 25th to the 28th of February the patient was fed exclusively on meat broths, meat being entirely withheld; on the latter date the stomach was again thoroughly washed out with a solution of soda (sod. bicarb., ℥ss; water, Oij). It took but eight quarts on this occasion to cleanse the organ. The flour soup was then introduced through, and before removing, the tube, allowed to remain in the stomach over night, and withdrawn the next morning by aspiration.[1] Dr. Stewart's examination of this was as follows: Contents received, 360 c.c.; strong odor of salol (given six days previously); total acidity, 70; sharp

[1] These manipulations were carried on under Dr. Stewart's directions.

Günzburg; free HCl, 0.175; combined and free HCl (Leo's method), 0.02225; no lactic acid; egg disk completely dissolved in three and a half hours.

On the 7th of March tympanites developed, and there were signs of commencing cardiac failure. Various measures were employed to relieve the abdominal distention, but with indifferent success. The patient gradually grew weaker and died March 13th. It should be added that no enlargement of the supra-clavicular and inguinal glands was at any time present, and that the temperature ranged between 98° and 99.5° F., occasionally reaching 100° F.

*Autopsy.* Body emaciated. Skin and mucous membranes deeply tinged with bile. Pleuræ adherent at various points. Lungs pale, except at posterior bases, where there is hypostatic congestion. Slight amount of fluid in pericardium. Heart small, muscle pale, valves normal. Stomach and intestines strongly distended with gas. Stomach occupies an almost vertical position, the whole of the organ lying to the left of the median line, the lowest extremity on a level with the umbilicus. The pylorus is at a point midway between the ensiform cartilage and the umbilicus. On a line with the pylorus and involving the whole circumference of the stomach is a constricting band, which divides the organ into two parts; the lower, consisting of one-third of the stomach, is thus separated from the body of the viscus by a rather narrow opening. The diameter of the stomach is lessened about one-half at this point. The portion above the constriction is of about normal capacity, while that below seems dilated. (Owing to rupture of the walls before the removal of the stomach, the exact capacity could not be tested, but the restricted portion evidently held about sixteen fluid-ounces, the rest of the organ about two pints.) The mucous membrane is softened (post-mortem) and in a state of catarrhal gastritis; but there is no evidence of cicatrization at the site of the constriction or elsewhere. The pyloric orifice is little, if at all, narrowed, as it admits the forefinger with ease. The head of the pancreas is the seat of a hard tumor, about the size of a hen's egg, which completely surrounds and occludes the pancreatic and common bile-ducts. As a result the body of the pancreas is enlarged and softened, its duct dilated and filled with retained secretion. Behind the obstructed portion the common duct is dilated and filled with dark bile. The cystic and hepatic ducts are also dilated, while the gall-bladder is enlarged and distended with fluid bile. The liver is enlarged, bile-tinged, the ramification of the hepatic duct filled with dark-greenish fluid. There are no secondary growths. The condition of the other organs is unnoteworthy. Dr.

McFarland, pathologist to the Episcopal Hospital, examined the pancreatic growth, and reported it to be carcinoma.

This case presents many points of interest. In the first place, it emphasizes the value and necessity of the modern methods of research in the diagnosis of obscure affections of the stomach and pyloric zone. The clinical history above narrated certainly warranted the diagnosis of malignant stenosis of the pylorus, with secondary involvement of the liver, or, at least, of the glands in the hepatic fissure; but the constant presence of free HCl (although by our imperfect methods this was often absent), and above all the absence of lactic acid, enabled us to exclude gastric cancer, and led us to attribute the symptoms to a cicatricial stenosis of the pylorus, hypertrophic in character, occluding the common duct, with a possibly concomitant carcinoma of the pancreatic head. The autopsy showed the latter surmise to be true. There was no stenosis, but a remarkable constriction of the whole circumference of the stomach, forming the diverticulum above mentioned, and accounting for the signs of dilatation during life, and the difficulty in washing out the organ, the food collecting in the constricted portion. It explained, also, why auscultatory percussion failed to reveal the true dimensions of the organ, the stomach-note being lost as soon as the space separating the two portions came under the percussing finger. The contraction was evidently congenital, as there was not the slightest evidence at the autopsy of cicatrices at the site of the constriction. Contractions of the stomach seem to be rather rare anomalies, as the few works we have referred to make little or no mention of them. This seems to be an instance of exaggeration of the antrum pylori (the lower quarter lying in front of the pylorus), which Ewald[1] mentions as causing the stomach, without the action of cicatricial contraction, to assume the shape of an hour-glass. Another interesting feature is the confirmatory evidence which our case gives of Boas's and D. D. Stewart's[2] work on the value of the presence of lactic acid as a sign of carcinoma of the stomach. The gastric catarrh was evidently sympathetic in character, and the weakening and dilatation of the constricted portion sequential to this. Until the onset of the pancreatic disease the diverticulum must have been able to empty itself, as there were no symptoms before that time. With the appearance of the carcinoma, however, and the consequent gastritis, the motor power of the stomach was impaired, and signs of dilatation became evident.

[1] Diseases of the Stomach, English Translation, p. 111. New York, 1892.
[2] Medical News, February 16, 1895.

As to the pancreas, a comparatively uncommon condition is presented in the limitation of the malignant growth to the gland alone. In only 12 out of 127 cases of pancreatic cancer collected by Segre[1] was the disease confined to that organ. It is quite possible that the pancreatic disease might have been detected with more certainty during life, had closer attention been paid to the presence of fat in the stools and glycosuria; but owing to the prominence and interesting features of the gastric symptoms, the stools were not examined microscopically, and the urine was tested but a few times. *May* 9, 1895.

---

34. *Specimens from a case of intermittent fever of hepatic origin, aortic obstruction, and chronic interstitial nephritis.*

Exhibited by Dr. Frederick A. Packard.

The man from whom these specimens were taken was a patient in the Philadelphia Hospital for two years continuously. He was 80 years of age, a native of Philadelphia, and with the exception of a period of two years, when he worked at gold-mining in California, has always worked as a clerk.

His father died at the age of 84 years. His mother died at 50 years, the cause of death being unascertainable. One sister died of consumption; two brothers of "bilious fever."

He had led a fairly regular life, but used alcohol at times to excess. He has been an inordinate user of tobacco. He never worked in lead. Forty years ago he had an attack of gonorrhœa, but he denied syphilis. He had no previous illness save for an attack of "bilious fever" during childhood. The nature of this illness could not be determined, as he could give no account of his symptoms. No later history of rheumatism, malaria, or any disturbance of the liver.

In 1890 he came into the "out-wards" on account of his being too old to work. His chief trouble at that time was the occurrence of attacks of vertigo, which were induced by stooping and by exertion. These symptoms steadily increased, and dyspnœa with œdema of the ankles made their appearance, so that in October, 1892, he was admitted to the wards of the hospital.

The records state that on admission to the wards he was very weak, had an irregular and feeble heart and a mitral regurgitant murmur.

[1] Osler: Practice of Medicine, p. 461.

He apparently improved under treatment, and showed no symptoms of interest until July 19, 1894, when the notes state that he was seized with a sharp attack of pain in the right side, requiring the administration of morphine. On the next day he had a repetition of the pain with tenderness on the right side, and had a chill followed by a rise of temperature to $101\frac{2}{5}°$. On July 21st the temperature-chart shows a sudden rise of temperature to 103°, and on the chart there is noted the recurrence of a chill on that day. As there is no note aside from that on the temperature-chart, it is impossible to say whether there was recurrence of the pain. The chart shows marked intermission of the temperature on the three days next succeeding. No mention is made as to the presence or absence of pain or of jaundice, nor is the character of the stools mentioned, nor any examination thereof.

The temperature is very irregular, with sudden elevations up to $102\frac{4}{5}°$ or thereabouts, until August 1st, after which it remained normal until October 1st, at which time he first came under my care.

On examination, aside from the lesions of age (arcus senilis and rigid arteries), he showed nothing abnormal save for the presence of a rather loud systolic murmur at the apex transmitted slightly to the left, with a harsher short systolic murmur heard best at the aortic area and well heard in the carotids.

On October 24th he complained of severe pain in the back and sides, not distinctly localized. This was somewhat relieved by lumbar cupping and by stupes. On October 27th jaundice appeared and the pain was more distinctly referred to the right hypochondrium. The area of liver dulness extended from the upper border of the sixth rib to three fingers' breadth below the costal border in the right midclavicular line. On the 30th there was another accession of pain, and in the afternoon had a stool in which four brown gall-stones of about 0.5 cm. were found on straining through muslin. He then remained free from pain, but still weak and slightly jaundiced, until the night of November 2d, when he had another attack of colic. The bowels were freely moved by sodium phosphate, but no stones were found until November 4th, when two rather larger than those first discovered were found, and there were several fragments. Liver-dulness on this date is noted as extending from the fifth interspace to two fingers' breadth below the costal margin. On the night of the 5th of the month he had a return of colic, and the next day four more stones were found. The temperature during this time was irregularly elevated. He had no chills.

During the winter of 1894–95 he had two or three similar attacks, but in the intervals between them his condition was quite good. Through-

out the winter he gradually lost strength and finally took to his bed for the greater part of each day. In the latter part of April, 1895, he had some return of pain in the right hypochondrium and jaundice reappeared. He lost strength rapidly, the pulse became more and more irregular and feeble, œdema of the lungs appeared, and he died on May 5th. For two days before death he had typical Cheyne-Stokes breathing.

At autopsy the omentum was found bound to the caput coli by a long adhesion, and it was also adherent to the round ligament of the liver. The heart showed dilatation of the tricuspid orifice with slight thickening of the tricuspid leaflets; quite marked dilatation of the pulmonary artery near its origin; fibroid changes at bases of mitral leaflets; adhesion of the aortic valve leaflets with calcareous change; atheroma of the root of the aorta, especially around the orifice of the right coronary artery, and a granular appearance of the myocardium. The lungs were slightly emphysematous and were decidedly œdematous. The mucous membrane of the bronchi was thickened and corrugated, their lumen was irregularly contracted and dilated in places, and their walls were thickened and in places infiltrated with calcareous material. The kidneys showed marked fibroid change, diminution of the cortex, adherent capsules, and very granular surface. The stomach and duodenum were normal save for some dilatation of the veins at the cardiac region of the former. The pancreas showed nothing abnormal except for an increase of fibrous tissue.

The liver weighed 1170 grammes, was small and of granular surface. On the surface of the right lobe there were four indentations marking the course of the large bloodvessels passing toward the surface. The lobules were pale and the fibrous bands that traversed the organ were accompanied by reddish lines, which suggested an increase in the amount of blood in the septa. The hepatic venous trunks were very much dilated. The gall-bladder was small and contained a very slight amount of bile; its walls were much thickened; the portal vein not much dilated; the bile-duct was patulous; the hepatic duct dilated to a circumference of about three inches from the duodenum up to the hepatic notch. Within the substance of the liver the bile-ducts were somewhat but not markedly altered to the naked eye, and there were no purulent foci. The liver was distinctly fibrous.

The brain showed nothing abnormal save for a cyst containing clear fluid, about one inch in diameter, and situated within the centrum ovale of the posterior part of the right hemisphere, at a point corresponding to one inch behind the termination of the horizontal limb of the Sylvian fissure. *May* 23, 1895.

### 35. *Duodenal ulcer.*

Exhibited by Dr. A. O. J. Kelley.

The specimen which I present this evening is from a man aged 32 years, who had, excepting severe pain after eating, apparently the ordinary pain of indigestion and constipation, always enjoyed very fair health. On the evening of February 2, 1895, he ate a quantity of walnut candy, and the following day was suddenly seized with severe pain in the abdomen. The pain was diffuse. He had repeated attacks of paroxysms of severe pain. There was not much swelling of the abdomen until the last attack of pain, which came on about four hours before his death. Shortly after this last attack he passed into a state of profound collapse, and died February 4, 1895, about thirty-six hours after admission to the hospital (St. Agnes's).

The following are the notes of the autopsy, which I performed about thirty-six hours after death: Body was well developed; fairly well-nourished man, about five feet ten inches in height. Rigor mortis present. Quantity of bloody mucus exuding from nostrils; abdomen very much distended. Upon incising the peritoneum a large quantity of gas escapes. The left pleural cavity contains about 250 c.c., and the right pleural cavity about 200 c.c. of bloody serum. There are no adhesions. The lungs are normal, except for very marked hypostatic congestion, especially of the left. The pericardial sac contains about 20 c.c. of clear straw-colored serum. The heart is normal. The peritoneal cavity contains a quantity of dirty-yellowish fluid and numerous particles of partially digested food, seemingly mostly curds of milk, most numerous in the upper part in connection with the diaphragm and below the liver. The intestines are very much congested and distended, and bound together and to the parietal peritoneum by delicate bands of lymph, evidently recent, being readily broken up. They are most dense in the region of the appendix. The appendix itself is normal. The liver is covered with lymph readily removed; the liver itself normal. The gall-bladder is distended; no calculi. The spleen hard, firm, about twice its natural size, and covered with a thick layer of dirty-white lymph, readily scraped away; upon section dark colored, with increase of stroma. The kidneys are normal; upon the anterior surface of the duodenum a slit-like opening 1 cm. in length, 0.3 cm. in width, is seen. The stomach contains about 100 c.c. of dirty-yellowish fluid, some

curds, and remains of partially digested food. The stomach near the fundus presents numerous polypi—polyposis ventriculi—otherwise apparently normal. On the anterior surface of the duodenum just beyond the pylorus is a sharply defined, circumscribed, more or less diamond-shaped defect, extending through the mucosa, submucosa, and muscularis to the serous covering; the inner orifice of the slit-like opening above mentioned is visible; the breadth of this defect on the serosa is about 2½ cm.; the walls surrounding the defect are thickened, elevated, dense, and somewhat overhanging. Brain not examined.

*Pathological Diagnosis.* Duodenal ulcer; perforation; subsequent peritonitis; death. *May* 25, 1895.

---

36. *Fibroid liver and pancreas and obstruction of the common bile-duct.*

Exhibited by Dr. Sedgwick for Dr. W. E. Hughes.

R. R., aged 68 years; white; Irish. Father and mother died of senility. Two brothers died, cause unknown.

*Previous history.* Had measles and smallpox when a child; at ten years of age had enteric fever. Forty years ago had pneumonia. Has been a moderate beer and whiskey drinker for forty years. Lived for ten years in Richmond, Va., but has never had malaria. Forty years ago suffered from hemorrhoids. Denies specific history.

*History of present disease.* For the past two years has suffered with pain on micturition, dyspnœa, and palpitation of the heart, especially upon exertion. Since two weeks has been vomiting some after eating. Three weeks ago first noticed yellowish discoloration of skin and distention of abdomen, which has gradually increased; no history of hæmatemesis, colic, or pain; slight cough with slight expectoration, no hæmoptysis, no itching of skin, appetite poor, bowels constipated.

*Present condition.* Fairly well-nourished; conjunctivæ and skin intensely icteroid, abdomen very much distended, superficial veins prominent, and abdomen is tympanitic throughout; no dulness elicited on change of position, no percussion-wave can be felt. Later the physical signs of ascites could be elicited. On May 19th and 20th vomited matter coffee-ground in appearance. Pulse slow, small, and compressible.

*Heart.* Cardiac impulse diffuse, extending from the second to the fifth interspace, quite forcible, seen and felt most distinctly in the third interspace above the nipple; a mitral systolic murmur best heard over

the apex and well transmitted into the axilla, also a faint aortic systolic murmur transmitted into vessels of neck.

*Lungs.* Chest emphysematous in appearance, tending to barrel shape; depression of supra- and infra-clavicular spaces, lower interspaces very much narrowed, and lower ribs flared out. Vocal fremitus somewhat diminished, feeble respiratory murmur, prolonged expiration; no râles except at inferior portion of right chest in axillary region, friction râles distinctly heard on percussion, chest hyper-resonant throughout.

*Liver.* Below margin of ribs upon deep palpation can be felt a resisting mass, there is slight tenderness, the margin of liver cannot be felt. Area of dulness in mammillary line from third to sixth rib, axillary line from seventh to ninth rib, in median line no dulness can be elicited.

*Post-mortem.* Abdomen contains about two gallons of bile-stained fluid; appendix normal and directed downward into pelvis. The pleural cavities obliterated; both lungs adherent throughout with old and recent adhesions. The pericardium contains about 14 ounces of bile-stained fluid, and very much roughened on parietal surface.

*Heart.* Flabby; cavities on both sides empty; mitral valves admit two fingers with difficulty, and tricuspid three fingers easily. Upon opening mitral valve thickened on margin and contracted; aortic valves are stiff and wrinkled.

*Left lung.* Crepitates throughout and markedly congested; œdematous throughout.

*Right lung.* Same as left, except at apex a cicatrix is found.

*Spleen.* Small; capsule corrugated and thickened throughout with areas of white patches evidently due to increased thickening; on external surface a calcareous plate one-half inch in diameter is seen, pulp dense, and shows increase in interstitial tissue.

*Left kidney.* Hard and small; upon section granular, and cortex diminished in size; capsule stripped with difficulty, and has a rough surface; in cortex opposite to pelvis is a triangular depression probably a cicatrix; there are also a number of cysts.

*Right kidney.* Same as left, except a large cyst at upper end of kidney one inch in diameter.

*Liver.* Small in size, dense, and bile-stained; gall-bladder very much enlarged and distended.

*Pancreas.* Firm, containing a number of hard nodules and small cysts.

*Bladder.* Normal. *May* 23, 1895.

## IV. VASCULAR AND HÆMATOPOIETIC SYSTEMS.

### 1. *Aneurism of the arch of the aorta.*

Exhibited by Dr. A. V. Meigs.

The patient was a mulatto woman, 29 years of age. Her family history was negative, as was her personal history until two years before her death. At that time she had a slight attack of pain in the right shoulder which was soon relieved. Eight weeks before death she had pain in the left shoulder, with cough and husky voice. She could lie only on her right side. Her heart-sounds were normal, her radials large and stiff, and the left pulse less in force than the right. There was no dull area. Beneath the right clavicle there was ill-defined pulsation, and the heart-sounds more marked and with the suspicion of a bruit.

*Post-mortem.* There was found an aneurism springing from the left posterior portion of the arch of the aorta, which had dissected along the arterial wall, narrowing down in front of the aorta behind the clavicle, and finally ruptured. The specimen was shown with the lungs attached.

*September* 14, 1893.

---

### 2. *Specimen of rheumatic pericarditis.*

Exhibited by Dr. F. A. Packard.

The specimen was removed from the body of a white woman, L. W., who died at the Philadelphia Hospital on August 26, 1893.

She gave a history of repeated severe attacks of rheumatism, in one of which she had much præcordial pain. At one time she was in bed for several years with rheumatism. She was admitted to the hospital two days before her death. On admission she was extremely weak and very pallid. There was decided tendency to hemorrhage on pressure upon the gums, and above the left patella there was decided infiltration of the deep tissues. Examination of the blood showed 1,300,000 reds, no excess of leucocytes, hæmoglobin value 22 per cent. She had constant delirium during her last two days. Over the præcordium there

was a loud to-and-fro murmur of great intensity. At the apex systolic retraction of the intercostal tissue was marked, and at the same position there was a loud systolic blowing murmur and a poorly developed presystolic sound. The breath-sounds were obscured by subcrepitant and crepitant râles.

*Post-mortem examination showed:* Body extremely white. Below left breast, on right thigh, and on left arm a number of white, smooth scars, not depressed, and about one inch in diamater. On the left thigh above the patella was a small ecchymotic, purplish spot. Subcutaneous fat in fair amount.

Peritoneum normal. In peritoneal cavity about a half-pint of yellowish serum, in which floated some white flocculi of lymph, and some translucent, transparent, smooth, friable, clot-like masses, resembling mucus. Organs of abdomen in normal position. Vermiform appendix has a complete mesocolon. The pericardium was large and bulging, its parietal layer much thickened. On incision about an ounce of blood-stained fluid spurted out. In the cavity of the pericardium five additional ounces were found. The parietal layer of pericardium measured one-eighth of an inch in thickness, was covered with a uniform layer of adherent fibrin of about a line in thickness and of a blood-stained, yellowish-white color. Over most of the surface, rough, shaggy heaps of fibrin were piled upon the surface, forming readily broken adhesions between this and the visceral layer of membrane. On opening the heart there was no sign of endocardial trouble, but the mitral orifice admitted three fingers. The heart-muscle was very pale, evidently fatty, and much resembling that seen in pernicious anæmia.

Aside from these conditions autopsy revealed intense pulmonary congestion on both sides, slight perisplenitis, fatty liver, right and left lobes of liver separated by a deep sulcus, evidently from tight-lacing; chronic interstitial nephritis, cystic cavities with fibrous walls in its supra-renal capsules, and œdematous appearance of the cerebral meninges.

*September* 14, 1893.

---

### 3. *Aneurism of the aorta.*

Exhibited by Dr. Alfred Hand, Jr.

Case I. *Aneurism of the aorta; death from heart failure.*—B. S., female, aged 37 years, born in Ireland, married, was admitted July 17, 1893. No family history could be obtained, and all the previous per-

sonal history that could be elicited was that four years ago she had had rheumatism, and about six months ago three profuse uterine hemorrhages.

Her present illness dated back six weeks, during three of which she had been in bed. It began with loss of appetite and weakness; then diarrhœa and vomiting set in, with pain in the abdomen; she had coughed some, and expectorated some white mucus. There had been neither nose-bleed nor headache.

When admitted she was evidently in a precarious condition. Her face was cyanotic, the pupils were dilated, breathing was labored, and she had a harsh, dry, brassy cough. She was in somewhat of a stupor, but could be roused easily, and would answer questions intelligently. Her temperature was 101.6°, but at evening it came down to normal. The pulse was a typical water-hammer pulse, the rate being 116 per minute. The apex-beat was in the sixth interspace, outside the nipple-line. At the aortic cartilage there were two murmurs—one systolic, transmitted into the carotids, and one diastolic, heard all over the præcordia. There was a systolic murmur at the apex transmitted toward the axilla, and failing compensation was diagnosticated. The lungs were clear, with the exception of moist râles posteriorly. In the left hypochondriac region there was a large area of dulness extending a little below the costal border, while in the right hypochondriac region the dulness was of such slight extent and situated so far toward the mid-axillary line as to suggest a transposition of the liver and the spleen, but after careful examinations it was seen that the liver-area was much shrunken, while the spleen was enlarged.

Throughout the duration of the case there was albuminuria, with hyaline and granular casts.

The daily notes of the case are as follows:

2d day. The diarrhœa has ceased, but the pain in the abdomen and vomiting continue; temperature from 99° to 100° F.

3d day. The vomiting has yielded to treatment; patient apparently moribund, but can be aroused for a few seconds at a time; respirations 8, pulse 84, temperature from 99° to 99.8° F.

4th day. Condition same as yesterday, but the abdomen is very tympanitic; expression of the face like that often described as typical of peritonitis; respirations 10, pulse 95, temperature 99° to 99.6° F.

5th day. The bowels were moved once during the night; distention of the abdomen is excessive; respirations 10, pulse 128, temperature from 100° to 102° F. In the evening, while watching her closely, it was observed that during the pauses of respiration there could be heard, when standing at the foot of the bed, a to and-fro sound identical with

that heard when a stethoscope was applied over the aortic cartilage. It very much resembled the sound made by a "donkey-engine."

6th day. At 11 A.M. the patient died, with a temperature of 106.8° F.

At the necropsy it was found that the abdominal distention was probably paralytic, as there was neither peritonitis nor obstruction. The liver was contracted, weighing 950 grammes. The lobules were prominent, and the surface was very much like that of a placenta. The spleen weighed 500 grammes. The kidneys were congested. The heart weighed 400 grammes; the valves were not diseased, but the aortic semilunars were rendered incompetent by a dilatation of the orifice due to an aneurism which extended from the origin of the aorta through the transverse arch. The dilatation of the aorta was uniform, and there were no clots; spots of beginning atheroma were numerous. *September* 14, 1893.

---

4. *Double aneurism of the aorta with rupture into the trachea.*

CASE II. C. K., a male, aged 42 years, unmarried, white, born in Ireland, a laborer, was admitted June 20, 1893. His family history was negative. He himself had never been sick. He contracted gonorrhœa and syphilis about sixteen years ago. Last October he began to have sharp pains about the left chest and upon the left side of the face, which were thought to be due to a severe neuralgia. The pains would not be felt while his mind was engaged on his work, but when at rest he would feel them severely. They ceased about four months before admission, and did not trouble him afterward. For three or four weeks before admission he had had a dry cough, laryngeal, and brassy in character, and a feeling as of something sticking in his throat. He had also been spitting blood for a few days, and exertion would make him short of breath. He had noticed at times unilateral sweating on the left side of the face.

Examination showed equal pupils; unequal radial pulses, the right being normal, the left almost imperceptible; veins around the clavicles dilated; heart-sounds normal; in the left carotid a systolic whiff not heard elsewhere. With both acts of respiration a wheezing sound could be heard at a distance of several feet. Examination of the chest was negative, except that there was dulness over an area with a radius of from an inch to an inch and a half from the left sterno-clavicular articulation. From this, the diagnosis was made of an aneurism of the transverse arch of the aorta, involving the origins of the left common carotid and subclavian, and pressing back on the trachea.

For three weeks the man remained apparently in about the same condition, occasionally spitting a little blood. The fatal hemorrhage came one morning as he was sitting quietly in a chair, after having risen and dressed himself.

The *autopsy* revealed a large aneurism of the transverse arch of the aorta, equal in size to the heart, beginning just at the origin of the innominate and extending to the descending aorta. It was filled anteriorly with a large lamellated clot, which was softer posteriorly, where there was a channel for the blood-current. The aneurism pressed posteriorly against the trachea, into which it had ruptured through a small opening about an eighth of an inch in diameter and an inch and a half above the bifurcation. On the thoracic aorta, just below the descending arch, there was a sacculated aneurism two and a half inches long and one inch deep, projecting backward. It was lined on the inside with calcareous plates and contained a small clot. The lungs were almost filled with blood, which had flowed down the air-passages, and a large clot occupied the trachea. There were no valvular lesions of the heart.

*September* 14, 1893.

---

### 5. *Pernicious anæmia.*

Exhibited by Dr. W. E. Hughes.

The patient was a woman, aged 80 years, who had great anæmia and exhaustion. There were no signs of cardiac disease. The veins were almost devoid of blood. The red blood-corpuscles numbered 1,080,000, and the hæmoglobin was but 35 per cent. or less. The urine was pale. The patient died of exhaustion.

*Post-mortem.* The lungs were universally adherent; at the base of the left lung there was a series of decomposed infarcts, the source of which could not be found. The heart showed an old endocarditis and a buttonhole in the mitral valve One kidney was parenchymatous and showed infarcts; the other kidney was atrophying. The stomach showed atrophy of the mucous membrane, which was very smooth. The intestines were normal. The lymph-glands were enlarged and the bone-marrow fluid. The exceptionally marked external anæmia, however, indicated pernicious anæmia. The brain showed some old hemorrhages.

Dr. Scott asked as to the color of the urine in pernicious anæmia. He had seen it of a cherry-red color. He had made about fifty examinations of liver, kidneys, and spleen in various diseases with the ferrocyanide of potash method. In all cases of pernicious anæmia he found

pigment in great excess near the periphery of the liver lobules. In no other case did he see this condition.

Dr. Hughes said he thought the infarcts in this case were not those of heart disease, but undoubtedly septic, as none were larger than a pea. He had never found red urine in pernicious anæmia.

*October* 12, 1893.

---

### 6. *Endocarditis.*

Exhibited by Dr. G. E. Curry.

Patient was an Italian, aged 34 years, and had been in this country but little more than two weeks. He was admitted to the hospital late in the evening, gasping for breath and coughing up dark-colored blood. The following afternoon he died, so, clinically, little is known of the case. It was noticed when he came in that there were more or less general anasarca and considerable jaundice. On questioning, patient said he had been sick since October 1, 1893, was taken worse fifteen days before being brought to hospital, and for three days previous had been coughing up dark blood. No history as regards family, previous illness, or habits could be obtained. Urine contained bile, but no albumin or casts. Area of cardiac dulness was considerably enlarged, and on auscultation loud murmurs were heard. Post-mortem revealed 24 ounces of a bile-stained serum in peritoneal cavity, and in right pleural cavity about 28 ounces of a similar fluid, and a small amount also in left pleural cavity. On left side were some old pleural adhesions and also some deposits of recent lymph. Pericardial fluid amounted to 5 ounces. Over right side of heart and particularly over right auricle were deposits of old lymph, and in some places this much resembled small tubercles. The mitral and aortic valves were calcareous, very much thickened and contracted. The tricuspid valves showed some thickening, and on this and the pulmonary valves were recent deposits of lymph, particularly seen at the line of contact when valves closed. Aorta was atheromatous and also the coronary arteries. The heart was both hypertrophied and dilated.

In both lungs were found numerous hemorrhagic infarcts and carnified areas, but no tuberculosis. All the organs were cirrhosed, and in addition the left kidney contained on surface a small cyst. The liver, besides being cirrhotic, presented two or three calcareous areas, the largest one being about one-half inch in diameter on surface of organ.

*November* 23, 1893.

### 7. *Pericarditis with effusion.*

Exhibited by Dr. STEELE.

Theo. B., Lapland; rag-picker; aged 53 years; admitted January 12, 1889, to the Insane Department of the Philadelphia Hospital with a diagnosis of chronic dementia. His mental condition showed nothing of special interest.

The record of his history is uneventful until January 1, 1893. But as he had been taking digitalis, I think he probably had cardiac symptoms that were not recorded. During the year preceding his death he had frequent sudden attacks of pain in the epigastric region, with tympanites and borborygmus, and with belchings of an extremely foul-smelling gas. These attacks quickly passed. Hoffmann's anodyne was given and seemed to afford relief.

Examination had shown absence of the knee-jerk and the presence of the Argyll-Robertson pupil, and these attacks were thought to be gastric crises.

The patient also exhibited moderate œdema of the feet, legs, and hands during this period. This had almost disappeared a month before death, but was still present in a slight degree upon the right side of his chest, probably due to his constant right lateral decubitus.

No albumin was found in the urine by the ordinary tests, but there were a few granular casts.

In September, 1893, the patient experienced an attack of acute right-sided pleuritis with effusion. This effusion disappeared promptly under absorbent treatment, and October 7th found him convalescent.

October 20th he was again put to bed, complaining of a slight cough and some pain in the right chest. There was no temperature above the normal.

On the evening of November 13th the patient was found in a state of collapse. His temperature was 94°. No pulse was discoverable at the radials, and his extremities were cold.

He rallied under stimulating treatment, and a slight febrile movement commenced, of which the maximum temperature was 100° in the axilla, and was reached November 20th (six days later). By November 22d it was again at normal.

The pulse and respiration kept pace with the fever, and the respirations at no time exceeded 30 to the minute. There was some pain in the chest with some muco-purulent expectoration.

On November 15th the patient vomited twice, the ejecta in each instance consisting of a moderate amount of clear fluid containing "coffee-ground" material, which the microscope showed to be altered blood.

About the time the fever reached its highest point the patient was observed to be jaundiced, and a few hemorrhagic spots appeared upon the skin of his abdomen. The jaundice, which was moderate in degree, began to disappear in three days after it was first noticed, and was soon gone. No more hemorrhagic spots appeared.

The patient's bowels were constipated, and when stools were obtained by enemata they were sometimes blood-stained. However, there were no complaints pointing to disease in the rectum.

One week later (November 27th) the patient began to develop marked dyspnœa, his cough was suppressed, and another slight and irregular febrile movement commenced, which lasted until death. The temperature ranged from 98.4° to 99.4° in the axilla—falling to 97.2° just before death.

Now physical examination showed presence of fluid in the right pleural cavity, reaching as high as the second rib. Small moist râles could be heard above this effusion.

The left side of the chest showed diminished movement, impaired resonance, and some dry râles. The area of cardiac dulness was somewhat increased, its upper bruit being at the second interspace and its outer at the mid-clavicular line. The right edge blended with the flatness of the right side. The apex-beat could be neither seen nor felt. The sounds were faint and the action of the heart was feeble and arhythmical; no murmurs were detected. The second sound was somewhat accentuated.

The dyspnœa increased, and the patient had frequent attacks of orthopnœa, which became more frequent and severe, until death occurred December 8th.

The man's mental condition rendered any physical examination very unsatisfactory.

In view of the epigastric pain and nausea, together with very deceptive contractions of the recti muscles, which made it difficult to determine whether or not a tumor was present, the physician in charge rather expected to find some malignant disease of the stomach, which diagnosis the altered blood in the vomit seemed to support.

*Autopsy Notes.* The body of a well-nourished man. Rigor mortis very slight. There is an abundance of subcutaneous fat which is normal in appearance.

*Abdominal cavity* is normal in appearance, except slight adhesions existing between the under surface of the liver and gall-bladder and the intestine.

The *right pleura* shows old, firm, and fibroid adhesions at the apex anteriorly and base posteriorly. It contains 24 ounces of fluid. The *left pleura*—adhesions at apex posteriorly—contains 30 ounces of fluid.

The *pericardium*. Surface is covered with a recent inflammatory exudate; there are comparatively recent adhesions at the apex; the exudate is dendritic in character. The pericardial sac contained 50 ounces of dark blood-stained fluid, which was opaque. The surface of the heart contained a fibrous layer of an old inflammation, and beneath this a thick layer of fat. The *heart* had recent adhesions at the apex with old ones at the base, to which last recent ones are suspended. The valves of the heart appear normal.

The *right lung* contained disseminated through its whole extent minute solid bodies, varying from one-eighth inch in diameter to almost imperceptible specks. Some of these are apparently pigmented. The lungs crepitate at all points.

The weight of the thoracic viscera was 5 pounds 8 ounces.

*Left kidney* is very fatty and showed a moderate degree of parenchymatous inflammation; weight 7 ounces. *Right kidney* shows a similar condition, which, however, is less marked; weight 8 ounces.

*Suprarenal bodies* normal. Bladder small and thickened. Ureters normal.

*Liver*, on section, showed some interstitial changes, giving it the nutmeg appearance; especially marked in the right lobe. The bloodvessels are markedly dilated; weight 51 ounces. The gall-bladder appeared somewhat distended and projected for an inch beyond the edge of the liver; the bile was thick and ropy; the duct was patulous; the duodenum and twenty inches of the ileum show minute swelling and ulceration of the solitary gland. At some places there are hemorrhagic points in the mucous membrane.

*Stomach* normal. *Pancreas* normal.

*Rectum*. There is a pigmented polyp, with a pedicle two inches long, four inches from the anus; it is ulcerated over one-half of its surface; it is two inches long and one and a half inches in diameter.

*Brain* shows œdema superficially. The convolutions are flattened and the gray matter is very thin.

*Spinal cord* not examined.

The etiology of the pericarditis seemed to me to be rather obscure. Dr. Musser reports a case of effusion which surpasses this in amount of

fluid which shows its tubercular nature by chills and temperature, and that it may have been cancerous is supported by the character of the effusion, and it will be interesting to learn the result of the examination of the tumor in the rectum and of the bodies in the lung. I would be very grateful if any of the members can give me results of their experience in similar cases.

Dr. Cattell believed there were tubercles present in the specimen.

Dr. Coplin said, in regard to tuberculosis, that he had notes of several cases of miliary carcinomatosis and miliary sarcomatosis. Miliary tuberculosis is rare in localized cases, while secondary malignant growths more commonly have localized miliary deposits. He thought the appearance of the rectal polyp was malignant.

The President considered further investigation necessary in the case.

Dr. Davis did not think a distinctly pedunculated tumor would give rise to general dissemination. *December* 14, 1893.

---

### 8. *Thrombosis of femoral artery.*

Exhibited by Dr. F. Savory Pearce.

Through the kindness of Dr. Musser I present this specimen from the following case: A. B., aged 70 years, admitted to the University Hospital October 19, 1893, on account of spasm of the œsophagus. Three days prior to admission the patient was seized with spasm of the œsophagus which prevented the administration of food. On examination pharyngeal inflammation was present, but no other evidence of local disease existed. It was impossible to pass an œsophageal tube on evening of admission. The next day the patient began to take nourishment—whiskey, milk, and small amounts of ice cream. On the third day after admission (October 22d) he was seized with pain in the right leg at the calf. This was followed by a dead leg; that member becomng pale and cold. After the occurrence of the pain, which became increasingly more severe and cramp-like, collapse took place, and he died a few hours after the onset of the pain in the leg. There was no fever throughout this rapidly fatal condition.

*Autopsy.* Body rather emaciated. No pathological condition evident externally.

*Brain.* Membranes presented a slight opacity, but were otherwise normal. Convolutions were slightly atrophied, but not more than age of the patient would account for. Cerebral lobes showed no pathological change. Cerebellum normal. On laying open the fourth ventricle the floor showed several minute hemorrhages, probably ante-mortem.

*Spinal cord.* Not examined.

*Lungs* were in all respects normal.

*Pericardium* normal.

The heart-walls were thin and flabby, showing fatty degeneration. No ante-mortem clots were found.

*Liver* was small and showed evidence of cirrhosis, both externally and on section.

*Spleen* was greatly reduced in size; its capsule very much thickened. Medullary substance not changed.

*Kidneys* were slightly reduced in size and presented interstitial change. Cortical layer was considerably narrowed.

*Larynx*, œsophagus, and stomach normal.

*Intestines* normal.

At the bifurcation of the aorta was found a firm ante-mortem clot, extending about one inch upward and sending a prolongation downward into right common and external iliacs, thence into the common femoral artery, which was filled with clotted blood, and so distended on down through the superficial femoral to the bifurcation of the popliteal artery in the leg.

The specimen here presented shows parts of the aorta, its bifurcation, and the thrombosis filling up the entire lumen from the aorta down to the division into the tibials on the right side. The firm clot has of course fallen out in places after section in order to ascertain the condition of the arterial walls. No atheroma is found. Arteritis does not seem to have existed; hence a local cause for clotting is eliminated.

The question arises, What was the cause of this extensive ante-mortem clotting? Green, in his work on *Pathology*, says that an abnormality or removal of endothelium of the vessels is the essential condition, and groups the causes into: 1. Injuries or diseases which destroy the endothelium. 2. The presence in the vascular system of substances not covered by endothelium. 3. Imperfect blood-supply of a part, causing disease of the vessel-walls by imperfect nutrition. 4. Finally, conditions of the blood favor coagulation and promote the occurrence of thrombosis; thus in great loss of blood, as after hemorrhages. In septic fevers the increase of leucocytes and micro-organisms favors clotting. Da Costa in the *Transactions of the College of Physicians*, April 7, 1880, reports

three cases of what he terms "starvation fever." Two autopsies are recorded, but thrombosis is not mentioned.

This seems like a case of great impoverishment of the blood due to malnutrition (the fibrin factors being increased, as in starvation), and the resulting hyperinosis with a slowed circulation caused by the plugging of the aorta by embolism above; all finally resulting in so generalized a thrombosis.

The embolus, probably formed in the heart, was apparently too large for entrance into the carotid or subclavian, the tenacious mass being carried on down the aorta.

The occurrence of the severe pain in the right calf was undoubtedly due to the sudden cutting off of the circulation. Of course gangrene did not have time to develop, death supervening.

Dr. Carter suggested that the blood condition might cause the clotting, as bleeding and starvation increase the fibrin factors enormously experimentally.

Dr. Davis recalled a case very like this one, after confinement, in a woman thirty-seven years old.

Dr. Coplin detailed a case of his in which, after apparently complete convalescence from appendicitis, there was some pain in the right leg, and the limb grew white and cold, and, three days later, discolored. The thigh was amputated, but before this small discoloration, with pricking pain, had appeared on the back. The result was fatal, and at the autopsy the iliac artery was found solid. At the operation no clot was found in the femoral. *December* 14, 1893.

---

9. *Blood from a case of sarcomatosis resembling leukæmia.*

Exhibited by Dr. Daland.

The diagnosis of tuberculosis had been at first made in the case owing to the enlargement of the glands and the character of their enlargement. Upon counting the blood a leucocythermic condition was found present, the number of white blood-cells reaching 300,000 to the cubic millimetre, and the diagnosis of Hodgkin's disease made. The slide was shown under the microscope. At the post-mortem acute miliary sarcomatosis was discovered with involvement of the lymph-glands.

Dr. Scott remarked that specimens recently shown at this Society emphasize the fact that any nodular enlargements suspected to be tuber-

cular, carcinomatous, or sarcomatous must be carefully examined microscopically to establish the diagnosis.

Dr. Daland said he had under his care at the time of speaking a case of sarcomatosis without leucocytosis, and was watching it with interest to see if it prove one of those cases that show a terminal leucocytosis. The case reported above was not of that kind, as the condition of the blood as exhibited existed for at least two months.

*January* 11, 1894.

---

10. *Heart of a child two weeks of age, with a patulous foramen ovale, a triangular opening in the ventricular septum, and a small and contracted aortic opening in which no valves could be detected.*

Exhibited by Dr. LAINÉ.

The history of this case is most interesting. The mother of this child is a woman, aged forty-two years, married eighteen years, and has two living children, one ten and the other thirteen years of age, both decidedly feeble-minded. Two years ago a daughter, of about fifteen years, died in the Pennsylvania Institution for Feeble-minded Children at Elwyn. About four years ago I was called to attend the mother in confinement, and found the child presenting in the second vertex position. The woman had been in labor several hours, and, after various attempts at delivery with the forceps, I was obliged to perform craniotomy. With the exception of a very large head the child appeared to be normal. Two years after this she was delivered of twins, both of them dying within eight hours of birth, mottled and to all appearances cyanotic. No post-mortem was allowed.

About a month ago I delivered her of this child. The only defect noticeable was a hare-lip. It was fat, plump, and to all appearances perfectly healthy. On the morning of the fourteenth day I was suddenly called to the house, the nurse telling me that the child was dying. I carefully examined it and found both lungs hypostatic, and slow and weak pulse, with a distinct systolic bruit heard over the whole chest. The child only lived two hours from the time the nurse noticed the shortness of breath. Unfortunately in making the section the arch of the aorta with the ductus arteriosus was not preserved, but the dilatation of the pulmonary artery is very noticeable in this specimen, showing no doubt that the blood after leaving the right ventricle was pro-

pelled through the pulmonary orifice into the aortic arch through the ductus arteriosus and on through the general circulation.

*January* 11, 1894.

---

11. *Ulcerative endocarditis.*

Exhibited by Dr. GRIFFITH.

Girl, aged 25 years. Five years ago she had chorea of the left side, with recovery, except slight twitchings at menstrual periods. Later the chorea returned, especially during excitement. Some years later she had rheumatism, with violent chorea, in which the muscles of articulation were involved. The temperature continued high, and a heart-murmur appeared later, and septic endocarditis was suggested. As she grew weaker the heart-murmur became fainter.

*Post-mortem.* No abnormality was found anywhere except in the heart, where there was on the auricular side of one mitral leaflet a little patch of ulceration with vegetations around it. The brain showed nothing to the naked eye.

Dr. Burr was especially interested in the case from the obscurity of the pathology of chorea. Embolism is not at all common, though in this case there certainly was the vegetation and ulceration of the endocardium that might give rise to it. *March* 22, 1894.

---

12. *Aortic stenosis simulating aneurism.*

Exhibited by Dr. GRIFFITH.

The patient was a man, aged 45 years. There was no family history of note. He had had rheumatism twenty-six years before; also scarlet fever and typhoid fever. Six or eight years ago his symptoms began with pain, throbbing in mid-sternum, and short cough. During observation of him he had severe pain, with a thrill; a double murmur at the aortic cartilage, an increased area of dulness, and a distinct thrill, with marked pulsation of the cervical vessels. He had no pressure-symptoms.

*Post-mortem.* The aorta was found slightly dilated; the aortic opening stenosed to the extent of admitting the tip of the little finger with

difficulty. The orifice was calcareous and there was no atheroma of the aorta. There was a large pleural effusion in the right cavity.

*March* 22, 1894.

---

13. *Specimen of cardiac polyp.*

Exhibited by Dr. Frederick A. Packard.

The specimen was removed from a man, G. W., aged 50 years, who was admitted to the Pennsylvania Hospital on March 30, 1894, to the wards under the care of Dr. Longstreth, for whom I was substituting. He was a cashier by occupation, an excessive smoker of cigarettes, and a regular user of alcohol, at times to great excess. Except for repeated attacks of bronchitis and an attack of inflammation of the lungs ten years before, he had never been ill until six weeks before admission.

At the time last mentioned he developed a bad cough with slight expectoration, diagnosed by his physician as pneumonia. With this he was in bed for two weeks, at the end of which time he got up from his bed and went out. He seemed to again "catch cold" and took to his bed, with a temperature of 100° to 101°. He had remained in bed from that time until his admission.

On admission he was thin, pale, and very weak, his temperature being 98°, pulse 110, respirations 40. A systolic murmur was heard at the apex, and well transmitted. There was some impairment of resonance over both bases posteriorly, more markedly on the left side, where there were also a few crackling râles and distinct tubular breathing. Urine negative; specific gravity 1018.

He was given ammonium carbonate, whiskey, and digitalis.

During his stay in the hospital his condition changed but little. He was very short of breath, very weak, and somewhat drowsy. The temperature ranged from 96° (on one morning) to 103°, without any marked regularity. His pulse gradually became weaker.

*Autopsy* was held four hours after death. No rigor mortis was present. The *left lung* showed an old healed apical lesion, gray hepatization of upper lobe, no hepatization of lower lobe. The lower lobe of the *right lung* was airless, and on section was seen to be of a grayish-red color. The *spleen* weighed seven ounces, was enlarged, firm, and brittle, and contained two small infarcts.

The *kidneys* were somewhat large, and in that on the right side there was a large infarct.

The *liver* was rough on the surface, yellow on section, and was distinctly cirrhotic and fatty.

The *heart* was large, its apex rounded, covered by a moderate amount of fat. The right auricle was normal. The right ventricle was somewhat dilated, its wall measuring a half-inch in thickness. Valves of right side of heart normal. Tricuspid orifice admitted four fingers. Left auricle dilated and somewhat hypertrophied. Springing from the posterior wall of the left auricle there is a large polypoid mass, almost filling the auricular cavity, generally of a club-shape, measuring two inches in length and an inch and a half in diameter at its free extremity. It had a distinct stalk which was firmly attached to the wall of the auricle, and appeared to be covered by a continuation of the endocardium. The club-shaped free extremity of the growth is covered by calcified rough material resembling cauliflower. The mitral orifice admits three fingers. At the base of the mitral valve leaflets there are thickened atheromatous areas. The chordæ tendineæ are thickened, and one is imperfect, the separated ends of which look as though the chorda had been divided by an ulcerative process. The wall of the left ventricle measured five-eighths of an inch in thickness. The aortic valve leaflets were slightly thickened.

The polypoid mass was unfortunately lost after being exhibited at the meeting, so that sections could not be made in order to determine its structure.

The dyspnœa caused by assuming the erect position, which has been emphasized by Pawlowski (*Berlin. klin. Wochenschr.*, May 6, 1895), was not noted as present in this case, although the patient was at no time sufficiently strong to permit of any but the slightest movement, and, it is possible, that he was at no time made to sit up for examination.

*April* 12, 1894.

---

14. *Aneurism of the heart.*

Exhibited by Dr. Daland.

The heart was enlarged, and there was considerable fat exteriorly. At the apex there was some pericarditis. There was a pouching of the lower part of the left ventricle the size of a mandarin orange. The lowest part of this pouch corresponded with the area of localized pericarditis. This may be considered an aneurism. The interventricular

septum shows marked fibroid change, especially on the left side. There is an area of ulceration in the left ventricle to which an old clot the size of a grape was adherent.

Dr. Scott considered the aneurism probably due to softening from embolism of the coronary artery with subsequent myomalacia.

Dr. Coplin thought the dilatation of the ventricle could hardly be called an aneurism. He had seen aneurism communicating with the cavity by a narrow neck only.

Dr. Daland replied that this is the usual seat for degeneration in the myocardium, and most aneurisms are in this situation. *May* 10, 1894.

---

15. *Dissecting aneurism of the arch of the aorta.*

Exhibited by Dr. Daland.

A bovine heart, with large aortic valves. An old scar was seen just above the valves, the remains of a break in the intima of the aorta, and above this were two openings, with an opening posteriorly into the pericardial cavity, which had given rise to hemorrhage causing sudden death.

Dr. Coplin thought the scar was from a syphilitic lesion.

*May* 28, 1894.

---

16. *Thoracic aneurism, rupture into œsophagus.*

Exhibited by Dr. Frederick P. Henry.

J. O., aged 55 years, Irish, single, tailor, an inmate of the pauper department of the Philadelphia Hospital. The previous history of the patient was obtained from one of his fellow "out-warders," and is consequently very incomplete. It was to the effect that he had been a hard drinker, had had syphilis, and had complained a great deal of pains throughout his body, and often of a severe pain after eating. About two weeks before his death he had refrained altogether from eating for a period of three days, on account of the pain referred to. It could not be ascertained whether he had complained of dyspepsia. Seven days before death he vomited blood in the yard, the amount being estimated at from half a pint to a pint. The day before death he again had a severe attack of hæmatemesis. This time one of the house physicians

was notified and ordered the man to be sent into one of the medical wards. The following notes were taken by the resident physician at the time of admission:

No history of cough, complains of weakness, no restlessness, face of natural color, lungs apparently normal, area of liver-dulness normal, heart's action irregular, systolic murmur over aortic cartilage transmitted into vessels of neck; a second murmur supposed to be mitral was heard over a large area, including apex and lower portion of sternum, and also over the left scapular region.

Temperature 97.4°, pulse 80, respiration 20.

Patient passed a comfortable night, and the next morning sat up in bed. He had hardly done so when a stream of blood poured from his mouth and nostrils. Death from hemorrhage in half an hour. It was found after death that blood had also escaped from the bowels.

*Notes of autopsy.* On opening the abdomen the stomach and large intestine were seen to contain a considerable quantity of fluid. Abdominal cavity, serous sacs, and pericardium normal.

*Heart.* Mitral valves normal, aortic valves slightly thickened and atheromatous, ascending portion of aortic arch markedly atheromatous and the seat of several small saccular dilatations, the summits of which were thin and transparent.

*Lungs* emphysematous; bronchial tubes free from blood.

*Stomach* contained two pints of bright-red blood, about one-half of which was coagulated. The *large intestine* contained over a pint of dark blood, a part of which presented the appearance of coffee-grounds. In order to trace the source of this extensive hemorrhage, which, up to this stage of the examination, was not apparent, the aorta and œsophagus were removed *en masse*, and the œsophagus then laid open longitudinally. As the result of this dissection a circular, perforating ulcer of the œsophagus, 2½ cm. in diameter, situated 7¾ cm. from the cardiac extremity of the tube, was revealed. The œsophageal ulcer communicated with a sacculated aneurism of the thoracic aorta, which measured about 20 cm. in circumference and 7½ cm. in length. Both the aneurism and the œsophageal ulcer were filled with laminated clot, a small imperfection in which had permitted the fatal escape of blood. About 8 cm. lower down there was another sacculated aneurism measuring about 26 cm. in circumference, 11½ cm. in length, and filled with laminated clot. This aneurism had eroded the bodies of the eighth and ninth dorsal vertebræ to a considerable extent, without, however, penetrating into the vertebral canal.

The *kidneys* were contracted, *spleen* apparently normal, *liver* somewhat firmer than normal. *May* 25, 1894.

17. *Aneurism of the aorta rupturing into the œsophagus.*

Exhibited by Dr. Craig.

I have the honor of presenting for your examination and study this evening a specimen removed from the body of an interesting case which was brought into the Philadelphia Polyclinic Hospital April 10, 1894, and there came under the care of Dr. S. Solis-Cohen, for whom I have the pleasure of reporting the case.

The history obtained was as follows: G. F., aged 38 years, white, single, and an iron moulder by trade, had been in fair health up to the day of his admission to the hospital. He had not, however, been "strong" for some months, having a pain at intervals in his left shoulder. Upon the day in question he ate a hearty dinner, and shortly after his meal he felt ill and went to the water-tank to get a drink. While drinking he was seen to fall and was found to be bleeding quite profusely from the mouth. The hemorrhage soon appeared to stop, and he was brought at once to the hospital, where he was received by my friend and colleague, Dr. Maurice A. Bunce. Shortly after his admission he had a second hemorrhage, which was large in amount and contained clotted blood and food.

As the man was very weak from the loss of blood, a thorough physical examination was not made at once. Rest and a very light diet were prescribed for a couple of days.

Upon the third day after his admission I was hastily called to the patient's bedside and found him unconscious, with several fluidounces of bright scarlet blood on his pillow. There was no bleeding from the mouth or nose at the time, but the man was evidently losing blood very rapidly. He died in about half an hour after the hemorrhage began.

A post-mortem examination was obtained, at which the following notes were taken:

*Rigor mortis* was very marked at the time of the examination, which was about seven hours after death.

Upon opening the abdomen all the viscera appeared normal. The ascending and transverse colons were much distended.

The thoracic contents were first examined. The *left lung* was found to be entirely free, well distended, a little cyanotic posteriorly, and on section the lower lobe was somewhat œdematous. The *right lung* was

adherent by a few easily broken bands anteriorly, laterally, and at the base; otherwise as the left lung.

The pericardium appeared normal and contained about three fluid-drachms of clear fluid.

The heart was about normal in size and was covered with a layer of fat, especially marked about the right auricle and auriculo-ventricular junctions. Its internal structure was apparently normal.

In following out the aorta we came upon the cause of the man's death, when we found an aneurismal sac at the junction of the transverse and descending aorta. The aneurism had eroded the bodies of the third, fourth, fifth, and sixth dorsal vertebræ, about one-third the surface of the first and last, and two-thirds the surface of the middle two being affected. There was also a perforation through an ulcer in the walls of the aorta opening into the œsophagus.

The *liver* showed no pathological changes.

The *stomach* was nearly full of clotted blood, but its mucous membrane showed no sign of any disease.

The *spleen* was soft and friable.

The *left kidney* was surrounded by a comfortable layer of fat, full sized, rather pale, the cortical structure increased and pale, while the medullary portion was cyanosed. The capsule was not adherent. The *right kidney* was similar to the left, but had several small areas of firm whitish accumulation.

In looking for a cause for our endocarditis, we turned first to an inspection of the genital organs and found a very tight prepuce, with the glans covered with smegma. Upon cleaning this away we found a cicatrix at the junction of the glans and the reflecting layer of the prepuce near the frænum. A delicate radiating scar was also found just above Poupart's ligament on the left side. *May* 25, 1894.

---

18. *Thrombosis of the left ventricle with pulmonary infarction.*

Exhibited by Dr. Alfred Stengel.

The patient from whom the specimens were obtained was a man, aged 40 years, who presented himself at the University Hospital, complaining of shortness of breath and general fatigue. The man's appearance was anæmic and rather sallow. The eyes were a little puffy and the ankles slightly swollen. On examination his heart's action was

found to be exceedingly irregular, and frequent intermissions occurred. The size of the organ was increased so that it extended beyond the nipple-line. The heart-sounds were weak and rather muffled. There were no murmurs. The urine contained some albumin and granular casts.

Subsequently the patient was admitted to the hospital, having in the meantime been comparatively well. On his admission he was found to be very ill. The heart's action was wretched, the rhythm having become completely destroyed. The heart-sounds were extremely weak, and there was now heard a slight systolic apex murmur. Treatment was of no avail. After several days a sudden attack of excessive dyspnœa occurred; hæmoptysis occurred; and on physical examination areas were found, particularly at the base of the left lung, where the percussion was dull and the breath-sounds harsh in character. The diagnosis of embolism was then made. Subsequently pain and excessive albuminuria gave evidence of renal embolism.

The organs exhibited are the heart, lungs, and kidneys. The heart is seen to be greatly enlarged on both sides. The substance is rather softer than normal and of a yellowish color. The anterior wall of the left ventricle seems to be somewhat dilated or thinned, and within this cavity is seen a perfect picture of cardiac thrombosis. A layer of fibrinous deposit of varying thickness covers the endocardium, and is attached between the papillary muscles so that it cannot be removed without destruction of the lining membrane. It is light in color and of rather friable structure, and in particular it contains small cyst-like areas, some of which have broken, leaving cup-shaped hemispherical depressions with raised edges. These have doubtless been formed, as certain pathologists have pointed out, by softening in certain portions of the deposit and the formation of liquidation cysts. The thrombosis occupies the region of the apex on the anterior, posterior, and outer wall of the heart. The endocardium above the clot and on the septum is healthy in appearance. The valves are normal, and there is no disease within the right heart. The lungs contain a number of embolic areas. These are small spherical nodules varying in size from a marble to a walnut, having a yellowish color and being cheesy or puriform within. The periphery is composed of a compact substance, forming a sort of capsule. A number of such lesions were seen in each lung. They were surrounded by more or less extensive areas of pneumonic consolidation, the affected parts having a mottled, red color, and a rather granular appearance. Hemorrhagic areas were not infrequent. The kidneys present lesions of chronic diffuse nephritis, the cortex

being wider than normal. The substance is of light color, verging toward yellow. In addition there are several recent hemorrhagic infarcts.

These specimens present a typical example of intra-vitam thrombosis of the heart. Sometimes it is difficult to determine whether the clot has been formed within a recent period before death or at a considerable interval. In a case, however, such as the one exhibited, there can be no question that it was formed during the active lifetime of the patient and not in the agonal period before death. The point upon which stress has been laid by writers, viz., that in ante-mortem thrombosis the clot is so intimately attached to the lining membrane that it cannot be separated without loss of substance, is well illustrated by this case. Further, the cysts formed seem to me to be important as indicating the duration of the process. Such cysts, it would appear, might easily have been mistaken for hydatids before the pathology of the latter was well understood. The emboli of the lungs suggests another interesting observation, viz., that an apparently well-formed capsule may be formed in the course of a few days. From the time of the embolic seizure until the death of the patient less than a week elapsed, yet the capsules in several instances were well marked. *June* 14, 1894.

---

19. *Specimens from a case of fatty degeneration and infiltration of the heart, causing sudden death.*

Exhibited by Dr. Daland.

The patient was a woman, aged 65 years, who had no history of previous ill-health. She was very obese, weighing 250 pounds. One morning she suddenly died. The autopsy showed everything normal except the heart and the obesity. The fat in the abdominal wall was four or five inches thick. The heart was larger than normal and the great quantity of fat on the surface was striking. The wall of the left ventricle was not thickened, but was light in color and showed evidences of fatty degeneration. The cavity was dilated. There was no lesion of the valves. There was an atheromatous patch on the aorta an inch above the free edge of the aortic valve. The right heart was similar. This was regarded as a case of sudden death due to fatty infiltration and degeneration. *June* 14, 1894.

### 20. *Cardiac hypertrophy.*

Exhibited by Dr. J. M. Swan.

The patient from whom this specimen was taken was admitted to the Presbyterian Hospital December 15, 1893, complaining of palpitation of the heart; anginoid pains running to the left shoulder; dyspnœa; short hacking cough with no expectoration; and œdema of face, feet, and legs. He weighed 242 pounds. He gave a history of high living and frequent indulgence in all kinds of alcoholic beverages, late hours, and exposure, often repeated. On admission signs of bilateral pleural effusion were present, which increased as the case progressed. Above the level of the effusion the breathing was harsh and bronchial in character, with sonorous and sibilant râles. The præcordia was bulging and the seat of a heaving pulsation; epigastric pulsation also noted. Apex-beat, on admission, in sixth interspace 3 cm. beyond mid-clavicular line. Later in the case, as the pleural effusion increased, apex-beat was in fifth interspace 4 cm. outside mid-clavicular line. The upper border of cardiac dulness at third rib, left margin 4 cm. beyond mid-clavicular line, right margin at mid-sternum, lower margin at sixth rib. The sounds were very rapid and irregular and had lost much of their muscular quality. A systolic murmur was heard at the apex and transmitted into the axilla. Sounds at the aortic cartilage were indistinct.

Hepatic dulness from sixth rib to costal margin; splenic dulness from seventh to tenth ribs. Abdomen was very large, and flabby, and pendulous, with bulging in the flanks, and to my examination gave all the signs of ascitic fluid; but which proved to be due to an excessive amount of fat in the abdominal wall and mesentery. Percussion for hepatic dulness was interfered with.

The pulse was very irregular, and varied between 48 and 92 beats per minute. Respiration ran between 24 and 40 per minute. There was a temperature of 102° the first two days of residence in the hospital.

The patient died suddenly of dilatation of the right heart while putting on his shoes. It was impossible to keep him quiet.

*The autopsy showed:* The body of a large white man, aged about 50 years; weight 250 pounds; neck short and thick; eyes protruding; bulging in flanks giving a sensation of fluctuation; legs swollen, pitting on pressure. Post-mortem rigidity well-marked and post-mortem lividity prominent.

The abdominal wall was 6 cm. thick and heavily laden with fat. The transverse colon was distended, omentum and mesentery thickly laden with fat. The liver projected 9 cm. beyond the margin of the ribs in the left mid-clavicular line, 13 cm. in median line, and 9 cm. in right mid-clavicular line. Appendix patulous to the end; contained one or two concretions of fæcal matter. It was furnished with a mesentery connected with the mesentery of the small intestine. It was 11 cm. in length and pointed down into the pelvis.

*Thoracic cavity.* The walls were very thick, subcutaneous fat very well marked. There were 1000 c.cm. of blood-tinged serum in the right pleural cavity, and 550 c.cm. of fluid more markedly hemorrhagic in the left pleural cavity. The left lung was entirely retracted behind the costo-chondral junction, and the right lung was visible for 4 cm. only. The remainder of the middle of the thoracic cavity was occupied by the enlarged heart and pericardium. The pericardium was heavily loaded with fat, and there were several recent adhesions between the visceral and parietal layers, which were readily broken up. Fluid normal in amount. The *heart* was dilated, both auricles and the right ventricle distended and filled with a mixture of fluid and clotted blood. In the left ventricle, which was contracted, a chicken-fat clot extended into the conus arteriosus and part way into the aorta. The auriculo-ventricular opening admitted four fingers, the right four fingers and the thumb. The mitral valve leaflets were much thickened at the edges; the aortic semilunar valves were also thickened along the lunula. The tricuspid and pulmonary valves were normal. The heart-muscle was very much hypertrophied, and there were evidences of beginning fatty change. There was a large amount of fat in the auriculo-ventricular and inter-ventricular grooves. A few small atheromatous ulcers were seen in the arch of the aorta. The microscope showed decided hypertrophy of the individual muscle-fibres and a deposition of fatty granules about the nuclei, which were very indistinct, and a generally cloudy appearance of the whole muscle-fibre. Weight of heart with clots, 1170 grammes; without clots, 1070 grammes.

*Lungs.* There were recent adhesions between the visceral and parietal layers of the pleuræ, not very many nor very strong. Both lungs were compressed. Anterior margins and apices emphysematous. On pressure a considerable amount of fatty, blood-tinged fluid exuded. Weight of left 700 grammes; right 800 grammes.

*Kidneys.* Both were imbedded in a large amount of perinephritic fat. The organs were large, broad on the convex surface, congested, and showed evidence of fatty degeneration. The left organ showed increased

connective tissue about the bloodvessels. Capsule not adherent. The right ureter was slightly dilated. The microscope showed distinct fatty degeneration of the renal epithelium, and there were several fields where the Malpighian tufts were absent from the capsule of Bowman. Weight: left 300 grammes; right 275 grammes. Spleen was large and congested; tissue soft and pliable. Weight 470 grammes.

*Liver* was twice the normal size; edges rounded, dark in color. The organ was congested. The microscope showed fatty infiltration of the liver-cells, and in places commencing fatty degeneration. Weight 3070 grammes.

*Pancreas* normal. *Bladder* empty.

*June* 14, 1894.

---

21. *Traumatic pyo-pericardium in a child of six months.*

Exhibited by Dr. Thompson S. Westcott.

L. R. G., a male child, aged 6 months; fed partly at the breast and partly with condensed milk; was brought to the Surgical Dispensary of the Methodist Hospital in the latter part of August, 1894. It was stated by his mother that several days previously, while tied in his high chair, he had fallen forward to the floor, but was apparently not much hurt. He seemed restless and irritable, however, and examination showed a small lump in the skin of the abdomen in the left half of the epigastrium; for this he was brought to the hospital for advice. The swelling was described as being close to the costal margin, and was supposed to be a dislocation of the cartilage of one of the false ribs, and was treated accordingly with a band of adhesive plaster, and the case dismissed for several days. At a subsequent visit the lump had become inflamed and a point of suppuration was evident. Closer inspection revealed the eye of a large sewing-needle, one and three-quarter inches in length, projecting from the opening, from which it was readily extracted. The wound was simply cleansed and dressed for the first week, during which discharge continued. A probe now gently introduced into the opening penetrated backward and slightly upward for a distance of from two and a half to three inches, seemingly in a direction parallel with and close to the under surface of the diaphragm. Pus flowed along the groove of a director introduced into this tract, but its close relation to the peritoneal cavity rendered the injection of fluid a

hazardous proceeding. Drainage, however, was maintained by a twist of iodoform-gauze. In a few days the tract had apparently healed, but the child was restless and seemed to be in pain. The fistula was reopened and gave issue to more pus, with a relief of the general symptoms. Closure again occurred, to be followed in a few days by quite a severe attack of gastro-enteritis. The child now became a patient in the medical dispensary, where I saw him for the first time several days later, about September 10th. The bowel condition had somewhat improved, but the respiration was labored and there was occasional cough. Physical examination showed the scar in the epigastrium one-half inch below and one-half inch to the left of the xiphoid cartilage. On percussion a large area of flatness was mapped out extending upward from the costal margin to the first rib, and from the right border of the sternum to the left nipple-line. Beyond this the resonance of the left lung showed a marked contrast, and except for a somewhat feeble respiratory murmur over the rest of the left lung, nothing abnormal was here noted. Over the area of flatness no respiratory sounds were audible, and at the position of the apex-beat, which was included within the area of dulness, the cardiac sounds were distant and the impulse could not be felt. The intestinal condition, however, was most urgent, and the child was dismissed until the next day, the chest being treated to a good coating of iodine. At the next visit the condition of the bowels had improved, and the area of thoracic dulness had decreased materially, so as to clearly outline an enlarged pericardium. The general condition had improved, the pulse had regained force, and the temperature was not elevated. Further improvement followed in the next few days, the area of pericardial dulness decreasing, although it never reached normal dimensions.

At this time the diagnosis of pericardial effusion was fully settled, and the question of its relation to the suppurating tract and the wandering needle carefully considered. The rapid subsidence of a large part of the effusion, together with the uncertain history of the case, and the absence of any evidences of septicæmia, militated against a purulent collection ; and the tender age of the child, its weakened condition, and the fact that it was an out-patient of the hospital, deterred us from using a hypodermatic puncture to discover the true character of the effusion at this time, as the possibility of successful treatment by incision and drainage in so unpromising a case, in the light of statistics, was infinitely small. The case was, therefore, watched from day to day and its strength supported, until September 22d, when it was noticed that the condition was becoming worse. Œdema of the legs developed, the

area of dulness increased, and death occurred after several convulsions, followed by coma, on September 23d.

*Autopsy.* A marked prominence over the front of the left half of the chest from the mid-sternum to a line one-half inch outside of the left nipple-line. Dulness extends from the lower border of the first rib to the upper border of the seventh, and from the right border of the sternum to the left anterior axillary line. The external wound from which the needle came is completely healed and a strong cicatrix is found on the aponeurosis of the left rectus abdominis. Beneath the cicatrix is an area of peritonitis in process of healing. The peritoneum is adherent to the left lobe of the liver over an area of about one and a half inches square.

On opening the chest by cutting through the costal cartilages at their junction with the ribs the *right* parietal pleura is found normal and the lung pale and crepitant. At the anterior margin a few thin adhesions unite the visceral pleura to the pericardium, while the mediastinal surface is adherent to the pericardium by numerous adhesions. On freeing these the greatly distended pericardium is seen reaching on the transverse nipple-line from the costal extremity of the fourth rib to the right side and disappearing under the ribs on the left side, where it is adherent. Superiorly the sac reaches up to the clavicle, and below it is solidly adherent to the diaphragm. The walls of the sac are thick and rough to the touch and contain numerous vessels.

On the left side, from the costo-chondral margin, the pericardium is adherent to the parietal pleura by fibrous adhesions readily broken under pressure of the fingers, but under the second left interspace just beneath the costo-chondral junction the adhesions are very firm and are broken up with great difficulty. On freeing these adhesions the anterior border of the left lung is found closely adherent to the pericardial sac on a line drawn one-half inch to the left of the costo-chondral junction. The lung is compressed, but is normal in color and everywhere crepitant, except at the posterior inferior border, where there are several small areas of infarction. The right lung also shows small infarcts in the same position and also on the superior edge of the lower lobe posteriorly, while numerous smaller areas are scattered over the surface of both lungs. The pleural cavities are free from fluid.

The pericardial sac contains 60 c.c. of thick yellow pus containing curds of lymph. The wall of the sac is tough and measures 1 mm. in thickness. By cutting open the sac after evacuating the pus the whole visible surface of the heart is seen to be covered with shaggy, "custard-like" masses of lymph. The posterior surface of the organ is adherent

to the pericardium by thick, soft layers of lymph, extending toward the apex and base. These adhesions are soft and easily broken, leaving the visceral pericardium roughened, congested, and hemorrhagic in places, and covered by masses of the same shaggy lymph. Posteriorly near the roots of the great vessels there are areas of ecchymosis, and on the lower inner surface of the sac, corresponding to the diaphragmatic area of adhesion, there is a circular area of deep congestion, of currant-jelly color in its central portion, measuring about 12 mm. in diameter. On the lower surface of the diaphragm, at a point exactly corresponding to the area of deepest coloring, is a small circumscribed subperitoneal hemorrhage. A probe introduced without force easily makes its way from the pericardium to the abdominal cavity, giving exit to a minute collection of pus inclosed between the layers of tissue.

The heart-muscle is normal in appearance and the valves and chambers are normal.

The left lobe of the liver is adherent above to the diaphragm over almost the whole of its extent. The mucous membrane of the transverse colon is swollen and reddened and shows punctate hemorrhages, especially near the ileo-cæcal valve.

The kidneys are swollen and hyperæmic. Other organs show no change.

Bacteriological examination of the pus showed the presence only of the staphylococcus pyogenes.

The special interest in the case lies in the connection between the pericardial abscess and the wandering needle—the finding of a spot of firm localized pleuritic adhesion on the left side in the second interspace of the costo-chondral junction; the pyo-pericardium with hemorrhagic effusion beneath the serous membrane near the base of the heart; the ecchymosis beneath the inner diaphragmatic surface of the pericardium; the spot of hemorrhage on the under surface of the diaphragm marking the point of perforation; the evidence of localized peritonitis over the upper surface of the left lobe of the liver, and, finally, the epigastric sinus and the discharge of the foreign body. All these findings seem to point to the progress of the needle from the second interspace on the left side downward, into the pericardium, around the heart and its great vessels, through the diaphragm, and so out at the epigastrium.

It therefore seems most probable that the pericardial suppuration really preceded the discharge of the needle, and closer questioning brought out the fact that the baby had been failing for three weeks before his fall from the chair. If the probe did not actually pass through the diaphragm and into the pericardium at the point of per-

foration it was in close relation with the under surface of the diaphragm, and the perforation must have occurred previously, for on this supposition alone can we explain the relief given by the second opening, and drainage of the sinus. No pocket of pus was found beneath the diaphragm at the autopsy, and, except for the adhesions over the left lobe of the liver, no evidence of the tract through which the probe had passed.

Purulent pericarditis is an unusual condition at any age, but is especially rare in childhood, occurring then most generally as a complication or a sequel of broncho-pneumonia, or pleurisy accompanying the pulmonary inflammation. Occasionally it is found secondarily to other infectious conditions, such as umbilical infection, osteomyelitis, membranous angina with retro-pharyngeal abscess, etc. In 17 cases collected by Haushalter and Étienne (*Revue mens. des Mal. de l'Enfance*, August, 1894), in which a bacteriological examination had been made, 9 cases showed the pneumococcus; 5, the streptococcus; 2, the pneumo-bacillus of Friedländer; 3, the staphylococcus; in one case the staphylococcus being associated with the streptococcus, and in another with the pneumococcus.

In this case the operation of paracentesis pericardii for purulent effusion offered practically no hope of cure. Of 15 cases collected by Février up to 1889, 11 were treated by puncture and 4 by incision and drainage. Of the 11 all died; of the 4 treated by incision, 2 (Rosenstein's and West's) recovered, both being adults. Aside from the tender age and weakened condition of the infant, which in our opinion forbade so serious an operation, the post-mortem findings bear out the wisdom of our decision. The pericardial sac was greatly thickened and had lost its elasticity, so that collapse after evacuation would have been greatly interfered with or prevented, aided as this would have been by the numerous adhesions to the lung and the chest-wall. Again, nothing but prolonged scraping could have relieved the heart of the shaggy coating of lymph which was closely adherent to it, and nothing but prolonged irrigation could have cleansed the cavity—a proceeding which in one case at least (Parker's) caused a fatal termination.

Dr. Leonard adds that closure of the sinus occurred when gauze would slip out.

Dr. Stengel mentioned a similar case of Professor Smith's.

The President noted the existence of mediastino-pericarditis, and asked as to the presence of collapsing veins. It was replied that these were rare. The President had had two cases in influenza, both streptococcus infection. In one case a free incision was made, but death ensued. At the autopsy it was found that the incision was too small,

and much pus was still remaining. The other case was a physician with purulent pericarditis upon whom an operation was not undertaken.

*October* 25, 1894.

---

22. *Tricuspid stenosis associated with mitral stenosis and aortic stenosis.*

Exhibited by Dr. Thomas G. Ashton.

The clinical history is as follows:

W. N., aged 19 years, a japanner by occupation. Both parents are living and in good health, and in the family of neither is there a history of rheumatism.

The patient appeared to be healthy at birth. When six years of age he had measles, his childhood being otherwise uneventful until his fifteenth year, when he suffered from an attack of influenza. With the latter affection he was ill two weeks, but, while unable to attend to his usual work during that period, was not confined to bed. The chief symptoms of the influenza were referred to the head, bone pains being of very moderate degree. There is no personal history of scarlet fever, nor had the patient at any time suffered from what might be termed a frank attack of rheumatism, although at various times vague pains, somewhat rheumatic in character, had been complained of.

For the six years preceding his death the patient's occupation had been that of a japanner, and therefore one that entailed no very laborious exercise. Throughout his entire childhood he had lived a very quiet and retired life, and never indulged in the active pursuits of his playmates, although there never appeared to be, as his mother stated, any physical incapability. When first he accepted employment, however, in the year 1888, it was remarked that he could not walk to and from the factory, a distance of some thirteen or fourteen blocks, without suffering great fatigue. No especial cardiac symptoms showed themselves, however, until about four years preceding his death, when, after a hard day's work, he would frequently complain of præcordial distress and cardiac palpitation associated with easily induced shortness of breath. Upon such occasions the violence of the cardiac impulse had been noticed, and it was of sufficient strength to make itself evident through the several layers of the patient's clothing. At that period, however, his color was good, and there existed no further evidence of ruptured compensation.

Toward the end of March, 1894, the patient began to show signs of

cardiac failure. Upon exertion, especially upon bending over, his face, which usually had a good color, would become decidedly blue, and even the slightest exertion was sufficient to induce shortness of breath.

The patient's habits had always been abstemious; he had never used alcohol or tobacco, and, as previously stated, had never taken any interest in athletic exercise.

On June 23, 1894, he first made his appearance at the clinic of the out-patient medical department at the Jefferson Medical College Hospital. The notes of the physical examination made at that time are as follows: Marked cyanosis of the patient's lips, cheeks and hands; dyspnœa evident; puffiness of under eyelids and marked pretibial œdema; the radial pulses were imperceptible, and it was impossible, therefore, to obtain a sphygmographic tracing.

Inspection of the præcordium revealed a greatly extended impulse which was plainly perceived as far as the sixth interspace and one and one-half inches to the left of the nipple; there was marked pulsation in the epigastric region, which also extended well to the right of the sternum.

Upon palpation the cardiac impulse and apex-beat were found to possess but little force. A feeble thrill was detected above the apex-beat of the heart, the time of occurrence of which was presystolic; no thrill existed over the tricuspid area.

Auscultation at the apex revealed a systolic murmur, soft and of moderate intensity, which was plainly propagated into the left axilla. Above the apex, and at a point corresponding to the thrill above mentioned, was heard a murmur, presystolic in time, harsh in character, and terminating abruptly with what appeared to be the first sound of the heart. At a point below this, upon a level with the apex of the heart, but about one and a half inches to the right, it was possible to hear both the systolic and the presystolic murmurs. To the right of the sternum, toward its lower end, was heard a murmur of systolic time and differing in its characteristics from that heard at the apex. There existed no visible pulsation in the veins of the neck, nor was it possible to detect hepatic pulsation.

At the aortic cartilage no murmur was heard save that supposed to have been transmitted from the apex, which, as the great vessels of the neck were approached, disappeared altogether. The pulmonary sounds were clear.

The clinical diagnosis was combined mitral stenosis and incompetency associated with tricuspid incompetency, the latter supposed to have been a relative defect depending upon primary mitral disease.

The specific gravity of the urine was 1017; its reaction acid; it con-

tained no sugar; albumin, however, existed in large amount, but no casts were found.

The patient's condition became so serious that he was unable to return to the hospital, and subsequent treatment was conducted at his home; nevertheless, his symptoms became progressively worse. Toward the end anasarca of the lower extremities became marked, and effusions took place into the abdominal, pleural, and pericardial cavities, while throughout both cyanosis and dyspnœa were extreme.

On July 28, 1894, the patient died.

FIG. 1.

Showing narrowing of the tricuspid orifice and intimate adhesion of the three cusps of the valve. Observed from the auricular aspect.

The autopsy notes read as follows: The body that of a young man, about nineteen years of age. Post-mortem rigidity marked; slight discoloration of the dependent portions of the body; general anasarca, most marked in the lower extremities; abdomen distended; the skin generally extremely white and glistening, due to distention.

*Thorax.* Upon opening the thoracic cavity the lungs were hidden from view by a greatly distended pericardium. Both pleural cavities contained clear serous fluid; that of the left side three pints, that of the right side about two quarts.

The lungs were partially collapsed and lying in the upper part of the thoracic cavity along the spinal column. The left lung showed considerable œdema and some hypostatic congestion at its base. The right lung was deeply congested, and at its base was a moderate-sized area of consolidation, a piece taken from which sinking when placed in water. Neither lung showed any evidence of a recent or old tuberculous process.

The pericardium, upon being opened, was found to be filled with a blood-stained serum, the measured quantity being fifteen ounces. In several places the parietal layer appeared to be adherent to the right auricle.

FIG. 2.

Showing narrowing of the mitral orifice; the light shading about the orifice and upon the auricular wall denoting calcareous plates. Observed from the auricular aspect.

The heart's right chambers were found to be distended with soft blood-clots, the left side being completely empty. The apex of the right ventricle extended about one inch below that of the left ventricle. Upon the external surface of the right auricle could be seen four small openings, each about 5 mm. in diameter, two being at the upper portion and two near the right auriculo-ventricular boundary. Corresponding points were noted upon the parietal pericardium, denoting that the latter at these places had been adherent to the auricular pericardium.

Upon opening the right auricle it was found to be filled with dark, soft clots; its cavity was much enlarged and its walls thickened. The auriculo-ventricular orifice was much narrowed and would permit the passage of the middle finger only with some difficulty. As observed from the auricular aspect the three cusps of the valve were found to be firmly adherent to each other and very much thickened, resulting in a stenosis of the tricuspid orifice of the button-hole variety. The valve, though thickened, was smooth and free from any calcareous deposits. The cavity of the right ventricle was much enlarged and its walls increased to about 1 cm. in thickness. The pulmonary valves were normal.

The left auricle contained a small quantity of fluid-blood, but was not distended. Through the auricle the mitral opening was found to consist of a mere slit, the edges of which were in firm and close approximation, so that even the tip of the little finger could not be inserted into the opening. The valvular ring upon its auricular surface was rough and hard, having many sharp calcareous projections which extended in several places upon the inner surface of the auricular wall. The slit constituting the mitral opening, being so short and the edges so firmly approximated, could have permitted but a very small quantity of blood to pass through.

Fig. 3.

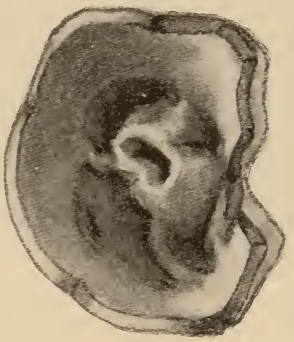

Showing narrowing of the aortic orifice; the leaflets of the valve adherent together, resulting in a funnel-shaped projection, the narrow end of which points toward the aorta. Observed from the aortic aspect.

The left ventricle was found completely empty; its cavity was greatly reduced in size, and its walls of great thickness. The aortic valve, by the water-test, showed no incompetency. The most extreme grade of aortic stenosis existed; the semilunar leaflets were firmly adherent to one another, resulting in the formation of a funnel-shaped deformity, the small end of which projected into the aorta some distance, and possessed

an opening that would no more than admit the tip of a slate-pencil. The aortic orifice also showed some slight degree of atheroma.

The abdomen was found to contain a large quantity of ascitic fluid. The intestines appeared to be normal. The other organs presented the conditions that might be expected to attend an advanced case of cardiac disease in which the right side of the heart had become involved. The liver was enlarged, congested, its lobules distinct, and its tissue upon section dense. The spleen also was enlarged and of increased firmness. The kidneys were somewhat increased in size and congested, the cortices being increased in width; their capsules stripped readily. The remaining abdominal organs were normal. *November* 8, 1894.

---

23. *Arterio-venous aneurism of the arm.*

Exhibited by Dr. Barton.

The patient was a locomotive engineer whose arm was injured by the bursting of a glass gauge in his engine, resulting in an arterio-venous aneurism of the venæ comites and of the brachial artery. The brachial artery was tied, but immediately after recovery from the other there was great pain. No circulation was obtained, so the arm was amputated. *November* 22, 1894.

---

24. *Aneurism of the heart.*

Exhibited by Dr. Coplin.

This occurred in a man who had symptoms of poor circulation. He was syphilitic and had been treated at the hospital for it. He died without a diagnosis, and the physical signs were not made out, as he was lousy and too ill for examination. He had had evidence of cirrhosis of the liver. Post-mortem showed the subcutaneous fat œdematous; the muscles atrophied, pale, and œdematous. In the thoracic cavity there was recent effusion of fluid on both sides. The left lung was partially collapsed and adherent to the pericardium. The lungs were otherwise normal.

The heart was adherent to the pericardium at the apex, and this to the lung. There were evidences of old adhesions. There were four

ounces of pericardial fluid. The heart near the apex was distinctly yellow. The right ventricle was enormously distended with blood. There was no recent or old valvulitis, but there was old atheromatous thickening. The coronary artery was obstructed on one side, and an injection was made with benzole to determine the point of occlusion. This was found at the margin of the yellow area. This area was found to contain a laminated clot not very adherent. The wall was very soft and friable and oily to the touch. On the outer margin there was a hard white fibroid area, which was evidently an old scar. Microscopic examination showed no healthy fibres in all the surrounding parts. There was much round-cell infiltration and proliferation. In the area which was distinctly fatty the outlines of the fibres were not at all distinct, and it was very friable. The bacteriologic examination of the blood was negative, except that the micrococcus pyogenes albus was found. The liver was granular and cirrhotic, the left lobe being infiltrated.

Saccular aneurism. This occurred in a young colored woman, aged 23 years, who had syphilis. She was found dead. The pericardium was found to be filled with blood and the aneurism ruptured. Death was probably rapid.

Dr. Coplin has always found pericarditis associated with aneurism, and suggests that in cases in which pericarditis occurs, with a history suggesting aneurism, that this occurrence may help in diagnosis.

Dr. Leidy recalled a case of an army officer who died at fifty-three years. He had always had good health, except rheumatic pain, and, a year before death, la grippe. During the war he was thrown from his horse and heard a click in his chest, and had always believed he suffered a heart lesion at that time. Shortly before his death he had pericarditis with marked dyspnœa, but no signs of aneurism. Death was sudden. Autopsy disclosed the pericardium filled with blood from a small aneurism. There was another on the descending aorta and one on the circle of Willis. He did not consider that the fall had anything to do with it.

Dr. Coplin said extensive pleural affusion or pulmonary œdema was the usual cause of death in his cases. *December* 27, 1894.

### 25. *Phlebitis of the ascending vena cava.*

Exhibited by Dr. Thomas S. Kirkbride, Jr.

The case, of which the following is a partial report, was one treated in the women's medical ward of the Pennsylvania Hospital.[1]

As a more complete report will be made at a future time the case is presented to-night without any comment on the various points of interest which it suggests.

E. M., aged 24 years; married; occupation housewife.

Father and mother died of phthisis; otherwise family history is negative.

As a child had measles, scarlet fever, and whooping cough. Otherwise has been fairly healthy until present illness. She has been married five years. Two children died of cholera infantum; two living. No miscarriages.

Was confined four weeks ago. About two weeks previous to confinement face became swollen and she vomited constantly. This condition lasted until after delivery. Labor was natural, and she did very well afterward; was up on the sixth day. On the tenth day she took cold in the back and had severe pain in the back and vomiting. Soon afterward she commenced to cough. Since the onset (eighteen days ago) she has had very frequent chills, followed by profuse sweating and feverishness. Two weeks ago, following a dose of medicine, bowels were freely moved, and since that time she has had profuse diarrhœa, with eight to ten movements daily. Appetite lost.

Vaginal discharge has not been excessive. At present is very slight and not foul-smelling. She thinks she is passing normal amount of urine.

*On admission* respiration 24, pulse 90, temperature 101°.

*Urine* cloudy, reddish-brown, acid, 1020, marked trace of albumin, a few granular and epithelial casts and red blood-corpuscles.

She is a well-formed and nourished woman. Tongue coated white in centre, dry at top and edges. Conjunctiva muddy.

*Pulse.* Rapid, 98 to the minute, and somewhat irregular. Volume is small; tension moderate; artery soft.

*Thorax* well formed; expansion good and equal.

*Lungs.* Resonance clear and breath-sounds good (unless somewhat weak) throughout.

[1] I am indebted to my chief, Dr. Morris Longstreth, for permission to report this case.

*Heart.* Apex indistinctly felt in fifth space 7 cm. to left of middle line. Dulness commences above at fourth rib; on right reaches to left sternal margin. At apex first sound is loud, but short and valvular in character. At aortic and pulmonic areas first sound is weak. Cardiac action is very rapid.

*Abdomen.* Scaphoid; is very tender in hepatic region and in left groin.

*Liver.* Dulness commences at fifth rib, mammary line; just passes costal margin—16½ cm. in all.

*Spleen.* Dulness increased.

*Vaginal examination.* Os lacerated; vaginal mucous membrane rather soft and boggy. There is a slight leucorrhœa. Without, mucous membrane is red and swollen at the meatus.

During the afternoon on day of admission she had five bowel movements which were light in color and liquid.

On admission she was ordered sp. frumenti, ℥ss, every second hour. Bismuth, gr. x; salol, gr. ijss, every fourth hour.

*December* 15. This morning respirations are 50, pulse 122, temperature 103.2°. Bowels moved five times during the night. At 9 A.M. had a chill. Temperature rose from 98° at 6 A.M. to 103.2°. Following the chill she perspired freely. At 5 P.M. had a second chill, half an hour later temperature had risen from 99.8° to 103°. Following the chill she complained of pain in cardiac region.

During the day the stimulants were increased and quinine ordered.

16*th.* At 4 A.M. had a severe chill. Her temperature rose from 98° during the chill to 105° one hour and a half later. At 5.30 A.M. there was a slight rigor. At 3.30 P.M. there was another chill, temperature reaching 103°. She vomited during the chill. There was little or no change in the physical signs, except that tenderness in the hepatic region was more marked.

A vaginal examination was made by Dr. Baldy last night. No evidence of pelvic sepsis was discovered.

*Blood.* Examination for malarial organisms was negative.

*Stools* contained pus-cells and epithelium; negative for amœbæ. The amount of urine was decreased, being about thirty-three ounces in the twenty-four hours. . . .

From the 17th to the 29th there was but little change in her condition. She continued to sweat profusely and had frequent chills. She had great difficulty in retaining food. During this time she gradually lost flesh, but there was no change in the physical signs, except that the tongue became dried and the cardiac action more irregular. The urine

constantly contained albumin, with glandular and epithelial casts and red blood-corpuscles. The diarrhœa was less troublesome.

On the evening of the 26th she complained of severe pain in the right side, extending from the costal margin anteriorly backward to the lumbar region. Over the painful area there was tenderness but no œdema. There was no change in her general condition. On the following day there was rigidity of the muscles in the right flank, but no mass was to be felt, and there was no increased dulness. The pain gradually decreased during the next day.

On January 1, 1895, the only change noted was a roughness of the first sound over the body of the heart. The next day this was more marked, suggesting a friction rub. Pulse was more rapid and irregular, and there was marked pulsation of the vessels of the neck.

On the 4th the urine contained pus-casts, otherwise was as before.

Repeated physical examinations were made without discovering any marked changes in the signs. On the 7th weak breath-sounds and diminished vocal resonance were noted at the base of the right lung posteriorly. Over this area the percussion-note had a peculiar tympanitic quality; no râles were audible. Cardiac dulness was not modified. The first sound at the apex was booming at the end of expiration; impure and soft during inspiration. The roughening of the first sound over the body of the heart was less marked.

*Abdomen* was slightly distended and tympanitic, but soft. Stomach was much distended.

*Liver.* Dulness extended from upper border of the sixth rib to below costal margin (in all 9 cm. in mammillary line).

*Splenic dulness* was obscured by stomach tympany.

From January 1st to 8th, inclusive, the chills were frequent and very severe. Temperature varied between 97° and 105°. Sweating was very profuse and vomiting continued at frequent intervals.

The amount of urine gradually decreased, being about 22 ounces on the 8th, 9th, and 10th. Later it could not be measured, as it, together with the feces, was passed involuntarily.

On the 12th (two days before death) she was somewhat delirious; feet and hands cold. She had become much emaciated.

Urine examination on the morning previous to her death did not differ from that noted above.

*Blood* again negative for malarial organisms. The leucocytes were much increased. She died on the afternoon of the 14th.

The body was removed from the hospital by her friends, and it was

only with a great deal of difficulty that they were persuaded to permit an autopsy at the house.

*Autopsy* twenty hours after death. Body of a woman; much emaciated; rigor mortis present.

*Heart.* Pericardium smooth; no increase of pericardial fluid. Both cavities contain firm chicken-fat clots. Valves are normal, with the exception of one leaflet of the tricuspid, which shows a small deposit of fresh fibrin on the free margin. The endocardium is elsewhere smooth.

*Lungs.* There are firm adhesions on the right side anteriorly and posteriorly. Both lungs are crepitant throughout. The right lung is congested at the base posteriorly. There are no areas of infarction.

*Abdomen.* Peritoneum smooth; no increase of fluid. Intestines were not removed; they appear normal. The stomach is much distended by gas.

*Spleen* is rather enlarged and congested.

*Liver.* Weight 3 pounds 8 ounces. Surface is rather dark and appears congested. On section parenchyma is rather congested.

On removal of the right kidney it was noted that the renal vein was much thickened and that it was the seat of a purulent phlebitis. The kidney weighs 4¼ ounces; it is somewhat soft. The capsule strips easily, leaving a smooth surface, which is decidedly pale. The renal vein and its larger branches are plugged by a thrombus, which, on section, is seen filling the vessels where they lie, between the cortex and medulla. The cut surface is smooth; the cortex is pale in color; its breadth is normal. The left kidney weighs 4½ ounces; it resembles the right, except that there is no evident inflammation of the vein.

The ascending vena cava is throughout its course (except above the level of the hepatic veins) the seat of a purulent phlebitis. The walls of the vessel are much thickened and the surrounding tissues are decidedly infiltrated. The lumen of the vessel is everywhere much diminished by the thrombotic deposits which line the wall and which in places almost completely close it. At the upper limit of the inflammatory process the thrombus projects upward about to the level of the left hepatic vein as a loose channelling process through which the blood from the vena cava must have passed.

The stream from the left renal vein passed along the side of the thrombus which formed the wall for its channel, while the left side of the vena formed the other wall. This latter portion of the vena cava is not inflamed.

The uterus shows apparent subacute metritis and endometritis, with

phlebitis of the peri-uterine veins, which were found distended with clotted blood and with somewhat thickened walls.

The report on the microscopic examination of the various organs will be made at a future date. *January* 24, 1895.

---

26. *Pericarditis with nephritis.*

Exhibited by Dr. W. H. Thomas.

Both cases occurred in the service of Dr. John H. Musser at the Presbyterian Hospital.

Case I.—Girl, aged 17 years, farm hand, with a history of pericardial pain for the last year. One year prior to death had marked œdema (general), lasting for three months, and then entirely disappearing. Chief interest of the autopsy was in the heart and kidneys. The kidneys were considerably contracted; capsules adherent. Surface of section was anæmic, with areas of congestion. Kidneys cut with greater resistance than normal. Microscope showed great excess of connective tissue. Both kidneys together weighed seventy grammes. The pericardium was greatly distended with fluid and showed a universal plastic exudate over both vesical and parietal layers, with numerous bands connecting the two. Pericardium over the left ventricle was three millimetres thick. The heart weighed three hundred and seventy grammes.

This case was interesting as it was a typical example of Weichselbaum's "congenital interstitial kidney," or a "congenital fibrous kidney," with subsequent inflammation.

Case II.—Male, aged 53 years. A case of mixed nephritis with a preponderance of interstitial variety. Each kidney weighed one hundred and fifty grammes. Universal serous exudates. Generalized deposit of fibrin over both layers of pericardium, amounting in places to definite bands, thread-like, and easily broken down. The usual hypertrophy of the left ventricle was present, its wall being twice its usual thickness.

*February*, 14, 1895.

27. *Valvular disease and beginning aneurism of the heart in a boy.*

Exhibited by Dr. ALFRED STENGEL.

J. E., aged 18 years, was a pale, but red-cheeked, boy, below the average size for a boy of his age. He had had acute articular rheumatism at ten and fourteen years, and the latter attack was followed by intermittent fever and heart disease. He came under my observation with pronounced symptoms of aortic regurgitation. The heart was greatly enlarged and palpitations were frequent. He remained under observation a long time and finally died rather suddenly.

The autopsy showed the following conditions: Well-formed boy; skin pale and delicate; the thighs and legs and lower part of abdomen present spots of fading purpuric eruption. The face and neck are bloated in appearance; the lips are blue; there is no œdema. Subcutaneous fat is well preserved—somewhat reddish in color. Muscles slightly pale. Two suggillations, due to mustard poultices, over upper part of the chest.

On opening the body the right lobe of the liver projects 6 cm. below the costal margin; the left lobe 11 cm. below the xiphoid. The lymphatic glands of the anterior mediastinum are somewhat enlarged, and there are a number of ecchymotic spots. The thymus gland has not completely atrophied.

The *pleural* sacs contain some blood-stained serum on both sides.

The *pericardium* is distended on both sides, especially the pouch over the right auricle. The sac contains 85 c.c. of clear serum. The epicardium along the right border and in the auriculo-ventricular groove, anterior and posterior, was marked by numerous distinct ecchymotic spots. There was no pericarditis. The anterior wall of the left ventricle at the apex is decidedly thinned and collapsed below the surrounding surface. On section the left ventricle is found distinctly hypertrophied, 2.5 cm. being the greatest thickness. The cavity is somewhat enlarged and contains masses of dark-red clot. At the apex is found an area of thinning, alluded to before, about 2.5 by 3.5 cm. in extent, in which the muscular substance was almost completely atrophied. The endocardium and epicardium in contact, thickened and sclerotic, white in color. The heart weighs 740 grammes. The wall of the right ventricle is quite sclerotic, especially toward the apex; the outer subpericardial layers being particularly involved. The cavity was similarly distended with clots.

*The valves.* The mitral leaflets were agglutinated and contracted to a narrow funnel. On the auricular surface the leaflets were highly calcareous, on their ventricular surfaces the edges were smooth and rounded,

and at the junction of the leaflets as well as in the substance of the anterior one were found large rounded masses of sclerotic tissue. The chordæ tendineæ were distinctly fibroid, as was the endocardium from the aortic orifice, and extended downward over the undefended space. The aortic valve was thickended, retracted, and agglutinated, but not calcareous.

In the left *auricle*, extending upward from the mitral valve on the posterior wall, the endocardium was highly calcareous, and at one portion there was found a polypoid thrombus closely attached to the roughened surface. The valves of the right side were normal. The tricuspid orifice was greatly distended.

The *liver* was much enlarged, and there appeared on its surface three or four puckered scars. On section there was much sclerotic overgrowth, and the parenchyma was light in color, probably fatty. The weight was 1430 grammes. *February* 28, 1895.

---

28. *Heart from a case of stenocardia.*

Exhibited by Dr. A. O. J. Kelly.

The heart which I present this evening was given me by Dr. O'Mally, who also kindly furnished me with the notes of the case, which are as follows: The patient, J. C., aged 54 years, married, watchman by occupation, was seen for the first time February 18, 1895. He was a remarkably robust appearing man, and had never been ill in his life before. He complained of a "gnawing" pain in the epigastrium and nausea. He was treated symptomatically, and subsequently lost sight of until Monday, February 25th. He was found sitting in a chair and evidently in great pain. He stated that owing to the great intensity of the pain he was compelled to leave work that morning. The pain he described as before, locating it over the epigastrium. During the evening he was seized with a paroxysm of great pain, which he described as radiating from the lower sternal region and præcordia to both shoulders and down the inner and posterior aspect of both arms. He had nausea and vomiting. At about six o'clock the following morning he was seized with another attack, which culminated in his death. At the post-mortem examination everything was found normal except the heart, which showed marked atheroma of the coronary arteries and aortic leaflets, which were evidently insufficient. At no time antemortem was any murmur audible. There is also marked hypertrophy of the left ventricle. *March* 14, 1895.

## V. ORGANS OF RESPIRATION.

### 1. *Pulmonary emphysema with pneumonia.*

Exhibited by Dr. Alfred Stengel.

The specimen exhibited was obtained from the body of an old woman who had been a patient of Dr. Lawrence Wolff, in the German Hospital. There was nothing remarkable in the history or clinical features of the case. The patient had a frank attack of croupous pneumonia affecting the right base. Death occurred about the fifth or sixth day.

At autopsy the right lung was found consolidated and of grayish-red color. The appearances were those of croupous pneumonia in the later stages. At the posterior portion of the upper lobe of the right lung and at various places along the edges of the left lung were seen large bullæ. These lay immediately below the pleura, were extremely thin-walled, and could not be moved from place to place. In several localities the bullæ were in groups, forming a very striking appearance, which might be likened to a cluster of miniature caoutchouc balloons. This was the interesting feature of the specimens—a rather marked instance of bullous emphysema. *December* 14, 1893.

---

### 2. *Apical phthisis with double tubercular pleurisy in an infant.*

Exhibited by Dr. W. E. Hughes.

The child, aged 11 months, had some cough and fever with constipation when first seen. Two days later there was some dyspnœa and dulness, and blowing breathing at the base of the right lung. Left lung normal. Next day the signs on the right were more marked, and there were dulness and blowing breathing in spots over the left lung. Death occurred the next day with marked dyspnœa.

At the autopsy there was a patch of pneumonia at the right apex with a series of small cavities—perhaps, also, some miliary tuberculosis in other parts of the lung. There was fluid in both pleural cavities,

the right being about half-full and containing much lymph, which readily peeled off from the pleural surface. The other organs were normal except that the lymph-glands were enlarged and the spleen anomalous—consisting of five distinct lobules held together by fibrous bands, and with a few accessory spleens along the course of the blood-vessels. I take this for a tubercular pleurisy and report it because of its rarity at this age. *January* 11, 1894.

---

### 3. *Bronchial moulds from a case of bronchitis.*

Exhibited by Dr. S. M. Hamill.

Mrs. F. H. was in good health prior to January, 1892, at which time she had a severe influenza. Since then she has had a persistent bronchitis, occasional dyspnœa, loss of flesh or strength, but at no time any hæmoptysis. There was no evidence of tubercular deposits in the lungs.

On the 18th of last month, while in church, she developed a very severe attack of dyspnœa, during which she fainted. After being removed to her home she had a violent paroxysm of coughing, which resulted in the expulsion of membranous casts of the larger and smaller bronchi. More of the smaller tubes were expelled in long, rounded, stringy masses, distinctly blood-stained and readily unravelled. The casts of the large tubes were much firmer and unfolded spontaneously. Following this attack, which occurred on the 18th, she had three others on the 22d, 23d, and 24th, respectively. Since that time there has been no recurrence of the paroxysms, the cough and dyspnœa have distinctly lessened, and the general condition has progressively improved. Some hours preceding each attack there was marked increase in the dyspnœa and in the force and frequency of the cough. Cyanosis was intense during all the paroxysms, and after the first, which was the most severe, the patient was in a condition of extreme collapse. There was no fever, no evidence of an exudate upon the tonsils, palate, or larynx, or of any intra-laryngeal exudate.

The etiology of fibrinous bronchitis is very indefinite.

This case occurred in a female, which is rather uncommon; the great majority occurring in males. The subject is in the third decade of life, which is the usual period for the development of the condition. She is the subject of chronic bronchitis, with the possibility of error in diagnosis, since the brief previous history we have—cough, loss of flesh, and strength—is suggestive of tuberculosis. Both of these conditions, and

especially the latter, are supposed to bear a causative relation to fibrinous bronchitis. It is probably in the majority of instances associated with pulmonary tuberculosis. It is possible that it and chronic bronchitis may act as predisposing causes to a specific infection, but this yet remains to be developed. It will be observed in the mould which I have softened that it is tough and elastic, that it possesses a free lumen, and that even macroscopically its laminated condition is apparent.

*April* 12, 1894.

---

4. *Specimens from a case of tuberculous pleurisy.*

Exhibited by Dr. F. S. Pearce.

The bloody fluid here shown is from the right pleural cavity of a case which is undoubtedly one of tuberculous pleurisy. The three slides, kindly prepared by Dr. W. S. Carter, are of portions of the lung and pleura of this same right side. The fluid under the microscope shows red blood-cells, leucocytes, endothelial cells, bacteria, and molecular débris. No cancer cells could be detected, even when the specimen was fresh and therefore less disorganized.

These two slides (of the pleura and adjacent lung structure) are stained for the tubercle bacilli, but none could be found, probably from faulty preservation. There are, however, typical tubercles seen throughout, with here and there giant-cells, as shown well in one of these two specimens. No morbid growth can be detected.

The third slide is stained by Weigert's method, and shows no great excess of fibrin formation, hence no acute form of inflammation existed.

I found no tubercle bacilli, after repeated examinations, in the bloody fluid here shown and taken at time of autopsy.

On March 31, 1894, with the assistance of Dr. N. P. Ravenal, 1 c.c. of the fluid was injected into the peritoneal cavity of a guinea-pig at the Hygiene Laboratory of the University. The animal never had a symptom, and was running about in his pen to-day as lively as his fellows never experimented with.

The case occurred in the practice of Dr. E. Pearce, in Ohio. The specimens were from a man 58 years of age, with a negative history as regards tuberculosis among his relatives. He had enjoyed fairly good health all his life, but for the past ten years had led a rather sedentary life. For this reason he became anæmic, caring little for outdoor ex-

ertion. In spite of treatment by drugs, the disregard for hygienic measures gradually reduced him.

About five years ago the patient became the subject of a hydrocele of the left side. This was finally tapped a number of times, always returning, accompanied by general weakness. As soon as the enlargement, or, rather, as soon as his general health was improved, the hydrocele would lessen in size. Finally a seton was introduced, the man gotten out of doors, and overfed. The dropsy of this sac had not reappeared for the past three years.

After a visit to the World's Fair in September, 1893, he caught a heavy cold. He soon began to emaciate and to have creeping pains up the back, with now and then a stitch in the right side. Physical signs soon revealed incipient pleurisy in the right axillary region. Cod-liver oil, iron, with counter-irritants in turn, did not relieve his general or local condition much, and when at all, only for a short time, relapse taking place at the slightest provocation. The system was undermined by *something*, and proved a fair pabulum for further growth of the tubercle bacilli.

In December, 1893, the exudate in the right pleural cavity was becoming so great as to produce compression of the lung and extreme dyspnœa.

In January, 1894, the patient's appetite had almost failed him. Cod-liver oil, inunctions, and stimulants tided him over for a time. On January 24th paracentesis thoracis was done in the right axillary region, 1½ ounces of light amber fluid being withdrawn. This gave no relief of any moment. Cyanosis and orthopnœa returning, he was again aspirated January 31st, 14½ ounces of the same colored serous fluid being withdrawn, and this produced marked relief of the sense of chest constriction. Small amounts of this amber-colored fluid were withdrawn from time to time as absolute mechanical compression demanded. There was an "unproductive cough;" little or no expectoration.

On February 4th it was noticed the fluid had a shade of red. The trocar of the aspirating needle would push the lung about as a soggy mass hanging in the chest cavity. There was now a constant feeling of restriction about the abdomen.

During this month the patient regained a little more strength, the fluid filling in less rapidly. At the end of February, however, the left chest began to become the seat of this leakage from the serous membrane. A consultation was had; the surgeon thought of possible malignant growth. Nothing further was done surgically. The temperature had run along at from 100° to 102°, pulse became progressively weaker, and

he died March 11th. In all over one and one-half gallons of, first, amber, then bloody, fluid were reluctantly removed on account of the danger of death from dyspnœa during January, February, and March.

Autopsy revealed the following: Extremely emaciated body. On opening the thorax there was found about one quart of this bloody fluid. Right lung was dark, shrunken, and hepatized. It contained no cavity, and was flattened out in the upper posterior part of the right chest, being there somewhat adherent to the costal pleura. No tubercular deposit or new growth could be seen by the naked eye on section of the right lung. The whole section of the pleura (pulmonary and costal) presented a pink color, more marked in the region of the contracted lung. The pleura had many rounded miliary deposits on it. The heart was normal. Pericardium contained two ounces of serous fluid. The left lung was partly consolidated toward the base; no new growth here or in left pleura. No effusion was found in the peritoneal cavity, but the hepatic peritoneum and many other points on the intestine and parietal walls were jutted over with these small miliary tubercles, similar to those found on the pleura. There were few abdominal adhesions, and the peritoneum was dull red in color, indicating chronic inflammation. The liver was about normal in size. Spleen normal apparently. Gall-bladder contained one ounce of bile; no stones.

The history of this case, the color of the fluid first drawn (serum; later, bloody), the "unproductive cough," the slight hectic (though no pus ever developed), were all suspicious of tubercular disease. There was of course some reason to think of carcinoma.

With the result of the autopsy and microscopic findings, and taking into account the hydrocele of some years past, the case looks like the classification Osler gives in his *Shattuck Lecture on Tuberculous Pleurisy* as "General Serous Membrane Tuberculosis." Confirmation is also here given, as Musser well points out in a paper entitled "Notes on Tuberculous Pleurisy," published in the *International Medical Magazine* for February, 1894, that the "examination of exudate is rarely satisfactory." It must be that the bacilli act in a very slow manner, and are thrown off in the pleural effusions. *May* 10, 1894.

### 5. *Carcinoma of the larynx.*

Exhibited by Dr. M. H. Fussell.

Michael X. was a patient of Dr. James Sibbald, of Wissahickon, to whose kindness I owe the privilege of presenting this specimen. One year before death a growth appeared in the glands of the left side of the neck. This growth was apparently partly inflammatory in character, as it periodically enlarged and partially disappeared, never completely disappearing, however. The patient gradually lost his flesh as the growth enlarged. Urgent dyspnœa developed, and laryngeal examination demonstrated a mass almost entirely occluding the chink of the glottis. A tracheotomy was urged, but refused by the patient and family.

Post-mortem twenty-four hours after death. There is a mass on the left side of the neck as large as a goose-egg, involving the glands in that region. The mass presses directly upon the larynx. The larynx is highly calcified, requiring the use of a saw to separate it in the posterior line. The chink of the glottis is entirely obliterated, partly by pressure of the growth on the side and partly from an ulcerating growth, involving the left ary-epiglottic fold. All of the tissues on the left side between the tip of the hyoid bone and the arytenoid cartilage are the seat of ulcerations. The ary-epiglottic fold is almost entirely destroyed, and it is the edge of this ulcerated tissue which forms the mass occluding the glottis. The ulceration extends directly to the base of the epiglottis and involves this to a slight extent. There is a small abscess-cavity, formed by the extension downward of this ulceration to the middle of the thyroid cartilage. Examination of the growth shows a carcinomatous tissue, both in the glands and the surrounding tissue. *May* 25, 1894.

---

### 6. *Encysted and organized empyema following a wound.*

Exhibited by Dr. H. W. Cattell.

Several years before S. H., colored, aged 49 years, had received a penetrating wound, situated near the sternum. It was supposed at the time that the thoracic cavity had been entered.

At the post-mortem the right lung was seen to be somewhat emphysematous, and with no adhesions except posteriorly near the apex. On section, it is pale and congested, though consolidated at apex. An abundant frothy matter exudes, calcareous masses are scattered through it; the bronchial glands are enlarged, bronchi dilated. Weight 440 grammes. The head is drawn toward the left. The left lung is in a condition of collapse, no crepitation being felt. It is pushed toward the median line by the thickened visceral and parietal pleura, which is fairly well filled with an organized material. The new membrane extends from clavicle to diaphragm, and is in intimate relation with the ribs, and can only be torn away with the greatest difficulty. On section the left lung is found to be carnified, and portions cut off sink when dropped in water. Weight 480 grammes. There is a small cavity at apex.

On further dissection of the mass in the left chest it is seen that the apex is well packed with old inflammatory material. No bloodvessels were found diseased or injured, or in any way connected with the mass, which was removed entire by careful dissection and was found to be filled with a soft, organizing clot. The internal surface of the new membrane is inflamed—what is really a well-organized pyogenic membrane—showing the presence of numerous new bloodvessels which are in intimate relation with the internal material above described. This does not occupy the entire cavity, is very soft, resembling French bread in texture. The indentations of the ribs and the marking of the intercostal spaces are well shown.

In this case the left common carotid is seen to come off from the base of the innominate and passes directly across, in order to assume its normal position. There is a small extra artery running up into the neck (not traced out), coming off close to the left subclavian and running behind it. The vertebral arteries forming the basilar are extremely small. *June* 14, 1894.

---

7. *Laryngeal perichondritis as a complication of typhoid fever.*

Exhibited by Dr. M. H. Fussell.

A very incomplete and cursory glance at the literature of this subject seems to show the extreme rarity in this country at least of this complication.

In 2000 autopsies on fatal cases of typhoid in the Munich Hospital reported in the *Münchener medicinische Wochenschrift* for 1891, *fifteen* cases of laryngeal perichondritis were found. Osler states in his work on *Practice of Medicine* that he has seen two cases of this disease. I have not met personally any gentleman who has seen the complication.

I saw the person from whom the specimen was removed in consultation with my friend, Dr. A. H. Melleuh, of Roxborough.

The history was briefly as follows: The patient, a man aged 30 years, was seized with what proved to be an unusually severe attack of typhoid about December 1, 1894. When he was first seen by the doctor he was hoarse, and soon developed a consolidation of one lobe of the lung. After five weeks the temperature fell to normal. About six days after this a friend brought to the patient an apple, which he ate whole, core and all. Almost immediately he was seized with a severe attack of coughing and signs of laryngeal stenosis.

I saw him on the third day afterward. The patient was suffering extremely from stenosis of the larynx and begged for relief. Examinations of the larynx showed nothing but an œdema; no ulcerations in any part. The region of the thyroid cartilage was swollen and extremely painful to the touch. The urine was normal. The lungs showed no signs of disease. Examination of the sputum showed an absence of tubercle bacilli.

A diagnosis of perichondritis was made, and tracheotomy was advised but refused, and a blister was placed over the larynx.

Two days afterward I saw the patient again. The œdema of the larynx had largely disappeared, but the stenosis was quite as great as on the former occasion. The laryngoscope showed a pale mucous membrane with a decided narrowing *below* the cords. The tenderness over the larynx still existed. The diagnosis seemed to be certainly correct, and a tracheotomy was again urged but refused. The patient died on the seventh day after the begining of the symptoms of stenosis of the larynx.

At the autopsy the left lung was found to be the seat of an old pleurisy. Lungs crepitant throughout. Heart normal. Kidneys normal. The intestines showed healed typhoid ulcers, as here shown.

The larynx was removed entire. The interior was filled with a frothy muco-purulent matter; no ulceration of the cords. On the left side, just at the junction of the false and true cords, there was a small mucous polyp the size of a pea.

Section through the *posterior* angle of the thyroid cartilage showed a large perichondrial abscess filled with pus. The cartilage was necrosed.

The abscess extended about one-half of an inch on each side of the posterior median line. The anterior portion of the thyroid cartilage and the neighboring cartilages appeared normal.

Unquestionably a tracheotomy would have saved the man's life, as there were positively no general symptoms of infection, but death occurred solely from the stenosis. *January* 24, 1895.

## VI. GENITO-URINARY SYSTEM.

### 1. *Enlarged prostate with cystitis and nephritis.*

Exhibited by Dr. Carter.

W. W., aged 58 years, was admitted September 4, 1893. No family or previous history taken except that he had had trouble in urinating for four or five years, and the present tumor for about three months, during which time he had been losing flesh and strength rapidly.

He came to the hospital with a supposed abdominal tumor, which extended about two inches above and to the right of the umbilicus. Upon examination this was diagnosed as a distended bladder. Some difficulty was experienced in passing a catheter, due to enlarged prostate, but finally an English one with a stilette was introduced, with the result of drawing off about thirty-five ounces of urine and immediately very much diminishing the size of the tumor. He was retained in the hospital and his urine drawn three times a day. On the third day the English catheter was not necessary, and from that time a soft-rubber one was used. About the fourth day the urine became bloody, and the next day he began to complain of severe pain, almost altogether confined to his penis. The fifth day there was less blood, but on the sixth it returned and became more and more marked. The pain continued all the time, but worse at intervals. The urine was markedly ammoniacal, and contained much blood and mucus and some pus and albumin, but it was not possible to find any tube-casts. The blood from the first was well mixed with all the urine passed. On the evening of September 16th, the thirteenth day in the hospital, he developed a slight hiccough, which in spite of treatment became progressively worse, and was the first symptom of the oncoming uræmia. It lasted until death. Up to the 16th he had been passing large quantities of urine, usually about sixty ounces; but on the 16th he only passed about twenty ounces, and on the 17th only eight ounces, and in the last twenty-four hours only two ounces. He vomited occasionally during the first ten days, but on the last two days he could take no food at all and vomited almost constantly. His pulse was very weak and irregular at times. He had no

convulsions, and died in a comatose condition about 2.30 P.M. on September 18, 1893.

*Post mortem.* Body of an old man, six feet tall, weighing about 160 pounds. No scars, no discolorations. Autopsy three hours after death.

*Thorax.* Few pleural adhesions, posteriorly at the base of right lung. At the apex of both lungs there are a few healed tubercles, with considerable fibrous change and puckering of the lung-substance. There is some hypostatic congestion in lower lobes of both lungs posteriorly. There is considerable coal-pigment throughout the lungs.

*Heart.* Weighs 350 grammes, with blood in cavities. Heart not opened, at the request of one of the visiting physicians. Considerable deposit of fat beneath the pericardium. Pericardium normal. No patches or adhesions. Amount of fluid normal.

*Abdomen.* The bladder extends up about 10 cm. above the symphisis pubis. The bladder is sacculated at the upper part, there being a large pouch about 8 cm. in diameter and 4 cm. in depth. The organ is bound down by dense adhesions anteriorly at the lower part of the organ. The bladder can only be separated from its attachments posteriorly with great difficulty. In handling it a quantity of blood and mucus escaped from the penis. The bladder contained about a litre of dark, bloody urine, of very foul odor, and containing numerous clots and masses of mucus. Its wall is very much thickened, measuring from 1 to 2 cm. The pouch described above has a much thinner wall, only 5 cm. in thickness. Where this pouch communicated with the bladder there is a distinct ridge. On the posterior surface in the upper third of the bladder there are four small openings about 1 to 5 cm. in diameter; these open into small sacs, the walls of which are formed by the thickened peritoneum. Over the entire inner surface there are numerous hemorrhages, and the surface is very irregular on the posterior wall, so that it presents an appearance not very unlike the surface of a placenta. The bladder and the prostate weigh 480 grammes.

*Kidneys.* Left kidney weighs 105 grammes. Surface irregular and a number of small cysts on the surface. Capsule is very adherent and the cortex very much diminished, measuring 3 to 5 mm. There is a large cyst in one pyramid. There is considerable uratic deposit at the bases of the pyramids, and there are four small hemorrhages in the pyramids. The pelvis is considerably dilated and the wall thickened. The ureter is dilated throughout its whole length. The inner surface of the pelvis and ureter presents a large number of hemorrhages of all sizes in the mucous membrane. When the ureter was cut across a large clot escaped, being a mould of the ureter.

*Right kidney.* Weighed 160 grammes; surface irregular; capsule strips easier; cortex very pale, and, as a rule, is 6 to 8 mm. thick, although it is thin in places. The pyramids appear normal. The pelvis is slightly dilated, and also the upper part of the ureter. There is some inflammation with small hemorrhages, but not as severe as in the left.

*Supra-renal* bodies normal.

*Spleen* weighed 140 grammes; pulp normal; capsule slightly thickened.

*Stomach* considerably dilated, and wall seems of about normal thickness.

*Intestines* not opened, but appear normal.

*Liver* weighed 1500 grammes; color about normal. The central vein stands out rather prominently. Consistence somewhat increased.

*Gall-bladder* is dilated. Contained no stones.

*Bile-duct* patulous. *October* 12, 1893.

---

## 2. *Cancer of the breast.*

Exhibited by Dr. F. S. Pearce.

The tumor here presented I removed in the practice of Dr. E. Pearce, of Steubenville, Ohio, on October 19, 1893, one week ago, and it is a fungus mass involving the entire right mammary gland and surrounding tissues.

The patient from whom the tumor was removed is a little, spare woman, 53 years of age, married and having six children, the oldest about 27 years, the youngest 6 years of age.

There is a history of cancer having existed in the breast of an aunt, while a sister, I am told, has an annoying, painful, but small, ulcerating growth of the breast.

The patient says since before she was 20 years of age she has had a small growth above the nipple in the right breast; that this was painless and movable *at first;* after marriage and nursing her first child the enlargement began to slowly increase, but without giving any inconvenience, no physician being consulted. Went on in perfect health, but never nursed again from her right breast for fear of causing the tumor to enlarge more rapidly. About ten years ago she had a sense of uneasiness about the tumor (now the size of a small walnut) when tightening

her clothing or when lying on the right side. Now consulted a travelling doctor, who "burned it out," and she had no more disturbance from it for three or four years, then at the site of cauterization the growth lightened up anew. For the past three years it has been enlarging very perceptibly, giving at times some twinges of pain. Patient thinks she bruised the tumor at that time (three years ago) in leaning over a barrel. Dr. E. Pearce saw the growth July 1, 1893, after the skin had ulcerated above the nipple, the nipple itself being well retracted. The tumor was not adherent to the chest-walls, and no axillary, cervical, or other enlarged lymph glands could be found. Operation was then advised. For the past three months there has been considerable discharge, pain has been more severe, and the patient, while going about as usual, has lost in appetite and general health. Uterus, lungs, and other organs normal.

At date of operation the breast seemed quite free from attachments, no enlarged lymphatic glands could be detected, and there were no large veins visible on the surface. The skin, of course, was firmly adherent over the gland.

Very little hemorrhage took place during the operation, the entire gland and affected fatty tissue about being removed, and the patient is now making a good recovery.

The tumor, with skin attached, retracted nipple, and fungoid ulcerating masses above it, seem to have undergone a mucoid degeneration, a watery solution of some of the contents being precipitated by acetic acid, and is more easily broken up now from some unavoidable decomposition having taken place.

A frozen section under the microscope, kindly furnished me by Dr. Cattell, gives evidence of round-cell infiltration from the ulcerated process and fibrous tissue-like fibroma, but no cancer cells are detected.

From a clinical point of view we were led to believe this at first was a simple œdema, later assuming a malignant type.

It seemed isolated so well, with no apparent glandular involvement, that the hope was expressed of a longer respite than usual from malignant disease.

More time is required for the preparation of paraffin sections and from different parts of the growth to show the true pathological condition, which to the naked eye and from the clinical symptoms has led to the diagnosis of cancer.

Dr. McFarland said that upon examination of the microscopic section he had thought of sarcoma, but the age (54) and the place from which the tumor was removed accounted for the sarcomatous appearance. He

thought the appearance not myxomatous, though the microchemical examination seemed to show myxoma.

Dr. Scott had made microchemical tests and found reaction with alcohol and acetic acid. He therefore thought it mucoid. From the clinical history it would seem to have been at first benign and subsequently malignant. *October* 26, 1893.

---

### 3. *Fibroid tumors of the uterus.*

Exhibited by Dr. J. M. Baldy.

The series of tumors I present to you to-night are unusual in that they have been removed from the living body, while the other specimens you have seen have been removed post-mortem. Clinically we recognize two varieties of this class of neoplasm—the hard variety and the soft variety. The hard variety is usually called fibroid, while the soft is known as myoma, or, more correctly speaking, soft myoma, as both varieties are in reality myomata. The soft myomata, two specimens of which I show you, are comparatively rare and are not infrequently mistaken for cysts or pregnant uteri. The first one I removed I had taken from the room in order that I might examine it alone, so much afraid was I that it contained a fœtus and that I had made a terrible mistake in my diagnosis. It will be noted that the appendages in both cases are healthy and that there have been no adhesions. Such is the case with another specimen of the same kind which I have in my possession. These three are the only specimens of the soft variety that I have come across in over fifty operations for this disease. This proportion about represents the relative frequency of the two varieties.

The rest of the dozen or so specimens before you are of the hard variety of myomata, and illustrate some interesting points both as to the complications which usually accompany this disease and as to the variation in the tumors of their position. This first specimen shows the uterine cavity cut open, with a tumor as large as the fist protruding into its cavity; it represents very beautifully the variety known as submucous. The interstitial variety is shown in these two specimens. All the rest are of the subperitoneal variety. Again, these specimens show about the relative frequency of the three varieties—submucous, interstitial, and subperitoneal—the latter being far the most frequent. Of these subperitoneal tumors you will note that the vast majority are

made up of several nodules, some of which are pedunculated. This, again, is usual and what we expect to find. The large, solid tumor I hold up represents that variety of the tumor which grows into the connective tissue of the broad ligament instead of into the open peritoneal cavity. It is the variety of tumor which is the terror of the surgeon. The present specimen I attempted to remove over two years ago, and ended the operation as an exploratory one, fearing to kill the patient on the table if I attempted the removal of the growth. After over two years' more suffering the woman returned and demanded another trial. An increased experience and a more perfect technique carried us safely through the ordeal. Here is the tumor, and the patient is a well and happy woman. You will note that but a very small portion of the tumor is covered by peritoneum. The upper surface was the only part which was not buried in connective tissue.

There are two features worthy of note in these tumors before you. A number of them show adhesions—adhesions which existed between the tumor and the intestines, the omentum, and the abdominal walls. This complication is not so very common as writers would make us believe, and yet when it does occur it is an exceedingly annoying and dangerous complication when it comes to an operation. In almost every specimen before you it will be seen that the appendages are diseased to a greater or less extent. Many of the Fallopian tubes are distended with fluid. It is noticeable that not one of these enlarged and distended tubes is what is known as pyosalpinx or pus-tubes, and, as a matter of fact, this condition is rare. On the other hand, the fluid-contents are mostly serum or fluid-blood. The ovaries are mostly enormously enlarged, but only in rare cases are they cystic. It is clear that the disease of the appendages is brought about by the same influences, whatever they are, which have caused the growth of the tumor. The cause is plainly not a septic or specific injection coming from the uterine cavity or the vagina. Were that so, the tubal contents would be purulent in a large proportion of cases. Many times would the ovaries contain pus and adhesions of the appendages, and tumors would occur with much greater frequency than is now the case. As a matter of fact, adhesions are relatively rare, as is also pus.

I do not wish to intrude upon your time with any discussion of the surgical side of the subject; but in view of the fact that you have been recently told that the extra-peritoneal treatment of the stump in the removal of these tumors is the only proper one to adopt, and that the intra-peritoneal treatment has an enormous mortality (20 per cent., I think), and should never be used, I wish to put on record in our *Trans-*

*actions*, side by side with that statement, these facts: that all of these tumors have been removed by me by the intra-peritoneal method of treating the stump; that in every case the woman recovered from the operation; that in a series of over twenty-five hysterectomies done in this way but one death has occurred; that other operators have had equally as good results. I challenge the world to produce as good or better results by any method. With the exception of two or three men, operators the world over have long since catalogued the extra-peritoneal method of treating the stump as the method of the amateur.

*November* 9, 1893.

---

4. *Abdominal tumor, probably of ovarian origin.*

Exhibited by Dr. J. M. Swan.

S. Y., aged 48 years, was admitted to the gynecological ward of the Presbyterian Hospital, August 15, 1892. The only point of interest in the family history is the death of her father at 61 years from erysipelas. When admitted she had been ailing four months, having noticed first a tightness and fulness in the abdomen, with some swelling. This confined her to her room, but she was able to walk about. The swelling increased in size, and was painless. Menopause started at about the time the abdominal enlargement began.

She was operated on on August 23, 1892, by Dr. G. E. Shoemaker, eight days after admission. Then the parietal peritoneum was smooth at the site of incision and of normal thickness, though somewhat too vascular. No nodules felt. The small intestine was hardened and stiffened and contracted, the loops tightly adherent together. There were rough, cheesy nodules situated in these adhesions. The matting of the intestines was marked to the left. There was an appearance on the surface of the small intestine like granulation tissue. A small distended sac in the false pelvis appeared to be the colon surrounded by the adherent small intestine, distended with gas. Uterus large, tubes and ovaries small, peritoneum covering them roughened. On December 7th a second operation was performed, and Drs. Willard and Shoemaker decided that the disease was malignant. They found there two large cystic masses on each side, firmly adherent to the abdominal wall, and smaller hard masses scattered through the omentum. This operation was recovered from, and the patient spent the remainder of her life

in the wards, a hopeless invalid. During this time paracentesis abdominalis was performed about every three months. In April, 1893, 10½ pints of fluid were removed by Dr. Weiser, "clear and frothy." In July, 14 pints of "clear, straw-colored serum" were withdrawn by Dr. Edwards. In October, 8 pints of a "clear yellow fluid" were withdrawn by Dr. Keller, and the aspirator wound allowed the escape of similar fluid for eleven hours. On October 31st she developed a facial erysipelas, and was transferred to the medical ward. At 8 P.M. on November 3d her temperature rose to 104.8°, and she died the following morning.

*Autopsy.* The body of a very much emaciated white woman, with an enlarged abdomen, presenting evidences of an intra-abdominal growth. Face about the alæ of the nose the seat of a scaly desquamation; eyelids œdematous. Post-mortem rigidity not at all shown. Post-mortem lividity marked.

On opening the abdominal cavity there was seen in the right and left iliac and hypogastric regions, extending into the right and left lumbar and umbilical regions, a large tumor. The tumor was partially cystic and partially of considerable consistency. On the left side were two areas presenting fluctuation and dark discoloration on the surface, and on the right one large cyst, dark in color, resembling a distended cæcum in shape. The cæcum, ascending colon, and sigmoid flexure of the colon, together with the rectum, were adherent to the growth, and so involved in the mass as not to be distinguishable. The lower portion of the ileum was adherent to the wall of the tumor. The uterus and ovaries were involved in the growth. Weight of tumor and intestines 3750 grammes. The intestines, other than those portions already mentioned, were bound to each other and to the abdominal parietes by bands of lymph, some recent, some old, and in these bands of lymph were noticed a large number of hardened nodules of varying size, from that of a pea to that of a pigeon's egg, and many were the seat of calcareous deposit. Between the edge of the liver and the transverse colon was a well-defined space, measuring about 8 cm. In this space could be seen the contracted stomach and the first portion of the duodenum and the head of the pancreas. This space contained the larger part of the ascitic fluid from the abdomen, which measured 450 c.c.

The diaphragm reached to the fifth rib on the right side and to the sixth on the left.

The pericardium was adherent to the pleura by fibrous bands. The mitral leaflets were the seat of a sclerotic endocarditis. The aortic valves presented atheromatous patches with calcareous deposit, and

there were several atheromatous ulcers in the beginning of the aorta. Heart weighed 215 grammes. The left pleural cavity contained 350 c.c. of a hemorrhagic fluid. The right, 1450 c.c. of a similar fluid, and there were several bands of soft, fibrous exudate connecting the visceral and diaphragmatic pleuræ. In these bands and on the diaphragmatic pleura, particularly, were numerous calcareous nodules exactly similar to those described in the abdominal cavity. Both lungs were small, anæmic, and emphysematous. Weight of left 350 grammes, right 370 grammes. The left kidney was large, pale; cortex almost entirely obliterated; capsule adherent. There were three pockets containing calculi, white, not larger than cherry-stones, and some very small; weight 140 grammes. The right kidney was small, pale; capsule adherent; cortex nearly destroyed; evidences of increased connective tissue. Weight 70 grammes. Both kidneys were the seat of pyelitis.

Spleen presented increased connective tissue. Liver was rather small, anæmic, tissue friable, and there were some evidences of increase of connective tissue and some areas of yellowish discoloration. On the diaphragmatic surface were several pits resembling smallpox scars, surrounded by additional layers of plastic lymph. On the diaphragm over these pits were calcareous nodules, similar to those described above. Weight, 1320 grammes. There was no tubercular focus in either lung.

*November* 9, 1893.

---

5. *Series of ovarian and uterine specimens.*

Exhibited by Dr. G. E. Hughes for Dr. Joseph Price.

The first specimen I have to present is that of a very common disease, pyosalpinx. The disease in this case was post-puerperal in nature. She had an angry attack of pelvic peritonitis immediately after delivery, and was very ill for many weeks. Her convalescence was tedious, and she has remained an invalid to the present time. The tubes are charged with pus; the ovaries and tubes were fixed by general adhesion, necessitating a complete enucleation. The patient is now convalescent. Irrigation and drainage were practised.

The second specimen is that of an ovarian sarcoma of unusual size; the pedicle was long; the tumor high up and enveloped by adherent omentum and small bowel. She was also suffering from intrauterine

malignancy, adenoid in character, necessitating the extirpation of the uterus, which I now present as a unique specimen. Careful microscopical examinations had been made by competent pathologists. The ovarian sarcoma had been mistaken for a uterine fibroid, and its removal refused by a number of competent operators at home and abroad; operative interference was refused, probably on account of the patient's size, her weight being nearly 300 pounds. The operation was difficult and trying. She is doing well, and is now convalescent.

The third specimen is also common, but seems to be on the increase, as we now find larger numbers of women suffering from fibroids of the uterus than we did a few years ago. Gynecologists at home and abroad seem to recognize that fact. The specimen is that of a multinodular fibroid; the small tumors all seem to be drifting toward the cavity of the uterus and are easily enucleated; at that point you see clusters of small fibroids surrounding the uterine cavity. She suffered chiefly from pressure, not from hemorrhage or discharge.

The fourth specimen is quite similar in nature or a myofibroma; some small fibroids studding the uterus. The bulk of the tumor is myomatous in nature. The unique feature of the specimen is the huge pus-tube coiled up on its right side and beneath it in the pelvis. The tumor and diseased appendages were firmly fixed in the pelvic basin by adhesions. Four years ago Dr. Price urged the removal of the diseased appendages; at that time the pus-tube was recognized, also the general adhesions; the uterus was normal in size. This case demonstrates most beautifully the causal relation tubal and ovarian disease bears to new growths in the uterus. It is quite common to find puriform or inflammatory trouble of the appendages complicating hard tumors of the uterus. This woman was greatly emaciated and had been a long sufferer, bleeding more than half the time. Drainage was necessary in this case. Here again we have an opportunity of demonstrating the absence of so-called endometritis, so much looked for and so much treated and fancied as existing in about all women. After removal of the uterus for fibroids or for cancer Dr. Price is in the habit of laying the uterus open for the purpose of demonstrating the absence of such a disease or an unhealthy condition calling for the curette or intrauterine treatment. *November* 9, 1893.

### 6. *Chronic nephritis with great aortic stenosis.*

Exhibited by Dr. Gibbons.

Owing to the kindness of Dr. Meigs, my attending chief at the Pennsylvania Hospital, and to the courtesy of the Society, I am allowed the privilege of showing this evening some specimens which, when considered separately or together, are of considerable interest. I regret that the organs are not fresh, but the alcohol in which they have been kept has at least not changed the interesting condition of the heart-valves, and I shall ask you to take on faith what I have to say of some of the appearances noted at the autopsy.

The patient from whose body the specimens were obtained was admitted to the Woman's Medical Ward of the Pennsylvania Hospital, October 19, 1893, and died October 23d, thus remaining under observation for only four days. The history of the patient is as follows:

A. S., aged between 50 and 60 years, white, single, born in Pennsylvania, cook.

*Family history* could not be obtained. (Patient on admission in no condition to give us any history of her illness prior to her admission, and that which we have was obtained from the lady for whom she worked.)

*Personal history.* Patient is said to have been "scrofulous." Was in hospital fifteen or twenty years ago, when she suffered from "nervousness," only remaining in the house one day. Excepting this no history of illness other than the present could be obtained. A fact in this woman's personal history, which renders the specimens shown of much greater interest, is that she was always a woman of temperate habits. For many years she has suffered with periodical attacks of insomnia, and it was then only that she was ever known to take alcohol, and at such times it was given in form of whiskey in tablespoonful doses by the lady for whom she worked. This lady tells me she does not believe the patient ever spent twenty-five cents for whiskey in her whole life; certainly it would have been known had she indulged even to a moderate degree, for she was the servant in a small family for twenty years.

*Present illness* dates back about four years, when patient became unfit for work for short periods, but not until two years ago could any history be obtained of heart-trouble, and not until one year ago had œdema of any part of the body been noticed. About one year ago patient was

incapaciated by swelling of feet and legs, complicated with a large leg ulcer. This condition was relieved, however, and patient was able to go about again. The mental faculties during all this time were noticed to be failing. Friends were told by the family physician that the patient was suffering from an organic heart-lesion. Last spring was again compelled to go to bed by a return of swelling in limbs and ascites. After some weeks became better, but remained weak, and again went to bed a few weeks before admission.

*On admission* patient's condition was very poor, pulse weak, and respiration shallow. Quite restless, requiring constant watching to keep her in bed; was, however, easily managed. Talked at random and a great deal about money, but was easily kept in rational conversation for short periods. Temperature 98°; pulse 80; respiration 30. Superficial examination showed general œdema of hands, feet, and face. Abdomen large and seems to contain fluid; walls œdematous.

*Urine.* Diminished amount, some sediment, specific gravity 1022, acid, no albumin, no sugar, no casts.

*Treatment.* Tr. digitalis, gtt. x, and Bash. mist., f℥ij, alternating two hours.

A day or two after admission Dr. Meigs made the following notes:

*Heart.* Beat is diffuse, wavy, perceptible over largely increased area, heaving, but tends to be feeble. At apex both sounds distinct and tend to be thumping, and a blowing systolic murmur audible all over cardiac area. Veins in neck are lightly distended; lips and skin cyanotic. Everywhere œdematous. Abdomen is large, and there is fluctuation. Breathing very shallow and labored; seems to be a urinous odor to breath.

*Inferences.* Heart too weak for formation of accurate opinion; organ much enlarged. Lungs not examined on account of patient's weak condition, but there must be either great obstruction or hydrothorax. Kidney condition is doubtful. The day after these notes were made patient's condition became much worse, and on the fourth day after admission she died.

*Autopsy.* Twenty-four hours after death. Body generally œdematous, as mentioned in ante-mortem notes.

*Heart.* Enormously enlarged, universally adherent to pericardium. Pericardial sac completely obliterated; adhesions firm, but not fibroid. Weight 9 ounces; walls rather thin. Valves of right side normal, also the mitral. Aortic opening consists of a narrow slit, measuring about one-half to three-quarters of an inch in length and less than one-eighth of an inch in width; the valves exceedingly rigid, thickened, and very chalky.

*Lungs.* Right pleural sac contained quite a large amount of serous fluid. Left lung universally adherent; right lung adherent posteriorly. Lungs generally congested, indurated, and leathery; a portion from base sinks in water. Upper part of lung crepitant, but base non-crepitant.

*Liver.* Much contracted; weighed 2 pounds 2 ounces. Surface rough, visible fibroid bands running irregularly over it. On section yellowish in color, very tough. Capsule difficult to remove.

*Spleen.* Slightly smaller than natural, shortened. Capsule white and very thick, covered with spots of fibroid thickening. On section exceedingly hard and fibrous. Weight 7½ ounces.

*Kidneys.* Weighed 4 ounces each. Appearance is of but little reduction in size. Hilus is distended with fat. On section renal tissue was evidently reduced in amount, it looking as if there had been extensive cellular infiltration. The fat in hilus greatly increased so that the calices extended as tubes as much as two inches from summit of cone to exit. A few chalky deposits.

Abdominal cavity contained large amount of serous fluid.

The interesting features of this case, as can be seen, are: Far advanced aortic disease, with rest of valves healthy, a cirrhotic liver in a temperate person, and, last, the interesting kidney condition.

*November* 9, 1893.

---

### 7. *Alveolar sarcoma of the kidney.*

Exhibited by Dr. W. E. Hughes.

He had seen the patient two years before, in consequence of hemorrhages from the stomach. At the same time there was in the left renal region a tumor which was evidently a floating kidney and about the size of a normal kidney. There was a strong family history of cancer, one sister having died of cancer of the breast, another of cancer of the uterus, and a brother of rodent ulcer. About a year ago the tumor began to grow, and she began to have pains radiating down the left thigh, which was flexed. Shortly before death she had hæmaturia, the blood being intimately mixed with the urine. There was then a large mass in the left renal region which was fixed, painful, and tender. In addition she had dyspnœa due to an effusion in the right pleural cavity. This was tapped later, and a bloody-fluid drawn off. After this febrile symptoms appeared, and the patient became uræmic.

Upon post-mortem examination there was found a cicatrix near the pylorus of the stomach. The left kidney was much enlarged, and showed little of the kidney structure. There was a large cyst in the lower part, and the remainder was a large growth, apparently a cancer. There were also some metastatic growths in the retroperitoneal lymph-glands. There was almost complete invasion of the right pleural cavity, and complete obliteration of it. There were several nodules in the left pleura. *November* 23, 1893.

---

8. *A kidney showing primary tuberculosis, from an infant of seven months.*

Exhibited by Dr. S. M. Hamill.

The clinical history of the case from which I obtained this interesting specimen, which it is my privilege to show the Society this evening, is of sufficient value to admit of a brief report:

K. N., aged 7 months, came under my care October 2, 1893.

Family history excellent. No evidence of tuberculosis or any chronic wasting disease in any branch of family.

The health of the infant since birth has been good; was always very pale. Early in September had an attack of diarrhœa and vomiting, lasting over a period of twenty-four hours. Two weeks later, one week before she was brought to me, she developed a diarrhœa. Green stools containing mucus and flakes; sour odor; five to six stools in the twenty-four hours. The child was a bit fretful, but did not develop any marked symptoms until after six days.

Then the temperature became suddenly elevated and the child very restless. It was at this time I made my first examination, and found the following condition: A well-developed, full in flesh, rather flabby, very anæmic infant. The mucous membranes were almost bloodless, there had been no vomiting, had taken nourishment well, had had no convulsions, no cough, no difficulty in swallowing, cry was not hoarse; some pain when bowels were moved or urine voided. Abdomen not much distended, no tenderness. Examination of heart and lungs negative; respiration regular, 30 per minute; pulse 168 per minute; temperature 104.6° F.; urine voided freely. Two days later the abdomen was more distended and tympanitic, and there seemed some special tenderness in the lower abdominal region, but any movement of the body produced pain. The temperature, pulse, and respiration continued about

the same, and there was no other change in the symptoms. Nervous symptoms developed a few days later, such as persistent pulling of the ears, marked tremor of the arms, and later of the legs, exaggerated during motion and subsiding only during sleep; prolonged attacks of crying, lasting over periods of three to five hours; there was marked retraction of the head, the muscles of the back of the head and neck were in tonic spasm; the eyelids were partially closed, the balls rolled upward, pupils were normal; no vomiting. On the tenth day after the child came under observation a cough developed, soon became very severe; respirations rapidly increased, getting as high as 80 per minute; no expiratory moan. The lungs were full of coarse and fine moist râles. The child grew rapidly weaker, lost much flesh; temperature and pulse continued the same, the latter losing daily in volume, persisting between 160 and 170.

The symptoms continued until death, which occurred just three weeks after the child was placed under treatment.

*Autopsy. Heart and pericardium* normal. There were some firm tenacious clots in the right heart.

*Pleuræ.* Normal; not adherent.

*Lungs.* Small patch of croupous pneumonia on lower lobe of left lung. Right lower lobe much congested, but would not sink in water.

*Spleen.* Seemed slightly enlarged.

*Lymphatic system.* The bronchial glands were slightly enlarged, and the mesenteric glands quite considerably enlarged.

All the abdominal organs appeared normal with the exception of the right kidney, which presented the rather remarkable appearance you here observe.

It is increased, I take it, to about five or six times the size of the normal kidney of an infant of seven months; it measures about five inches in length, two and three-quarters in breadth, and one and a half in thickness.

The capsule is tremendously thickened and extensively infiltrated with fat. The surface of the kidney is irregularly nodulated. The capsule is tightly adherent at points, and on stripping is found covered with particles of degenerated kidney structure which have adhered. On section the parenchyma is found to be made up of tubercular nodules in all stages of development, one or two of which are necrosed. There is apparently but little healthy tissue.

The pelvis, curiously enough, is smaller than that of the left kidney; its mucous membrane is smooth and not at all thickened. The ureters and bladders are normal.

There are some sections under the microscope showing only cheesy change. Dr. Riesman has kindly prepared these for me.

*November* 23, 1893.

---

9. *Ulceration of the vagina and cervix uteri, the latter carcinomatous.*

Exhibited by Dr. McFarland.

The woman had a uterine displacement, and wore a pessary which caused ulceration of the cervix and vagina. The parts were removed by a surgeon.

Microscopically the vaginal ulcers showed no malignant change, but only "proud flesh." But in the cervical tissue distinct carcinomatous change is evident. *December* 28, 1893.

---

10. *Specimen showing metastasis of cancer of the breast.*

Exhibited by Dr. Guitéras.

Rose D., aged 55 years, white, Irish, admitted to the nervous ward of the Philadelphia Hospital, where she was treated as an ordinary hemiplegic. Her short stay in the nervous ward precluded any careful clinical examination. Clinical diagnosis: hemiplegia. Pathological diagnosis: primary cancer of the breast; secondary cancer of the bronchial glands, the lungs, the liver, both adrenals, the uterus, one broad ligament, both frontal bones, and the white substance of the brain.

Autopsy forty-eight hours after death: Body of a somewhat emaciated white woman, showing well-marked rigor mortis. Surface of the body very white; no contractures. The right breast presents a scar from a previous operation. There is a small superficial ulcer in the line of the scar. Beneath the ulcer there is a small tumor. The abdominal viscera are found in normal position. The left lobe of the liver projects very slightly in the median line. Peritoneal cavity presents no abnormal contents. The vermiform appendix is free and extends upward along the outer wall of the colon.

*Thorax.* The lungs are prominent in front; they cover the pericardium almost completely.

*Pericardial sac.* Contains some excess of fluid; otherwise normal.

*Heart.* Weight 240 grammes. The cavities contain a considerable amount of soft dark clots. The tricuspid admits three fingers and the mitral two. The heart is small, the cavities contracted, and the walls slightly thickened. The mitral valve is the seat of commencing sclerosis. The endocardium of the left ventricle is opaque, and the papillary muscles are slightly indurated. The aortic valves are normal; the aorta presents a few small patches of atheroma.

*Left lung.* Weight 400 grammes. The upper lobe presents a few adhesions in front; the lower lobe is congested and presents a few small areas of catarrhal pneumonia. The bronchial glands are large and surrounded by thick fibrous capsules. Most of them contain whitish nodules. The new growth extends from the bronchial glands into the circumjacent lung, forming there an irregular mass about the size of a pigeon's egg. Smaller superficial nodules are found upon the mediastinal aspect of the lung.

*Right lung.* Weight 455 grammes. The bronchial glands affected, as upon the left side; the circumjacent lung is less involved. There is a nodule of the size of a small walnut at the apex. The pulmonary tissue is otherwise normal; the parietal pleura is normal throughout.

*Spleen.* Is rather small, but presents no morbid change.

*Left suprarenal.* Is double the normal size and totally changed into a white, firm mass, similar in character to the new growths above described.

*Left kidney.* Is small and of irregular shape. The upper half consists of two fibrous sacs filled with a white, soft, cheesy material; the lower half is normal. The ureter is not obstructed. Weight 95 grammes.

*Right kidney.* The size is normal; the consistency rather lessened; the color is pale; the cortical substance is in excess; the pyramids are short. The pelvis and the ureters are slightly dilated.

*Right suprarenal.* Presents two white nodules of the size of large peas.

*Right broad ligament.* Presents a single cyst with smooth walls and clear fluid-contents. Upon the posterior wall externally there is a small white nodule. The cyst probably caused some pressure upon the right ureter.

*Ovaries.* Are both atrophied and fibrous.

*Bladder and rectum.* Normal.

*Uterus.* Rather small. Upon the fundus of the uterus, close to the left Fallopian opening, there is a white nodule about the size of a pea. It does not appear to involve the muscular substance. The cervix and vagina are normal. The uterine cavity presents upon the anterior sur-

face in the median line a small, white, superficial nodule of the size of a pea.

*Duodenum, stomach, pancreas.* Normal.

*Liver.* Normal in size and somewhat fatty. It presents a large number of nodules throughout its substance. These are cream-colored, rounded, and well circumscribed. The superficial nodules are distinctly umbilicated; the left lobe is more extensively involved than the right; the largest nodules do not exceed the size of a walnut.

*Head.* The periosteum over the frontal bones is found to be raised in smooth, circular areas measuring from five to ten millimetres in diameter. The color of these does not differ from that of the surrounding bone; they are but slightly elevated and might be easily overlooked. The point of the knife easily penetrates at these points through the external table. The new growth, resembling in color and consistency a raw potato, can be readily picked out, having a funnel-shaped excavation in the bone, with the base toward the periphery. Five growths were counted in the left frontal plate, and three in the right. The calvarium is thick and the dura adherent to it. The inner table, however, presents nothing abnormal. The same may be said of the base of the skull, of the substance and inner surface of the dura, and of the sinuses of the latter. Other portions of the skeleton were not examined.

*Brain.* The pia and arachnoid are normal. The left parietal lobe is somewhat depressed and gives the sensation of a deep-seated cyst. This comes nearest the surface, involving the deeper layers of the gray matter in the supra-marginal convolution. The little finger introduced into the cyst reaches, anteriorly, to the white substance beneath the ascending frontal convolution. The cavity contains softened brain-matter. The bloodvessels and membranes at the base are normal. The left lateral ventricle is dilated. Its outer wall, opposite the thalamus, presents a distinct bulging. This is hard, and involves somewhat the adjoining part of the roof of the ventricle. The ependyma and brain substance immediately beneath it are normal. The eminence corresponds with the position of the cyst toward the periphery.

Upon making a horizontal incision into the hemisphere outward from the corpus collosum a large cancerous mass four and one-half centimetres in diameter is found. The cancer appears to affect the white substance only. Toward the periphery there is an area of softening corresponding to the cyst-like formation above described. The internal portion of the tumor toward the ventricle is quite hard. The cancerous mass is sharply defined by a reddish line from the white substance. The red zone presents some radiated markings and gradually fades into

the grayish-white color of the central portion of the tumor. The basal ganglia, the right hemisphere, and other portions of the brain present no gross lesion.

The intestines are normal. *March* 22, 1894.

---

11. "*Single*" *kidney the seat of abscess and multiple calculi.*

Exhibited by Dr. F. S. Pearce.

*Apropos* to the specimen of "Calculus in the Kidney from an Obscure Case of Uræmia," shown by Dr. Griffith at the meeting of March 22d, it occurred to me there was a unique kidney in the mortuary of the Presbyterian Hospital. With Dr. E. L. Duer's permission, this "*single*" right kidney is here presented. It is encased in an immense amount of fat. The organ was enlarged and lobulated at the time of autopsy (now being contracted and bleached by the action of alcohol since October 16, 1891). In the pelvis are seen a few masses of uric-acid concretions remaining.

On section at the time of the post-mortem a large abscess was discovered in the cortex, extending down into the pelvis, which also contained a large number of calculi, ranging in size from a few millimetres to more than a centimetre in diameter. They were mostly angulated and whitish in color. The capsule of the organ was adherent and the cortex very much narrowed; indeed, there was very little semblance of normal structures in the kidney.

No left kidney could be found, and on tracing down to the bladder there was also absent any ureteral opening into the bladder on the left side. Neither was there a renal artery leading off to the left from the aorta, nor any anomalous vascular supply toward the right or left in the abdominal cavity.

The other organs were recorded as follows: Lungs rather dark, otherwise normal. Spleen normal in size and consistency. The digestive tract presented no pathological change. There was post-mortem discoloration of the small intestine in limited areas. The heart was large, but not "bovine." It contained a currant-jelly clot in the left ventricle. There was slight atheroma of the aortic leaflets; the other valves were normal. *Dry gangrene of the right leg to above the knee.*

The woman from whom the kidney was obtained was of Irish descent, married, 56 years of age, and had been operated upon by Prof. Gross

for piles and vesical calculi some eight years before admission to the hospital (March 16, 1891).

The patient complained of incontinence of urine and vesical irritation ever since, as she had done before the operation. After freshening the edges of the urethra and stitching, she was somewhat relieved of the incontinence and was discharged.

She was readmitted to the ward October 1st, complaining of dyspepsia and gastro-intestinal disturbance and the vesical tenesmus. No stone could be found in the bladder. General health was bad. On October 6th she complained of *intense* pain about the knee of the right leg. Her breath became extremely fetid, and she presented the anxious expression of one undergoing some form of acute toxication. There was no œdema, no convulsive movements; nor were there any casts in the urine, which was also not scanty, but was of high specific gravity. It contained many uric-acid crystals, and a ring of albumin on boiling the upper stratum, to which acetic acid was added (from the cystitis and pyonephrosis). Uræmia was therefore not alone prominent at least. There must have existed some other form of dyscrasia. Very likely it was septic. The temperature was slightly above the normal most of the time.

On October 9th the right leg became very cold and there was loss of sensation in the toes. The right leg up to above the knee now became the seat of dry gangrene, the unremitting and unrelievable pain only ceasing at death, October 14th, 1891.

As the autopsy was obtained in limited measure only, and after the body was removed from the hospital (the femoral vessels not being cut down upon), the actual local cause of the "dead-leg" cannot be proven. It was most likely embolic. The cause may have been due to a general hæmolysis, probably from pus-product poisoning. It is to be regretted a blood examination had not been made.

As to the disorganized single kidney, it teaches the extreme conservatism of nature, compensation taking place through the other emunctories. The digestive tract giving out, the *vital* cord snapped.

*May* 10, 1894.

---

12. *Sarcoma of uterus.*

Exhibited by Dr. M. H. Fussell.

Mrs. R., aged 60 years. Was well until forty years old; at that time she had menorrhagia and at times metrorrhagia. Menopause finally

occurred at the age of fifty years. From then until she was fifty-eight she enjoyed good health. About that time she began to have abdominal pain, with a bloody vaginal discharge. One year before her death she began to have severe uterine hemorrhages. At that time she was seen by Prof. B. C. Hirst, who diagnosed a uterine fibroid of considerable dimensions. His opinion at that time was that the fibroid was possibly undergoing sarcomatous change. Six weeks before death I saw the patient. The uterine hemorrhages had entirely ceased and did not again recur. The patient suffered much from abdominal pain, however, and she became obstinately constipated. The symptoms of pain and obstruction of the bowels increased. The abdomen became distended with liquid, and the patient died of exhaustion, having absolute obstruction of the bowels for more than a week before death.

At the section, twelve hours after death, the peritoneal cavity was distended with about ten quarts of bloody serum; the entire peritoneum, both parietal and visceral, was studded with numerous new growths. One patch on the parietal peritoneum in the median line was the size of a hand, and broke down easily on handling. The uterus was enlarged to the size of a large cocoanut. The entire cavity was filled with an old fibroid, which had undergone the same degenerative change as was evident in the new-growths on the peritoneum. On section these new growths presented the typical structure of a large round-celled sarcoma.

*May* 10, 1894.

---

13. *Tubercular kidney.*

Exhibited by Dr. J. M. Swan.

E. E., aged 34 years, white, a weaver by occupation, was admitted to the Presbyterian Hospital October 3, 1893. At this time he complained of an urethral discharge, and was passing small quantities of urine at short intervals and in a very small stream. Micturition very painful. The urine contained a large amount of pus, some albumin, no sugar and no casts. Amount of urine daily 23 ounces. A No. 30 (French) sound was passed. Temperature in the evening 103° to 104°, pulse 100, respiration 24. At this time he also complained of pain over the left kidney, which pain was increased on pressure.

The man is emaciated, weighing about 124 pounds; normal weight 140 to 150 pounds. He has always been healthy, except for a slight hacking cough and repeated night-sweats, which, however, he did not

notice until his present illness, which began four years ago. The illness is dated back to an attempt at coition, which was not completed, and which was followed by the urethral discharge spoken of above. Following this he noticed pain and soreness in the left lumbar region, which lasted about two hours each day.

*Physical examination.* On the right side of the chest there are evidences of scattered areas of consolidation of the lung. Examination of sputum revealed the presence of tubercle bacilli. Liver slightly enlarged. On the left side the area of nephritic dulness is increased and at places is absolutely flat. There is intense pain on pressure in this region. Over this area of dulness there is a sense of deep fluctuation imparted to the palpating finger; the softest part of this area is on a level with the twelfth rib, and four inches from the spine. Anteriorly the curve from the ribs to the pelvis is not so marked on the right side as on the left. There is slight fulness in the lumbar region.

On October 28th nephrotomy was done, and about a pint of very fetid pus was evacuated from the kidney substance. No calculi were found. After this operation there was, almost constantly, a profuse discharge of greenish-yellow pus from the wound. This pus was urinous in odor and irritating to the skin over which it passed. The temperature showed a daily evening rise; but the patient was able to be up and about the ward. The constant discharge was very annoying and showed no evidence of abating.

On May 22, 1894, Dr. Wharton performed a nephrectomy. At this time the patient was passing a fair amount of albuminous urine. After the operation the urine contained large amounts of albumin and granular and hyaline casts, and free blood-corpuscles were found in the sediment. Since the operation the patient has gradually and steadily improved, the discharge of pus from the wound has grown progressively less, and the incision is rapidly filling up with healthy granulations. The temperature keeps close to the normal line, occasionally rising to 100° in the evening. Patient is passing between 7 and 10 ounces of urine in the twenty-four hours, with very little albumin, and containing no casts in the sediment.

The remains of the kidney removed show almost entire absence of renal structure. At one end is a large cavity the walls of which consist of unhealthy granulations, with some bloodvessels running through the floor. The remainder of the organ is composed of cysts, each containing whitish, granular, semi-solid, cheesy material.

The microscope shows very little renal tissue, and the little that is seen is the seat of a catarrhal inflammation. Near the wall of the

abscess-cavity a great degree of round-celled infiltration is seen, completely obscuring the tubules and Malpighian tufts. There are no evidences of decided tubercular formation.

I do not think the attempted coitus, on which the patient laid so much stress, had anything to do with the etiology of the disease. I diagnose the almost shapeless mass a tubercular kidney, from the evidences of tuberculosis in the lungs, associated with the presence of tubercle bacilli in the sputum, and from the character of the pus contained in the cysts, and from its decided resemblance to a kidney removed at an autopsy at the University Hospital by Dr. Guitèras, in 1893, and pronounced by him tubercular. *June* 28, 1894.

---

14. *Cerebral tuberculoma.*

Exhibited by Dr. W. E. Hughes.

The patient, a male, aged 25 years, was admitted to the Presbyterian Hospital in July. His mother had died of phthisis. He had suffered an injury to the left side of the head which rendered him unconscious. It was thought to be a fracture of the skull, but he recovered. Eight months before death Jacksonian epilepsy developed. The aura began in the left foot and ascended up to the scar on the right side of the head. There was tonic spasm of the left arm and clonic of the left foot. There was occasionally complete unconsciousness, and he bit his tongue. The convulsions were always absolutely limited to the left. The face was not involved. There was a history of more marked convulsions and a failure of mental powers. On his return to the hospital he was stupid and had general convulsions. The fever went up to 110°, and death followed.

Post-mortem there was no fracture of the skull discovered, but it was curiously thinned out as though by malnutrition. There was also a more marked thinning of the part over the tumor. On the right side of the brain, posterior to the motor area, there was a mass harder than the surrounding brain tissue. It was smooth, shining, white, and passed itself imperceptibly into the brain tissues. A secondary growth was also seen, or what had this appearance.

The lungs showed only caseation at the apex of the left. Throughout the rest of the lungs there were small nodules, which were probably tubercles. The bronchial glands were very large, but not cheesy.

The liver contained a large number of millet-seed-sized nodules. The spleen was similarly affected.

The kidneys had a little parenchymatous nephritis. The mucosa of the intestine was ragged and eroded in spots. *January* 10, 1895.

---

15. *Two cases of ruptured tubal pregnancy.*

Exhibited by Dr. S. W. Dougherty.

1. The patient was 34 years of age, and had seven children. At two o'clock Wednesday morning she experienced a sharp pain in the right iliac fossa, which she attributed to cramp, and did not consult a physician, but took whiskey and ginger. At eight she started for market, but was overcome by faintness and had a cold sweat, and made her way home with difficulty. At three in the afternoon a physician was summoned, who advised her removal to the German Hospital. She was admitted at 5 P.M., her condition being that of approaching collapse. Dr. Deaver diagnosed extrauterine pregnancy with rupture, and operated immediately. The abdominal cavity was filled with blood and clots. Subcutaneous injection of normal salt-solution was practised during the operation. She reacted well, and is now in a very fair condition. The specimen shows that rupture took place remarkably early, the tear being small. The fœtus was not found. The menstrual history in this case was normal.

2. The patient, aged 46 years, was admitted to the German Hospital in August with retroflexion of the uterus, which was dilated and curetted. At that time she was thought to have ovarian and tubal trouble on the right side, but operation was deferred owing to her weak condition. She improved steadily until November 22d, when at five in the morning, while walking in the hall, she was taken with a sharp pain in the right side, which disappeared in a few moments. On returning to bed she had a second attack of pain very suddenly and fainted. She was collapsed and almost pulseless, but under treatment she reacted slowly. At three in the afternoon a diagnosis of ruptured tubal pregnancy was made by Dr. Deaver, and the operation followed at once. The belly cavity was filled with blood and clots. No fœtus was found on careful examination. She had not menstruated for two months.

*November* 22, 1894.

16. *Uterus and ovaries from a case of peritonitis from rupture of an ovarian cyst.*

Exhibited by Dr. J. K. Mitchell.

The patient was a servant girl, who, a week ago, complained of slight pain under the left side below the ribs. She was constipated, and laxatives relieved the pain. She returned again, and was again relieved. Subsequently she was found with features of peritonitis, the symptoms beginning after menstruation. Two days before she had had no sign of peritonitis. Morphine was given, and the next morning she felt entirely well, but vomited her breakfast. At 10 o'clock she was collapsed, was livid, pulseless, cold, and the abdomen was tense but not swollen. The diagnosis of the twisting of the pedicle of a parovarian cyst and of extrauterine pregnancy were thought of, but the latter was ruled out by the hymen. The patient died. The autopsy showed both ovaries enlarged and knotty, with a small cyst in each, also a parovarian cyst on left side. The cyst on the right ovary was ruptured and empty, with no contents left. It could not have contained more than a drachm. There was no free pus in the abdomen. The jejunum showed inflammation on the surface.

Dr. Deaver thinks the patient was merely in shock from internal hemorrhage. *November* 22, 1894.

---

17. *Ulcer of the bladder with miliary abscesses of the kidneys in a patient dying with some of the symptoms of Raynaud's disease.*

Exhibited by Dr. Francis R. Packard.

J. C., aged 64 years, white, house painter, was admitted to the men's medical ward of the Pennsylvania Hospital November 25, 1894, and died December 1, 1894.

*Family history.* Negative.

*Previous history.* Always a strong, heathy man; smokes; is a very moderate drinker; denies venereal disease; had all the ordinary diseases of childhood. When 18 years old had inflammation of the lungs, but has had no illness since. Says he never suffered from painter's colic or any other form of lead-poisoning. Never noticed any œdema. Never had a cough. Never had rheumatism.

*Present illness.* He has been a patient in the lower surgical ward of this hospital for the past nine days, having been admitted for incontinence of urine and hæmaturia. He has no stone, no stricture, or any other discoverable surgical affection of the genito-urinary tract. He says that four months ago, for no assignable reason, he began to pass bloody urine and to urinate involuntarily. He says this condition was periodical, but says the intervals between attacks varied greatly. He continued working at his trade up to a few days before admission. No pain with micturition. Bowels move regularly, and he has perfect control over them. Appetite good. No headache.

Two nights ago, while in the surgical ward, he was seized suddenly with an attack of dyspnœa. This has continued to the present date. Has some cough ; very slight expectoration. His eyelids have become puffy.

On admission to men's medical ward the temperature was $100\frac{3}{5}°$, pulse 98, respiration 28.

*Urine.* Clear, amber, small amount of white sediment. Specific gravity 1012. Albumin 8 per cent. by bulk. Microscopical examination revealed many red blood-cells, some crystals of oxalate of lime, but no casts ; many pus-cells.

*Heart.* Area of dulness normal. Soft, blowing, systolic murmur at apex. Second sound accentuated at pulmonary cartilage.

*Lungs.* Some loud, asthmatic râles ; otherwise negative. No impairment of resonance.

*Liver-dulness* begins at the sixth rib and extends to the costal margin ($2\frac{1}{2}$ inches).

*Splenic* area of dulness increased.

*Abdomen* contains no demonstrable fluid.

Pulse was of high tension. Reflexes all natural. Blue-line on lower gums.

The helices of the ears are purple, and cold to the touch. Over the styloid processes of each ulna there is an area of purplish discoloration, cold to the touch. Skin very dry.

His lower *eyelids* are puffy. *Expression* anxious. *Tongue* thickly furred, white in centre. *Breath* offensive, but not urinous. No œdema anywhere. Reflexes natural.

*Blood examination.* Red blood-corpuscles, 3,468,000 per cm. ; white blood-corpuscles, 48,000 per cm. ; hæmoglobin, 40 per cent.

He was given a hot-air bath—temperature 100°—until free sweating was induced. This made him much more comfortable, and shortly after it he feel into a natural sleep. Nitroglycerin (1 per cent. solution), gtt. ij, t d.

*26th.* To-day the areas of blueness have disappeared. On putting the hands in ice-water or pressing them firmly they become very blue. Pressure on the feet also produces temporary purplish discoloration. Passed fifty-two fluidounces of urine in twenty-four hours. Temperature normal. Pot. iodid., gr. x, t. d., in addition to previous treatment.

*27th.* Breathing became labored to-day; lips rather blue. No appearance of areas of discoloration. Passed a very small quantity of bloody urine involuntarily.

Was given a hot-air bath until sweating was induced. This relieved him considerably.

*29th. Urine* pale, yellow, abundant precipitate. Specific gravity 1015; alkaline; albumin 5 per cent. by bulk; no casts; many blood-corpuscles, oxalates, and phosphates. Impossible to measure urine, as he is delirious and it is passed involuntarily. Was given another hot-air bath. Respiration very shallow and labored; pulse of high tension; no blueness anywhere, nor can it be produced by pressure or cold.

*December* 1. Condition gradually growing worse ever since last note. Respirations more shallow and labored. Pulse averages thirty-eight beats to the minute in the past twenty-four hours. No return of blueness. Lies in a comatose condition. Pulse was very feeble all day. Was given two hot-air baths; by both of them free sweating was induced, but no material change in symptoms effected. Was given, in addition to nitroglycerin, strychnine sulph., gr. $\frac{1}{30}$, third hour; spts. ammon. aromat., f℥ss, second hour. Died at 4.30 P.M.

Autopsy, eighteen hours after death.

Body that of a stout, well-nourished man. Rigor mortis well marked. Marked blue-line on gums beneath lower incisors.

*Heart* large; pericardium normal; apex made up of left ventricle in normal proportion. All the cavities contained chicken-fat clots. *Right auricle* slightly dilated; foramen ovale closed. Endocardium, right leaflets and orifices of right side normal. Four cm. from root of pulmonary artery the intima is of a pale yellowish color in a few small areas (early atheroma). Wall of right ventricle $\frac{1}{2}$ cm. in thickness. *Left auricle* of normal size, and endocardium healthy. Mitral valve leaflets healthy. The general endocardial surface of the left ventricle is opaque. On ventricular surface of anterior mitral valve leaflet there is a broad, yellowish-white patch of thickened endocardium. At ends of papillary muscles two small areas of whitish thickening of endocardium. A distinct, poorly-developed moderator band runs across the left ventricle. Average thickness of left ventriclar wall $1\frac{75}{100}$ cm. Aortic valve leaflets normal. In sinuses of Valsalva marked, diffuse, atheroma-

tous change, not very well advanced and without calcareous infiltration. Same process higher up in root of aorta. On opening coronary arteries there is found diffused atheroma.

*Pleuræ* healthy.

*Lungs* normal, except for a few old adhesions at right base.

*Abdominal* walls very fat; much fat in omentum; no trace of peritonitis; no enlargement of mesenteric glands.

*Liver* normal in size and weight. Surface studded with quite frequent, small, miliary tubercles, about 1 to 3 cm. in size. None found in substance. Gall-bladder distended with stones. No calculi in ducts.

*Spleen* healthy.

*Kidneys* looked like those of chronic parenchymatous nephritis. Surfaces of both were thickly studded with what appeared to be miliary tubercles, from 1 to 3 cm. in size. Many similar nodules also found throughout substance. The pelves were filled with pus and their lining mucous membranes much injected.

*Ureters.* Rather capacious, perfectly normal in appearance; no evidences of tuberculosis.

*Bladder.* Rather contracted; whole surface roughened, except at bas-fond. On the roof of the inner surface is a large, white, spongy mass. At the right side of the upper portion is a pendulous, soft, friable, cheesy mass with ragged surface, measuring 5 cm. in length. General surface of bladder ribbed. It contained about one fluidounce of yellowish-green pus.

*Brain.* Perfectly healthy. Nothing found in any of the ventricles.

*Microscopic examination of kidneys.* Both kidneys show a general, diffuse, round-cell infiltration with numerous small, purulent foci scattered throughout cortex and medulla. The cellular infiltration is most diffuse in the cortex, where it is seen both in and around or entirely replacing the tubule and glomerule. The epithelium of the tubules is in places entirely lost; elsewhere it shows evidences of degeneration. In the medulla the purulent foci are more circumscribed, and the collecting tubules are here and there distended by masses of pus-cells, the latter condition apparently indicating that the process has ascended from the pelvis.

There are a few areas which show small hemorrhages with deposition of blood-pigment. The arteries throughout are more or less thickened and in places show amyloid degeneration. The latter is also seen in one or two of the glomerules. *December* 13, 1894.

### 18. *Atrophic nephritis.*

Exhibited by Dr. W. E. Hughes.

The patient, a woman, from whom no history could be obtained. She was much emaciated and had evidently had some injury to the knees or old rheumatic disease. She seemed to be about 69 years old, was very stupid, and exhibited no especial symptoms. The urine showed a moderate amount of albumin, but no casts. The post-mortem showed:

*Right kidney.* Enlarged, rather diminished in size, granular, firm, and pale. The external surface was atrophic in spots, and there were small cysts.

*Left kidney.* Very small; structures nearly all gone except in spots. The interior is a thick-walled cyst, evidently developed from the pelvis. It has numerous compartments. There were old sores and fresh tubercles in the lungs. The right heart was dilated and full of semifluid blood. The aorta was dilated to twice the normal size. There were some fatty patches.

The study of this kidney is interesting in connection with analogous cases in which not exactly similar pictures result from the same renal disease. *January* 10, 1895.

---

### 19. *Enlarged uterine veins.*

Exhibited by Dr. Coplin.

The case was one of eclampsia in pregnancy, due to parenchymatous nephritis.

The most interesting feature of the post-mortem was the enlargement of the uterine and ovarian veins on one side. The uterine was considerably larger than the vena cava at the diaphragm, and was about the thickness of two thumbs. On the opposite side it was normal. It was a twin pregnancy with two placentæ. There was some quantity of blood in the retroperitoneal connective tissue. The lungs were intensely congested. The heart normal, excepting slightly friable and granular.

Dr. Coplin said he had made autopsies on many cases of eclampsia, and had found the kidney changes to be not interstitial. The advanced changes in the epithelium are the striking feature. The urine is also

rather indicative of parenchymatous lesion. There is much albumin, but, as a rule, no blood. The changes are rather those of an acute degeneration of the tubules. *January* 10, 1895.

---

20. *Carcinoma of breast of unusually long duration.*

Exhibited by Dr. Riesman.

The chief interest with this specimen springs from the fact that it is a malignant tumor, the course of which has been exceptionally and remarkably chronic. It was removed by Dr. Barton from a patient in the Philadelphia Hospital. The clinical notes were kindly furnished by Dr. D. E. Esterly.

The patient, C. H., now 68 years old, noticed, when about 20 years of age, a small, hard nodule, the size of a pearl-button, under the skin of the right breast, just below the nipple. It gradually enlarged until it attained the size of a hen's-egg, but was not painful. Later, it became inflamed without any apparent cause, and after remaining stationary for a period of years began to ulcerate. The ulcer persisted, with occasional unsuccessful attempts at cicatrization, until the day of operation, in September, 1894.

There was no involvement of the axillary lymphatic glands. The tumor was hard, not adherent to the underlying muscles, and had an ulcerated surface, nearly circular in outline and measuring about 1½ inches in diameter. The edges were congested or scalloped and somewhat everted. The ulcer itself was depressed and crater-like, with a rather smooth floor. In the upper part there were a few papillary prominences. The nipple was invisible, but about an inch from the upper edge of the ulcer there was a deep, linear depression that at first sight looked like the nipple, but on close inspection was found not to be so.

*Microscopy.* The microscopic examination clearly proves the tumor to be cancerous. As might be expected from a growth with such a peculiar clinical course, it also presents an anomalous histology. The epidermis is quite normal; below it we have a cancer tissue in the form of acini, as we see it in glandular carcinomas; deeper down we find that the nests have a more adenomatous character, the walls nearest to the stroma being columnar. There is also in this part a marked hyperplasia of the connective tissue, which has grown into the cancer tissue and

separated it into nests of a cylindrical or tubular outline. In some places there is a striking analogy to the angio-sarcoma tubulare. Dense masses of normal cells and a peculiar granular degeneration, perhaps fatty, complicate the picture.

*Remarks.* According to the history, the patient had this tumor for over forty (forty-eight) years, which, if we assume it to have been cancerous all these years, would make it a unique case. As far as I have been able to ascertain, the duration of chronic cancer is rarely over ten years. Williams,[1] in 234 cases of cancer, found only 38 chronic, *i. e.*, lasting over five years, and of these only one was of more than twenty-five years' standing. Henry's[2] most chronic cases had lasted but ten years, and Bryant,[3] in 504 cases, noted 17 with a duration of from ten to twenty years. Ashhurst[4] refers to cases lasting ten to twelve years or longer. The question arises in this case, Was the tumor cancerous from the time of its inception or was it first an adenoma which, in course of time, from an excessive hyperplasia of the epithelium with penetration of the basement membrane, became cancerous? *February* 28, 1895.

---

## 21. *Chronic nephritis and tubercular pyelitis.*

Exhibited by Dr. A. O. J. Kelly.

The specimens which I present this evening are from a case which was under the care of Dr. D. D. Stewart, for whom I made the post-mortem examination and to whom I am indebted for them. The patient, I believe, came under Dr. Stewart's care about two months ago, supposed to have been suffering with chronic Bright's disease. Examination of the urine gave evidences of the truth of this supposition, and during a careful systematic examination the presence of pus in the urine suggested to Dr. Stewart the propriety of examining the pus for tubercle bacilli. The bacilli were found by Dr. Stewart, and on several occasions, I think, by a medical friend of his. I present the heart, the kidneys, ureters, bladder, and genital apparatus. The following are the notes of the autopsy made April 2, 1895, seventy-two hours after death: Body of a rather slightly developed, poorly-nourished

[1] Williams: Diseases of the Breast.
[2] Henry: Statistische Mittheilungen uber Brustkrebs, p. 114.
[3] Bryant: Diseases of the Breast.
[4] Ashhurst: Principles and Practice of Surgery, fifth edition, p. 533.

female; panniculus adiposus slight; muscular tissue somewhat atrophic. The natural appearances of the tissues and organs of the body have been somewhat disturbed, particularly in the direction of excessive dryness, and the serous cavities more or less filled with the embalming fluid. Thoracic and abdominal viscera have their normal positions. Left pleural cavity contains dirty, red fluid; parietal pleura is firmly adherent to the costal pleura posteriorly and below and to the diaphragmatic pleura. Except some slight deficiency of tissue at edges, the left lung is normal; no evidences of tuberculosis. Right pleural cavity contains similar dirty, red fluid; the two layers of the pleura are adherent—posteriorly and below. Excepting some slight thinning at edges, right lung, upper and middle lobes, normal; lower lobe rather dense, heavy, contains air, no evidences of tuberculosis.

Pericardium contains about 10 c.c. of clear serum. Heart is much enlarged; walls of left ventricle are twice their usual thickness; on the posterior mitral leaflet is a small islet of thickening. Tricuspid râles show no abnormalities (specimen so much changed post-mortem that it is impossible to speak positively). Pulmonary and aortic leaflets normal. Omentum normal. Liver is about normal size; capsule normal; on section bloody; the centre of the acini reddish-brown; the periphery more yellowish. Gall-bladder normal. Spleen somewhat increased in size, rather dense, pulp dark brownish-red, section surface smooth, capsule and tuberculæ thickened. Stomach, pylorus, duodenum, appendix, cæcum, large and small intestines, normal. Left kidney is about normal size; feels denser than normal. Capsule here and there slightly adherent. Surface is mottled in appearance in that a general grayish-red hue with a few yellowish points alternates with dark-reddish spots. On section the cortex is normal or slightly increased in thickness, striated, yellowish-red and gray, with here and there distinct spots of dark reddish-brown color. The kidney has two ureters, both normal, although one is smaller than the other; they join just before entry into the bladder. The right kidney presents the same general characteristics, except the pelvis, which is dilated and contains pus. The surface is studded with small, miliary points of grayish-white to yellowish color. There is one ureter which is normal. Bladder contains a small amount of pus. Bladder itself normal. The ureter is somewhat atrophic. Attached to the left cornua is a pedunculated fibroid the size of a goose-egg; on the anterior surface to the right of the median line is a small, calcareous fibroid, size of a small chestnut. Tubes appear a trifle thickened; ovaries atrophic; retroperitoneal glands apparently normal.

*Pathological diagnosis.* Chronic hemorrhagic nephritis with tuber-

culous pyelitis of the right kidney; hypertrophy of the heart, left ventricle; chronic induration of the spleen; nutmeg kidney.

The following day examination of the pus from the pelvis of the kidney and that contained in the bladder showed the presence of tubercle bacilli in both. *April* 11, 1895.

---

22. *Papillomatous ovarian cyst.*

Exhibited by Dr. Thomas.

Mrs. I. M., aged 33 years, admitted to the Presbyterian Hospital May 16, 1895.

*Family history.* The father died at fifty; cause unknown. Mother living at fifty; strong and well. Patient has two sisters and one brother living and well. Maternal grandfather had a stroke of apoplexy. No family history of cancer or tumors of any kind. No family history of consumption.

*Personal history.* Usual diseases of childhood. Always was strong and well until three years ago. Menstruation started at fifteen, and was always regular and without pain. She married at twenty-four. Has had no children. About four years ago she commenced to complain of a pain in her side (left) and back. About three years ago her abdomen commenced to swell up, and she had a great deal of pain in the back and side. She had been tapped forty times previous to admission to hospital. These tappings were done at varying intervals. Lately these intervals were about three weeks.

On admission to the hospital the patient was tapped and twenty-six pints of a clear, yellow fluid were obtained. This fluid, on standing, deposited a reddish sediment which had the gross appearance of urates. Microscopically, it was found to consist of red blood-cells in abundance, leucocytes, and epithelial cells. No cholesterin plates were observed. The fluid contained 2.8 per cent. of albumin and had a specific gravity of 1015. The patient was etherized on the 20th, and an exploratory incision was made in the linea alba. The sheath of the rectus was greatly thickened. After cutting through its posterior layer, the peritoneum was seen. On incising it a fluid poured out similar to that obtained at tapping. An immense cauliflower mass filled the left lower abdomen. This had been previously palpated after she had been tapped. Everything was so bound down that the point of origin could not be ascertained. The mass was undoubtedly cancerous.

Temperature 91°, pulse 92, respiration 20, after operation.

She had a great deal of pain following the operation. This required gr. ¼ of morph. sulph. every hour, and then it was not controlled. She had taken a great deal of laudanum before the operation. She was delirious all the time and did not recognize anyone. She would try to get out of bed and did not seem at all weak. Temperature rose to 104⅖° this morning, and she died at about 6.30 A.M.

Body of a very much emaciated white woman. Abdomen very much distended, a solid mass apparent in lower part. Rigor mortis marked. Cadaveric lividity in dependent parts of the body.

Scar of laparotomy in median line, about four inches in length, on opening abdomen. Peritoneal cavity contains 1400 c.c. of an offensive sero-sanguineous fluid. Abdominal contents were pushed upward by growth. Thorax. No adhesions in left side. A few strong ones in right pleural cavity. Right pleural cavity contained 400 c.c. of a dark, clear red serum. The pericardial cavity contains a normal amount of fluid. Heart is rather small. Muscle somewhat atrophied and pale. Valves normal. Cavities distended with currant-jelly clots. The left lung is normal in appearance. Right lung is rather collapsed by fluid in pleural cavity. The lower lobe contains a succession of hemorrhagic infarcts. The liver is adherent by old, firm adhesions by its upper and posterior surface to diaphragm; capsule is thickened and unusually adherent. On section, liver is soft, friable, and somewhat yellow in spots; lobules well marked; spleen capsule is thickened, calcareous in spots, universally adherent; splenic tissue soft and confluent; stomach is very much distended; pancreas rather hard, grits on section; right kidney is rather soft; ureter is dilated to diameter of one inch as far as brim of pelvis; then runs into a mass about to be described.

Left kidney. Ureter not dilated, rather small, soft; capsule not adherent; on section, cortex is somewhat decreased in size and thickness.

Pelvis is filled with a hard, irregular mass; cystic in some parts, calcareous in others; nodular.

Bladder is not involved. Uterus is apparently free.

At points from the surface of the cyst there are papillomatous projections. The peritoneum was much thickened; no papillomatous masses. Ovaries apparently symmetrically involved.

Diagnosis. Malignant papillomatous cyst; chronic peritonitis; chronic perihepatitis; chronic peniplenitis. *May* 23, 1895.

23. *Further report of an intercanilicular fibroma of right mammary gland.*

Exhibited by Dr. F. Savary Pearce.

Most specimens presented to the Society are from the necropsy table, and therefore the most valuable to the clinician and pathologist because of the opportunity for more complete research for pathologic states, and of thus correlating the lesions in order to demonstrate the accuracy or fallacy of a diagnosis or prognosis; finally to throw new light on disease and its prevention.

A further report of a case that was thought might have come to autopsy ere this, or at least might have shown recurrent malignant disease, may not prove uninteresting, as it certainly has been instructive to us.

*To recapitulate.* Mrs. R., white, American, aged 52 years, with no marked hereditary history of malignant disease among her ancestry, presented herself to Dr. E. Pearce, of Steubenville, Ohio, in the fall of 1893, with an ugly fungoid tumor of right upper half of the right breast. The nipple was retracted. There was considerable lancinating pain in and about the tumor. The cervical and axillary lymph glands could not be made out as enlarged by palpation, nor were the veins much engorged beyond the unilateral area. The breast was movable upon the tissues beneath. The thoracic or abdominal disease could be detected. The woman was of small stature, had wasted to the last degree, and was profoundly cachectic. The menstrual flow was somewhat irregular, due to the approaching menopause.

The clinical picture had been something like this: In good health until her thirtieth year, then married; nursed her first child from both breasts. At her thirty-seventh year she noticed a small lump deep in the breast above the nipple. It gave no pain and grew but very slowly. Several years after an irregular physician "burned it out" several times, the resultant ulcer healing slowly, and the growth then remained dormant for years. Five children since borne by the patient nursed from the left breast alone, because she feared to use the right one.

At an indefinite time the tumor in the right breast began to enlarge and the growth passed through the clinical picture of slow, malignant disease apparently. All this time she kept her complaint from her family. Her health gradually failing, she finally consulted her physician, who advised immediate amputation of the breast.

The appearance of the tumor and age of the patient militated against a diagnosis of sarcoma, and from the retracted nipple and fungoid ulceration of the growth soft cancer was tentatively diagnosticated. Fortunately, such was withheld from the family. Under ether, on October 19, 1893, the breast and tumor were excised, and I brought the tumor East and presented it with slides to this Society October 26, 1893. The sections showed many round cells infiltrating the connective-tissue masses so much that some of the members made the diagnosis of sarcoma. I asked a prominent surgeon of this city at that meeting his opinion from macroscopic appearance, and he promptly replied "sarcoma." The question was referred to the Committee on Morbid Growths, and after deeper sections had been made it was decided to be an intracanilicular fibroma. This was confirmed by Professor Guitéras. The patient made a rapid recovery from the operation, lost her cachexia, and had regained her health in every respect when I saw her in December, 1894.

Dr. Pearce writes me, under date of June 12, 1895, now twenty months since operation: "She is in good general health; appetite is good; she is well nourished. I find the integument and cicatrix where right breast was excised in perfectly normal condition. No redness, swelling, induration, or other abnormal appearance. No tenderness in the wound, and she says she is entirely free from pain or inconvenience in any way. The operation up to date has been an entire success."

Dr. Morton has told me of a case of tumor of hip in the practice of Dr. Agnew, in which a diagnosis of sarcoma was made from the microscopic examination of an excised portion of the growth by the late Dr. Formad. After amputating the thigh the growth was found to be an immense ulcerated lipoma.

So far as I can find, the specimen reported from our case (and of which there is a section under the microscope) is the first intracanilicular fibroma of the mammary gland reported to the Pathological Society.

This proves that the condition is not common. The growth had partly undergone myxomatous metamorphosis. It seems singular that the tumor had not become transitional to the malignant growth it was thought to be.

*June* 13, 1895.

## VII. NERVOUS SYSTEM.

### 1. *Old hemorrhagic cyst situated in both caudate nuclei and bilateral psammomata of the choroid plexus.*

Exhibited by Dr. H. W. Cattell.

T. F., aged 59 years, was admitted to the out-wards of Blockley Hospital on February 23, 1893. On examination for admission to insane ward later on, the following conditions were noted: Right pupil dilated; left contracted; both reacted slowly to light and accommodation. Speech hesitating and thick. Liver enlarged. Diastolic mitral murmur. Hardened vessels. Paralysis of sphincters dating back to an apoplexy in 1891. Exaggerated knee-jerks, especially the right; grip of left hand impaired. Legs œdematous. Mouth slightly drawn to right. Gait normal, but he walked with short, quick steps. Memory poor. His mental state, briefly, was that of a pleasant, docile dement. Was in a comfortable condition until a few days before death, which was due to dysentery. I am indebted to C. W. Lincoln, M.D., resident physician at the Philadelphia Hospital, for the above notes.

The dura is firmly adherent to the bones throughout its entire extent, more especially beneath the parietal bones.

The arachnoid is distended with fluid, especially along the course of the middle cerebral arteries, where there was also to be found a cellular infiltration, the cause of which was not determined, though the micro-organism may have gained entrance into the circulation through the ulcer in the larger intestine. The vessels of the pia are injected. The pia and arachnoid are readily removed from the brain substance, which is anæmic and softer than normal. On opening the left lateral ventricle there was found in the corpus striatum, near the anterior cornu, a degenerated area covered by a thin membrane, showing a yellowish-brown coloration beneath. It extends toward the corpus collosum, where it is finally lost. The degenerated area is the size of an irregular quarter.

The choroid plexus contains a bean-shaped body slightly infiltrated with lime, containing a fibrous reticulum in a capillary network. A similar condition exists in the right lateral ventricle, only the depres-

sion of the degenerated area is more marked and the choroid growth is longer and more infiltrated with lime.[1]

On dissecting the brain the cyst on each side descended backward and downward, occupying the intraventricular portion of the corpus striatum, going posteriorly as far as the middle commissure. The internal capsule has escaped to a marked degree. There is a distinct wall with connective-tissue bands radiating from it.

The fluid under the microscope shows brownish masses of pigment with irregularly shaped pus-cells and compound granular cells, the latter being few in number. No cholesterin was discovered.

The third ventricle is extremely small; nothing abnormal discovered about other portions of the brain.

The post-mortem notes of the brain are alone given, the cause of death being chronic parenchymatous nephritis and dysentery.

*September* 14, 1893.

---

2. *Brain from a case of fracture of the base of the skull.*

Exhibited by Dr. Cahill for Dr. Fussell.

W. W. was admitted to St. Timothy's Hospital, October 15, 1893, partially unconscious, with impairment of speech, weak, irregular pulse, feeble respirations, partially dilated pupils, and several superficial scalp wounds on back of head. No fracture could be detected. There was no paralysis of limbs at any time. Several hours after admission the nose bled slightly; he also expectorated a little blood. The first few days he was very restless, becoming exceedingly so at night, and had to be strapped to the bed. At no time was he able to talk. He would make attempts, but could not articulate. There was a variation of 1° between morning and evening temperatures, never going above 101°, until the day before death, when it rose to 102°. Pulse was very irregular, but I could not detect a murmur. There was an atheromatous condition of the bloodvessels. Bowels were constipated, and he voided urine involuntarily. With increase of disease, patient lost control of muscles of deglutition, and twenty-four hours before death was unable to swallow. From the third to the sixth days there was a retrac-

[1] For a late and able description of psammomata, see an article by Paul Ernst, p. 234, vol. xi., of Ziegler's Beiträge zur Path. Anat. und zur Allgem. Path.

tion of head, stiffness of muscle of back of neck. For the first week patient assumed lateral position, with legs well drawn up. He died on the thirteenth day.

At post-mortem bones of skull were found to be one-half inch thick at several places; a large clot was found on the right side anteriorly, with small clot posteriorly. There was a fracture at the base of the skull; the line of fracture, four inches long, running along occipital sinus to foramen magnum. Pia mater showed intense congestion and thickening. The arachnoid was opaque. The Sylvian fissure was relatively far back. The whole frontal lobe was massive as compared with the middle and posterior lobes. On the right hemisphere there was a large clot embracing the anterior tips of all three convolutions. The brain substance beneath this was congested. On the left hemisphere there was a small hemorrhage the size of a dollar on the anterior tip of Broca's convolution. There was no softening observable. On the floor of the fourth ventricle there was a small hemorrhage slightly to the right of the median line.

Heart was enlarged and undergoing fatty degeneration. Kidneys about normal size. Cysts on the periphery. *December* 14, 1893.

---

### 3. *Brain tumor in the postero-parietal region.*

Exhibited by Dr. James Hendrie Lloyd.

This tumor occurred in a male who was admitted to Blockley with the disease far advanced. He was semi-stuporous, and little history could be gotten or subjective symptoms elicited. He had one or two convulsions, and the stupor deepened. Blindness with large pupils was present—extracortical blindness. Examination with ophthalmoscope showed choked disk. There was vomiting at times. Persistent headache was present. Latterly there was a slight hemiparesis on the same side. The condition was such that general pressure would disguise localization, and therefore no attempt was made. Earlier it might have been possible.

The post-mortem examination of the case simulates others of tumors of the postero-parietal shown in a table made by Dr. Mills and Dr. Lloyd. There are few with hemiplegia or involving the arm, leg, or face. In most there is cortical blindness. The lesion here is in the

postero-parietal region, and grew from the white matter, but had destroyed the gray matter. It is found in the angular gyrus in the superparietal and transverse occipital region. An earlier study might have elucidated the question of the visual centre. Ferrier locates the centre in the angular region, and here we have it involved. The cuneus is free, but fibres from there might be involved in their course down. The histology is not yet made out. I believe these soft, infiltrated tumors might be called areas of brain-softening. Surgical interference would have been of little benefit here. It has been preserved in formalin, and I think it has done well.

Dr. Coplin stated that formalin is very cheap, but he thinks the brain has sometimes swollen in it and that the convolutions have been rendered indistinct. He believes the softening of the tumor in this case to be a post-mortem result, and that it is due to the disappearance of blood from the vascular growths.

Dr. Riesman asks if the choked disk might not have caused blindness and if involvement of the centre would not cause hemianopsia.

*May* 24, 1894.

---

### 4. *Hydrocephalus preventing delivery.*

Exhibited by Dr. M. H. Fussell.

Mary M., II-para. Pregnancy normal. The woman went into labor at 6 P.M. Examination showed a large bag of waters presenting. It was impossible to make out the position of the child. Pains were slight, and there was little advancement at midnight. At that time the membranes were ruptured and showed a large, fluctuating mass filling the entire rim of the pelvis and not the least attempt at engagement. Under ether the mass was found to be a hydrocephalic head; the edges of the cranial bones could be felt widely separated. The head was perforated and the opening enlarged by the finger. About one pint of liquid blood exuded. The child was turned and delivered by the feet. The child was alive and breathed regularly for fifteen minutes.

All the flat bones of the cranium were widely separated and connected only by membrane. The dura was adherent to the scalp in the opening between the bones. At the position of the anterior fontanelle there was an opening in the dura the size of a silver quarter. The brain was of normal size and consistency, and lay at the bottom of the greatly dis-

tended cranial cavity. The optic chiasm was normal. The pia mater is congested. Length of the fœtus was nineteen inches. The viscera were normal, and there was no abnormal length of the extremities.

*June* 28, 1894.

---

5. *Spinal cord from a case of Pott's disease.*

Exhibited by Dr. Burr.

The patient, an Italian, male, aged about 45 years, was admitted to the Germantown Hospital under the care of my friend, Dr. Willits, in May of this year. As he could not speak English, no history was obtained. His condition was then as follows: Complete paraplegia with contracture, the legs being immovably reflexed on the thighs, the thighs on the abdomen. Anæsthesia from the level of the umbilicus down. Some loss of control of bladder and rectum. The fixation of the knee-joints prevented determination of the condition of the knee-jerks. No spinal deformity. No pain in spine, nor caused by percussion of it. Marked universal emaciation. Arms normal. Later, bed-sore developed on sacrum, and shortly before death another on right heel.

Died September 24, 1894. Post-mortem. No spinal deformity. On cutting down on spine a large pocket of creamy pus (about a pint) was found under and to inner side of right scapula. The lamina of the vertebræ from the fifth dorsal to the upper lumbar inclusive were carious. The corresponding bodies were carious, crumbling easily under the knife, and filled with cheesy masses. The process was most extensive in the region of the fifth, sixth, and seventh vertebræ. The pus had not burrowed downward under the psoas muscle. The cervical meninges were normal. The dorsal and upper lumbar dura was surrounded by a thick inflammatory, cheesy exudate, which in some places was half an inch in depth. The inner surface of the dura was smooth, and no inflammatory adhesions connected it with the cord. Beyond marked compression the cord showed no lesion macroscopically. Brain normal. Lungs: miliary, tuberculous and marked pleuritic adhesions. Abdominal organs not examined. The case is of interest for the following reasons: The entire absence of spinal pain, either subjective or induced by percussion. The absence of deformity, which should have been marked with such decided destruction of bone. The probable explanation is that the disease pro-

gressed rapidly after he became bed-ridden, many months ago, and ceased to use the spinal column to support the trunk. The late period of life at which the disease developed, Pott's disease, as is well known, occurring far more frequently in early life. Clinically, the case presents well the difficulties in the way of making a differential diagnosis of primary myelitis and myelitis due to pressure from bone disease when the symptoms of bone disease do not appear.

Dr. Daland remarked upon the interest of the case owing to the entire absence of pain. He had seen the same in aneurism once or twice.

*September* 27, 1894.

---

6. *Two cases of spinal hemorrhage and a case of cerebral hemorrhage.*

Exhibited by Drs. Mills and Vandevoort.

Case I.—J. D., aged 37 years, colored, Philadelphia, laborer, married.

*Family history.* Negative.

*Personal history.* Always healthy, except an attack of rheumatism several years ago. Denies all venereal history. Uses tobacco and alcohol moderately, and was a hard worker.

*September* 5, 1894. Yesterday he carried twelve tons of coal in a basket, and afterward sat down on a doorstep to rest. In a few minutes he experienced a sudden pain in his back, and gradually lost power all over, falling in a partially unconscious condition. In about twenty minutes he was able to call for help, but was entirely unable to move any portion of his body except head and left arm.

On admission at 4.30 p.m. he was completely paralyzed, except left arm.

He was a large, well-built negro, of rather intelligent appearance. He lay flat upon his back. Respiration rapid, shallow, and entirely diaphragmatic; pupils about normal in size, and reaction sluggish; pulse good and temperature 97°.

His legs were spread apart and rotated far outward; the right arm was fully extended to the side; the left arm was abducted, flexed at elbow; the fingers semi-flexed, the whole hand hanging inward over the chest. He was unable to elevate the arm, to extend it at wrist or elbow, or separate fingers. He can flex arm at elbow with little assistance, and can, when the arm is so flexed by side, slowly abduct it.

There was tenderness on pressure at back of neck. Below second rib there is analgesia and anæsthesia over the entire body, except over the biceps of left arm.

*Reflexes.* All abolished, but epigastric.

*Secretion.* Urine retained, but bowels involuntary.

About seven hours after admission he had a sudden and violent pain in the back with a rise of temperature and delirium.

*6th.* Respiration 60, of the Cheyne-Stokes type, and purely abdominal, tympanites becoming excessive. He began to vomit yellowish material earlier in the day, later becoming brownish, with slight fecal odor. Died at 5.30 P.M.

*Post-mortem* made by Dr. Cattell twenty-four hours after death. A clot was found beneath the scalp, about three inches in circumference, its centre corresponding to the position of the posterior fontanelle. On removing muscles and laminæ the spinal canal was found full of dark fluid-blood, extending upward to about the fifth cervical vertebræ. The cord itself was apparently normal except two small, pigmented areas on its anterior surface in cervical region. At the junction of the bodies of the fourth and fifth cervical vertebræ there was found a rough, softened area, apparently the result of an old focus of disease. It was somewhat smaller than a nickel and not covered by dura mater.

CASE II.—J. G., aged 44 years, white, German, occupation unknown. Previous and family history unobtainable. Patient was admitted to the hospital by ambulance September 10, at 11 A.M. He was in a horribly filthy condition, having been brought from a low boarding-house on Front Street, and, although conscious, was unable to speak above a whisper. He was completely paralyzed below the second rib, including both arms, and over the same area there were both anæsthesia and analgesia. Over the outer canthus of the right eye there was a small ecchymosis. He could move the head easily from side to side, and no evidence of trauma could be found. Respiration rapid and shallow and entirely diaphragmatic, and temperature 96°; radial pulse unobtainable. Bladder distended.

*Reflexes* entirely absent.

*Pupils* normal in size and respond well to light and darkness.

He gradually sank till death, four hours after admission.

*Post mortem*, made twenty-four hours after death by Dr. Jamison. On cutting away the muscles of spinous processes those of the first and fourth cervical vertebræ were found deviated to right, and a separation existed between the fourth and fifth which admitted end of finger. There was hemorrhage into the muscles around and below the luxation.

A large quantity of liquid-blood escaped through an opening made in the canal. Surrounding the dura was a small amount of clot. On removing the cord and cutting through the dura there was found a distinct softening and dark-brown decoloration at seat of luxation. Transverse section of cord one inch above seat of lesion showed a small hemorrhage and central softening, while one inch below the section showed complete softening and a mixture of cord-substance and blood. One and one-half inch lower the cord was normal.

Case III.—F. R., aged 71 years, white, German, single. Admitted September 30, 1894. Personal and family history unobtainable. Brought to the hospital by ambulance about 5 P.M. Had had a stroke twenty-four hours previous. He was very thin and wrinkled, with lost kyphoskoliosis. There was a right-sided hemiplegia with some drooping of same side of mouth and face; the head was turned toward the left side, as were also the eyes. Pupils normal in size; reacted to light. Respiration labored, but regular. Left radial pulse was full and soft, while right was small and thready. No anæsthesia or analgesia. He was in a partially unconscious condition, and remained so until a few hours before death, which occurred seventy-two hours after admission.

*Post-mortem*, made twenty-four hours after death by Dr. Cattell. When the brain was removed and placed on its basal surface, fluctuation could be detected over the greater portion of the left hemisphere. On opening the latter the whole parietal lobe and part of frontal and temporal were disorganized, and consisted of masses of blood-clot and brain tissue. The blood extended to within one-quarter or one-half inch of surface of brain.

Dr. Mills: The case of erosion of the vertebræ was interesting in connection with Thorburn's studies of *Injuries of the Cord.* This man had a peculiar position of his arm, holding it upward and forward, suggesting a lesion at a certain height of the cord. Everything was paralyzed in one arm and all except a few muscles in the other arm. The whole canal was full of blood outside the cord, up to the height where Thorburn's symptom would be produced.

The case of cerebral hemorrhage was interesting. It looked like an ordinary hemorrhage from the artery of cerebral hemorrhage. But this one broke into the ventricle secondarily. *September* 27, 1894.

### 7. *Cerebellar abscess.*

Exhibited by Dr. LINCOLN and Dr. MCFARLAND.

Through the kindness of Dr. D. J. Milton Miller I am permitted to present the following case:

M. H., aged 27 months. Family history negative.

*Previous history.* Quite well until two months ago, when she had pneumonia. She has had a running ear for about a year, which, however, caused no ill effects and stopped occasionally until at the time of the illness mentioned. An abscess formed in the lower mastoid region and was opened by the attending physician. Since that time it has been discharging continuously. The child was admitted for this, and transferred to the medical ward, because of the symptoms of meningitis. Upon admission she had a temperature of 104°, respirations 15, pulse 120 and full. She had convulsive seizures affecting the arms and legs and sometimes the whole body. Had severe pain and gave forth a peculiar, squeaky cry, not the "hydrocephalic cry." No running at that time from the ear. These symptoms continued, increasing in intensity until her death.

*Post-mortem notes.* Body of a small, emaciated female child. Upon the exterior of the body nothing of interest could be seen except a deep incision over the mastoid process of the left temporal bone. This incision was of some days' standing at least, and gave evidence that pus had been discharged through it. The left ear was plugged with cotton and also was the outlet of a purulent discharge.

The examination of the thoracic viscera showed them normal.

The abdominal viscera were also normal, the only item of particular interest being two slight intussusceptions such as are common in children, and, being dissociated with inflammation or congestion, are probably produced during agony.

The brain was of particular interest. On removing the calvarium considerable difficulty was experienced because of the firm adhesion between it and the bone. The membranes were not particularly congested, and the brain-substance—pia mater covering it—did not seem particularly congested. As the brain was turned back for removal, the moment the knife severing the cranial nerves pierced the left falx cerebelli there was an escape of horribly fetid pus, which continued welling up from the left posterior fossa of the skull until the cord was severed and the brain removed. The pus was then found to have its origin in

a cavity the size of a large walnut, excavated from the left lobe of the cerebellum. Whether this cavity was broken open accidentally or was already open it is impossible to say. The manipulations were done with extreme care, but the tissue was so softened and infiltrated as to make it a matter of doubt.

A probe introduced into the mastoid process through the external wound above mentioned found necrosed bone. When passed into the foramen of the temporal bone it could not be made to communicate with the exterior, but as the pus discharged from the ear and the wound was of the same offensive character, it is probable that the abscess evacuated itself through this channel. The probe passed through softened tissues into the posterior lacerated foramen of the skull, but did not communicate with the exterior.

Microscopic examination of the pus showed immense numbers of a small bacillus, probably the bacillus pyogenes fœtidus, and a large diplococcus. As no culture media can be kept at the hospital, I was unable to determine exactly what the bacteria were.

The case is of chief interest from a surgical point of view, as the trephine would probably have saved life.

Dr. Abbott spoke of the interest of the case from a pathological standpoint. These abscesses may be due to pneumococcus, streptococcus, or anaërobic micro-organisms. He has himself seen an abscess due to a hitherto unknown anaërobic organism. Middle-ear abscesses may be caused by the pneumoccocus. In a case of knee, hip, ear, and brain abscess of Dr. J. H. Lloyd's he found streptococci.

*January* 10, 1895.

---

8. *Tubercular tumors of cerebellum.*

Exhibited by Dr. M. H. Fussell.

Marie L., aged 3 years. When seven months old she had measles. Ever since that time has been peculiarly liable to bronchitis, and gets asthmatic attacks with this bronchitis. In September, 1892, she had scarlet fever. Christmas, 1892, she became sick, and has never been well since. She never was playful. She was weaned at eighteen months, and ate but little except milk before that age. After weaning the appetite improved, and finally became voracious. In March following the scarlet fever the right ear discharged puru-

lent matter, and has continued ever since. In the summer of 1893 she seemed entirely well, but in October, 1893, she began to complain of pain in her head. The pain is paroxysmal and generally worse at night, when she complains bitterly and appears in great distress. In January, 1894, she began to lose power in her legs, which weakness has steadily increased, and she has not walked for seven weeks. Never had any convulsions. Eyes never crossed. In January, 1894, speech was stammering. Spine normal. Pupils react to light, but oscillate. Patellar reflex cannot be developed. Dr. Randall reports purulent inflammation of right ear; no mastoid swelling. Eye-grounds. Neuro-retinitis with tortuous vessels. The patient gradually failed.

The patient finally lost entire control of both legs and arms. The head visibly increased in size; the fontanelles and sutures separated. She developed an irregular fever and died comatose in April, 1894.

She had been seen by various men and as many diagnoses decided upon, the final diagnosis being a meningitis due to middle-ear disease and an increasing consequent hydrocephalus.

*Post-mortem.* Marked emaciation. The fontanelles and sutures are widely separated, at least a finger's breadth. The entire lambdoidal and sagittal sutures are separated at least one-half inch. The scalp bulges over this separation. The bones can be separated easily by merely cutting the scalp. The longitudinal sinus is free from clots. There is a marked increase of the cerebro-spinal fluid. There is no meningitis except over one tumor to be described. In the right lobe of the cerebellum there are two hard tumors the size of a walnut and hazelnut, respectively. In the left lobe is a third tumor of the same character as large as a hickory-nut. The ventricles of the brain are much distended and filled with liquid.

On section the tumors are filled with myriads of tubercle bacilli. The sections I owe to the kindness of Dr. A. O. J. Kelly.

*March* 14, 1895.

---

9. *Sections of multiple neuritis.*

Exhibited by Dr. J. Reisman.

In presenting these sections I wish to say a few words on the pathology of multiple neuritis.

Multiple neuritis affects peripheral parts of the nerves, usually symmetrically. The nearer we approach the spinal cord the less marked

are the morbid changes. These changes are of two types—parenchymatous and interstitial. In the parenchymatous form we note a degeneration of the nerve-fibres, consisting in a breaking up of the myelinic sheath into smaller and larger droplets, with an eventual degeneration of the axis-cylinders, which swells, becomes beaded and vacuolated, and breaks down into granular débris. The interstitial type presents the characteristics of true inflammation, *i. e.*, the connective tissue of the nerve-fibres is the seat of a round-cell infiltration, the vessels are dilated and hyperæmic, and there is an out-wandering of leucocytes. Strictly speaking, it is only this form that merits the name neuritis, yet it is a general custom to apply this term also to that in which there is chiefly a degeneration. Multiple parenchymatous degeneration would be a more exact and hence preferable designation. It is to be noted, however, that in many instances both forms are combined, which is but natural. The inflammatory process, on the one hand, leads to degenerative changes in the fibres, by pressure and by interference with the blood-supply; while in the parenchymatous form the broken-down tissues act as irritants and set up an inflammatory reaction. The degenerative form is most common, and is that which is seen in the majority of cases of so-called alcoholic multiple neuritis as well as in other varieties of toxic origin. Sometimes, however, toxic neuritis is chiefly interstitial, as in an instance that occurred in the service of Dr. Lloyd at the Philadelphia Hospital, which he and I have reported. In that case two factors were causative of the neuritis—alcohol and septicæmia. The distribution was not quite symmetrical, or, rather, while the distribution was symmetrical, the nervous phenomena were not, there being more marked wasting and paralysis on the left than on the right side. The sections of the nerve showed a great increase in the interstitial tissue, together with a moderate decrease of the nerve fibres. In the cases in which Ross and Berry describe the microscopic findings the changes were both parenchymatous and interstitial.

In the specimens which I show here and which are stained after Pal's modification of Weigert's method, the process is strikingly parenchymatous. In longitudinal section, in which the alterations are more manifest, the myelin is seen to be broken up into oval segments or into large granular masses, or, again, into irregular heaps of variously sized granules. In places the appearance is that of a string of black beads attached to each other in a chain. Some of the degenerated fibres can be traced for a distance, then disappear entirely. In several sections isolated axis-cylinders are seen, running, as well-defined threads among the myelinic fibres. There is no round-cell infiltration; the blood-

vessels are not dilated nor increased in number. Although some of the capillaries are well filled with red corpuscles, they are not surrounded by out-wandered white cells. In certain places the nerve-fibres seem somewhat widely separated, but not because of any new formation of interstitial tissue. The transverse sections do not show the degenerative changes so markedly; where they are seen they consist of a disappearance of the myelin from those of the fibres and a granular condition of that which remains. The portions so affected reveal themselves by a lighter staining than the normal areas. *June* 27, 1895.

## VIII. TUMORS NOT OTHERWISE CLASSIFIED.

### 1. *Retroperitoneal sarcoma.*

Exhibited by Dr. M. H. Fussell.

The person from whom this specimen was removed was a patient of Dr. George Stiles, of Conshohocken, to whose kindness I am indebted for the opportunity of demonstrating the specimen. I never saw the patient while living, but performed the autopsy.

*Clinical history.* This is very brief. The patient, a male, aged 40 years, was seen by Dr. Stiles. He had a large mass on the left side of the neck, in the lower anterior triangle. The mass had grown rapidly, and was painless. Dr. Agnew diagnosticated a sarcoma and suggested an abdominal examination. This revealed a large, firm mass to the left of the median line and on a level with the umbilicus. The growth in the neck was looked upon as secondary to the abdominal mass, and operation advised against. The man went about his business as usual, suffering absolutely no discomfort from the abdominal growth.

After the lapse of two or three months the growth in the neck became inflamed and very rapidly softened. At the same time the growth in the abdomen became less distinct.

Dr. Agnew was again consulted, and opened the now large abscess in the neck. From the cavity a half-pint of fetid pus escaped. The wound was drained and did well. Suddenly, about one week after the abscess-cavity was cut, the man passed a large amount of blood from the bowel and died in collapse.

Section forty-eight hours after death. Body of a well-preserved male. There is a cut in the left lower cervical triangle, the seat of the surgeon's puncture. Chest: The heart normal. The left chest partly filled with a sero-purulent liquid. At the apex of the chest there is a perforation through the pleura, communicating with the cavity of the abscess on the neck. The walls of this latter cavity show no signs of infiltration. In the abdominal cavity is a mass straddling the vertebral column, rather more to the right than to the left. The small intestines are adherent to this mass in several portions. In the upper part the jejunum is tightly

adherent, and over the point of attachment there is a large perforation into the bowel the size of a silver dollar.

The sarcoma had softened and ruptured with the gut. Microscopical examination of the tumor shows typical sarcomatous tissue.

Retroperitoneal sarcomata are rare. But two specimens have been presented to this Society since its beginning—Dr. William Osler and Dr. James Tyson having presented the growths. In Dr. Osler's case the same necrotic change had taken place as has occurred in the specimen presented to-night. Dr. Tyson's case was not diagnosticated before death. *November* 9, 1893.

---

2. *A series of cases of intrathoracic tumors.*

Exhibited by Dr. Alfred Stengel.

The existence of various forms of intrathoracic tumors has been recognized since the time of Boerhaave. Within recent years several monographic contributions, notably those of Hare, Strauscheid, and Stevens, have dealt with this subject. The varieties of tumors observed included sarcoma, lymphadenoma, carcinoma, fibroma, lipoma, enchondroma, osteoma, dermoid and hydatid cysts, and the rare variety described by Virchow under the name of teratoma myomatoides. The epitheliomata may be reckoned with the carcinomata; the endotheliomata with the sarcomata. Of all these forms, the cancers, sarcomas, and lymphatic tumors alone occur with sufficient frequency to merit great consideration from a clinical point of view. Regarding the frequency of the different varieties, particularly carcinoma and sarcoma, much difference of opinion exists; but recent observers are united in declaring sarcoma the most frequent form, though the statistical articles of Hare, Strauscheid, and others still make carcinoma the most frequent form. It may be noted that in Hare's monograph 61 of the cases of cancer were reported before 1870 and 41 after that date, while the date of 32 is not stated; of sarcoma, only 3 were reported before 1870 and 66 after that year, and in 24 the date is not given. It is apparent, therefore, that cancer was recorded as the most frequent form at the time when the distinction between carcinoma and sarcoma was not drawn with accuracy; while the sarcoma had become almost the prevailing form subsequent to that time. It occurred to me that a careful consideration even of older literature might lead to a more accurate tabulation, de-

spite the name used in reporting the cases, and therefore I studied with care 25 of the older reports in which the respective authors had used the name cancer, with the discovery that 13 were undoubtedly sarcoma from the description given, while in 12 it was difficult to decide from the evidence. In only one or two cases was it likely that the tumor described was really carcinomatous. A review of the entire literature undertaken with this object in view would be too wearisome and unprofitable.

Regarding the point of origin of tumors, it may be noted, in the first place, that the anterior mediastinum is involved three or four times as frequently as the posterior, and it is usually not difficult to decide upon the structure from which the tumor took its origin. Virchow pointed out that the tumors of the thymus gland are characterized by a uniform outline, while those springing from the lymphatic glands are irregular in shape and nodular. New growths arising from bony tissues of the chest-wall are easily classified. I believe that a great majority of the cases of tumor of the anterior mediastinum arise from the thymus, as Letulle and other French writers maintain. The atrophic thymus furnishes a favorable soil upon which a new growth may implant itself. One of the cases at least that has come under my observation (Case I.) was an instance of this kind, and others not included in this series have presented similar features. Practically, all the tumors of the thymus are lymphadenomatous or lympho-sarcomatous, though Letulle, Danzae, and Hortsmann have described epithelial growths springing from the epithelial remnants in the thymus. Other forms are equally rare.

The tumors springing from the lymph glands are generally lympho-sarcomatous, and may reach considerable size. In the posterior mediastinum secondary carcinoma of the lymph glands occurs, as in Case III. of this series; but such secondary cancers rarely grow to notable dimensions.

Tumors of the lung may invade the mediastinum or may be practically mediastinal in their manifestations. Carcinoma may occur, but is less frequent than sarcoma, involving the peribronchial glands at the root of the lung and the nodes of lymphoid tissue within the lung surrounding the root of the bronchi.

Of the tumors springing from the pleura and secondarily involving the lung or other structures, primary endothelioma is of particular interest, and one of the cases reported below belongs to this category. I do not hesitate to group it among sarcomata, as it undoubtedly springs from the endothelium, which I believe is mesoblastic despite the view of Hertwig. Probably most of the cases recorded in literature of primary

cancer of the pleura are of this character. Another form of sarcoma of the pleura is that which has been found by Coots, especially in children. It springs from a subpleural tissue, and is fibro-sarcomatous in nature. Other tumors of the pleura are unimportant.

Sometimes œsophageal tumors may reach such size as to become clinically significant, aside from their effect on swallowing, and they may invade the surrounding structures of the posterior mediastinum. No such case has come under my notice.

For clinical purposes I have become accustomed to divide the tumors into those invading the anterior mediastinum, in which physical signs are usually prominent; those involving the middle and posterior mediastinum, in which marked symptoms may precede or overshadow the physical signs; and those springing from the lung or pleura, in which physical signs and symptoms may be more or less equally pronounced.

Case I.—The following case is one of primary sarcoma of the thymus gland, in which, however, at the stage at which it came under observation extension had taken place to the neighboring lymphatic glands, to the posterior mediastinum, and to the abdominal lymphatic nodes. There was also a complicating pleural effusion of dropsical character. The diagnosis was readily made by the distended veins, clubbed fingers, enlarged glands of the neck, the palpable tumor in the suprasternal fossa, and the physical examination of the chest. Unfortunately the history was not obtainable, and the progress of the symptoms could not be ascertained.

G. B., a Hungarian lad, aged 20 years, was treated in the wards of the University Hospital during December and January, 1893–94. The patient was under the care of Dr. William Pepper, to whose courtesy I owe the pleasure of reporting the case. It was impossible to get from him any intelligible statement of his previous health or of the progress of the illness which brought him to the hospital. He was a miner, and had been at work in the anthracite coal-mines of Eastern Pennsylvania as late as October, 1893. He stated, however, that he had been ill for six months before he entered the hospital, and that he had suffered principally with shortness of breath.

The following notes were recorded at the time of his admission:

*Inspection.* The patient presents a remarkable appearance in his features and posture. The eyes are somewhat protruding, the face is puffed, patchy flushing is noted from time to time about the cheeks and chin, and the forehead is covered with large sweat-drops. The neck is swollen, and its circumference just above the clavicles is decidedly greater than that above. The posture habitually assumed is one in

which the patient leans forward and to the right, resting his weight on the right elbow. At first sight he has the appearance of a kyphotic; but there is no curvature of the spine, excepting that the lumbar portion is rather convex than concave. The veins of the neck, upper thoracic region, and lateral portions of the abdomen are greatly distended. The hands are cold and cyanotic; the fingers are club-shaped. The sternum is prominent above, and the lymphatic glands of the neck project as knobs. The antero-posterior diameter of the body is everywhere greater than the lateral.

*Percussion.* The percussion-note over the right lung is hyper-resonant anteriorly and posteriorly. Liver-dulness begins at the sixth rib. The left thorax is also hyper-resonant above, but below a line passing through the nipple and angle of the scapula the note is dull. This dulness is movable and evidently due to fluid. In the central part of the chest is found an area of dulness bounded to the right by a line running from clavicle to liver-dulness, one-half inch to the right of the sternum; on the left by a diagonal line extending from the clavicle one-half inch outside the sternum downward to a little beyond the left nipple, then vertically downward to the seventh rib and horizontally over to the liver-dulness. This area is resistant and completely flat on percussion. There is cardiac pulsation somewhat below the usual point, and not distinct.

*Palpation.* The apex-beat is discernible only as a diffuse or indefinite jogging in the situation indicated. Vocal fremitus is distinct everywhere over the right lung. On the left side it is exaggerated above the mediastinal dulness and the pleural effusion before indicated.

*Auscultation.* The breath-sounds on the right side are soft and prolonged, especially the expiration; occasionally sonorous râles accompany the latter. On the left side the breathing is exaggerated, except at the lowest point of pulmonary resonance, where there is distinct bronchial breathing. The heart-sounds are weak and muffled. The second sound is accentuated at both pulmonic and aortic cartilages. There is no murmur. The radial pulses are extremely tense and cord-like, but are compressible. There is no atheroma. The pulse-wave is quite vigorous and decidedly more so on the left side.

Examination of the *superficial glands* shows them to be enlarged in various situations. In the neck are found a large number of separately enlarged nodes, but in the lower part of the neck, on the left side, is found one group of glands fused homogeneously. The axillary glands are similarly enlarged and the epitrochlear very slightly. Deep palpation in the suprasternal fossa reveals a globose mass behind the manu-

brium. This has the faintest trace, if any, of pulsation. There is no tracheal tugging.

The examination of the *blood* showed 2,930,000 red corpuscles, 9370 leucocytes, and 55 per cent. hæmoglobin. There were more than the usual percentage of eosinophiles and lymphocytes, and the red corpuscles were quite irregular in size.

Examination of the *urine* showed: Sp. gr. 1026; acid; no albumin; no sugar; deposit of amorphous urates.

The *abdomen* was greatly distended by tympany, and on firm palpation there seemed to be an intra-abdominal growth high up. This could, however, not be accurately determined.

On December 27th the note reads: Cardiac impulse to-day is very marked at the xiphoid cartilage. The patient has been growing more uncomfortable, and dyspnœa is increasing.

On January 1st it was noted that the dulness at the lower part of the left chest had increased and was distinctly movable. It was also noticeable that the veins of the chest became distended during expiration and collapsed during inspiration.

On January 11th the feet and legs were very œdematous. Orthopnœa was growing decided. The abdominal walls were distended by tympany and the mass within. The venous network on the front of the chest was very pronounced. The arms were livid. The left pulse was distinctly fuller than the right; the pupils were equal and reacted normally to light.

On January 12th distinct leucocytosis was noted, and there were many microcytes and macrocytes, but the exact blood-count was not recorded. The temperature-chart has unfortunately been lost, but there were frequent slight elevations, and toward the end of life there was almost constantly some degree of fever.

*Autopsy.* On opening the thoracic cavity a large tumor was found, occupying mainly the anterior mediastinum. This was somewhat irregularly nodulated and lobulated, and extended over the root of the great vessels and heart, much like a bell or cap. The lower surface was intimately attached to the pericardium, but the inner surface of this membrane was perfectly smooth and not involved in the growth. (Fig. 1.) The mass enveloped all of the great vessels, together with the trachea, and, to a less extent, the œsophagus, the bronchi, and the nerves of the posterior mediastinum. It extended backward on each side over and around the bronchi and vessels at the root of the lung, particularly on the right side, and was continuous with a smaller and somewhat denser growth in the posterior mediastinum, which extended downward to the diaphragm.

None of the vessels were completely occluded, but the right innominate vein was greatly compressed. In the posterior mediastinum the œsophagus, aorta, nerves, and veins were all surrounded by the mass. On a closer examination the growth anteriorly was found to contain numerous areas of softening and of cystic formations; the former containing cheesy material, and, in some places, calcareous particles quite abun-

Fig. 1.

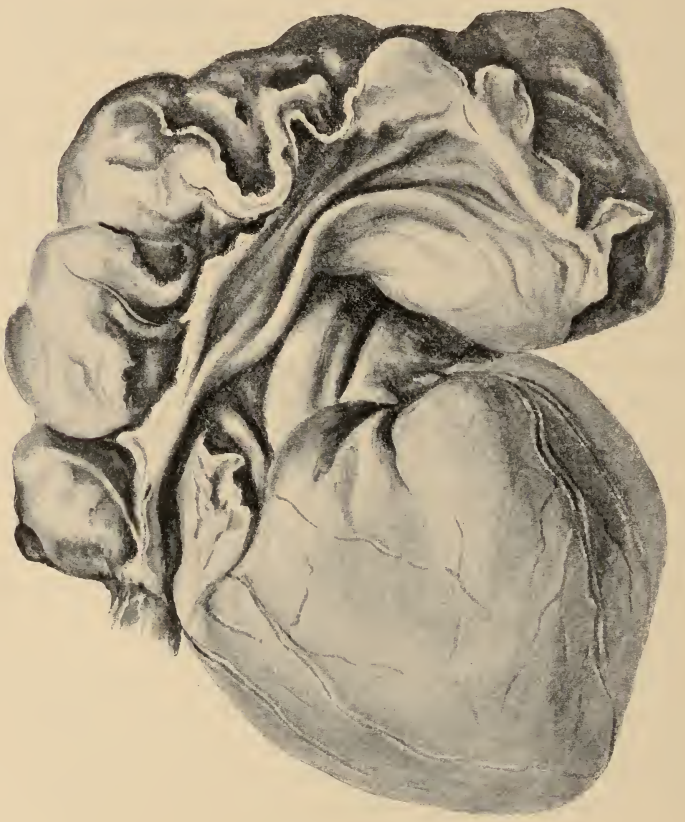

dantly, and the latter areas a dark, grumous liquid. The left pleural cavity contained a considerable quantity of clear, serous liquid, but there was no involvement or inflammation of the pleura itself. The left lung was somewhat compressed and œdematous. The right pleura and lung were normal. The abdomen contained a second and huge growth, which occupied the upper portion of the cavity and was situated, for the most

part, behind the peritoneum surrounding the aorta and its branches, and the vena cava as far down as the iliac branches. The greatest mass of the tumor, however, was above. It extended, also, forward to the root of the mesentery and surrounded some of the coils of intestine. This tumor was lobulated and presented an appearance like that of greatly enlarged lymphatic glands which had softened and undergone some calcareous deposition.

*Microscopical examination* of portions of the large mediastinal mass and of fresh nodules on the outer wall of the pericardial sac showed small, round cells with delicate fibrous stroma. The tumor may be regarded as a round-celled or lympho-sarcoma.

Case II.—M. K., aged 75 years, was admitted to the medical ward presenting the following conditions: She was much emaciated and of an extremely anæmic appearance. The striking and practically the only symptoms were extreme dyspnœa and restlessness. The patient lay on the side, but moved continually from one side to the other. Physical examination revealed marked dulness over the anterior part of the left chest, with diminished respiration. There was a systolic cardiac murmur and apparently hypertrophy of the heart. There was no particular change in the symptoms, and the patient soon expired.

*Post-mortem.* The pericardial and pleural sacs were normal; the heart was enlarged. At the root of the left lung was found a mass of solid tissue pressing upon and enveloping the left bronchus. This mass was continuous, with similar new growth enveloping the trachea and other structures of the posterior mediastinum. On section the tumor was found to be composed of a mass of altered lymphatic glands; it was of a gelatinous appearance, and exuded a viscid, milky liquid. Numerous small nodules were found in the pericardium and pleura of the left lung adjacent to the tumor. Microscopic section showed this to be a lymphosarcoma.

Case III.—The next case was one of secondary cancer of the glands of the posterior mediastinum, in which the symptoms and physical signs were scarcely marked enough to warrant a diagnosis, and, indeed, this had not been made. The dyspnœa did become quite extreme immediately before death, but there was a high grade of cachexia and asthenia, and there was neither any stridor nor any definite physical sign of tumor.

X. Y., an old lady under observation with symptoms pointing to cancer of the stomach, was noticed to become more and more dyspnœic and to have more or less cough. Physical examination failed to reveal any condition of the heart or lungs likely to produce these symptoms, but it

was observed that the respiratory murmur was decidedly lessened. This was as marked on one side as on the other. She was emaciated to an extreme degree, and soon died of exhaustion. At the autopsy a large pyloric carcinoma with dilatation of the stomach was discovered; and there was a mass of large lymphatic glands the size of a large apple in the posterior mediastinum at the roots of the lungs. The bronchi were pressed upon, but not seriously, and there was no involvement of the other structures. Microscopic examination of the gastric tumor and of the mediastinal glands confirmed the diagnosis of carcinoma.

Case IV.—In the following case the tumor had evidently begun in the posterior mediastinum, but at the time it came under observation the symptoms of a complicating pleural involvement and of pleuritic effusion were even more pronounced than those of the original mediastinal disease. Definite aid was rendered in the diagnosis of this case by the swelling of one of the ribs and by the removal through aspiration of intensely hemorrhagic liquid. The case was seen by Dr. William Pepper in consultation with Dr. J. L. Forwood, of Chester, and through the courtesy of these gentlemen I present the specimens.

Mr. D., aged 54 years, had been a good liver. There was no specific history. His illness began insidiously about seven months before he came under observation, and developed progressively. The main symptoms were progressive dyspnœa, increased by exertion; cough of a somewhat paroxysmal character, and later intense pain referred to the side and upper part of the left chest. The sputa were sometimes bloody. Emaciation was moderate, but there was marked pallor, though no distinct cachexia. The temperature was little, if at all, elevated. There was little sweating. Toward the close of his life the position of greatest comfort was sitting upright and leaning well forward. A painful swelling of the fourth left rib in the axillary line appeared about two months before death.

Physical examination, shortly before death, showed mark impairment of expansion of the upper part of the left chest. The heart was somewhat but not greatly displaced, and was apparently normal. The enlargement of the rib was visible and palpable, and was the seat of pain and tenderness. It seemed firm to the touch. Over the upper lobe of the lung, both front and back, there was great decrease of the vocal fremitus and resonance, with absolute flatness on percussion and an extremely weak respiratory murmur. Over the lower lobe of the lung the percussion was full and the breath-sounds were almost normal. The right lung seemed entirely normal. There were no physical signs pointing to aneurism. Exploratory puncture of the upper part of the left

pleural sac was performed, and marked hemorrhagic fluid was withdrawn. This was submitted to microscopic examination, but no distinctive elements were discovered. Death occurred soon after this time.

The *autopsy* was performed the day after death. The swelling and bulging of the fourth rib were still quite apparent. On opening the thoracic cavity there was found a considerable quantity of bloody liquid in the upper part of the left pleural sac. The lung itself was pressed downward and against the chest-wall. It was soft and œdematous, and was easily torn by the fingers in the attempt to remove it. Opposite the external swelling alluded to there was a mass of tumor-tissue which had involved the rib and invaded the pleura and lung within. The rib itself was somewhat eroded and brittle. The tissues of the chest-wall were considerably infiltrated as far outward as the superficial muscles and for an inch or more around the point of greatest bulging. The lungs were removed together and with the heart attached. There was then discovered a mass of tumor situated at the root of the left lung and extending around the descending aorta, trachea, and other structures of the posterior mediastinum. In particular, however, this tumor invaded the substance of the left lung as a dense white mass, marked in numerous places by darkly pigmented lymphatic glands. Many of the latter were involved in the disease, but some were apparently healthy and merely surrounded by the growth. The edge of the tumor where it merged into the lung-tissue was rather sharply defined, but did not show any evidence of the formation of a capsule. The lung-substance was so compressed and œdematous as to present the appearance of a pulpy mass. Posteriorly and laterally the mass approached the surface and involved the pleura; and it was in this way that the attachment to the fourth rib and its involvement had taken place. Some of the glands at the root of the right lung were involved, but there was no extension of the disease into the lung-substance. The outer surface of the pericardium was involved, but within the membrane was healthy. The heart and other organs were not invaded. A large calculus was found in the pelvis of the left kidney, also a quantity of gravel.

The tumor, though it surrounded the bronchus of the left lung, the trachea, and to a large extent the aorta, did not cause serious compression of any of these structures.

*Microscopic examination* of the growth showed it to be lymphosarcoma.

Case V.—The following case was under the care of Dr. Thomas P. Tyson, of Jenkintown. It did not come under my observation during

life, but by Dr. Tyson's courtesy I was permitted to make the post-mortem examination and to give the following report:

J. McC., a lad, aged 13 years, had been ill for several months before his death. He had complained of great loss of strength and had a persistent cough, with more or less shortness of breath, but with little expectoration. In addition he had suffered much pain in the right chest, especially in the upper part. The illness seemed to follow directly upon an injury of the upper part of the chest, in the situation indicated by the pain. Previous to the time of this injury the boy had been healthy, but smoked cigarettes immoderately. The cough was most persistent and sometimes distinctly paroxysmal; toward the end it was accompanied by more expectoration, the sputa being muco-purulent in nature. He became very much emaciated at last, but never presented a distinctly cachectic appearance. There was from the first considerable perversion of appetite. Physical examination revealed a swelling or bulging of the second rib of the right side about the anterior axillary line and engorgement of the veins of the neck. There was decided dulness on percussion over the upper part of the lung, with absence of breath-sounds. Below the lung was resonant, and moist râles and crepitation were discovered, accompanying harsh respiratory sounds. Percussion-resonance on the left side was full until shortly before death, and mucous râles were constantly present. These symptoms and physical signs continued with but little change until the boy's death; but the dyspnœa, later orthopnœa, and emaciation steadily increased. The temperature ranged from normal to 101° F., and the pulse from the first was rapid—110 to 120 per minute. The swelling of the rib and the persistent cough and dyspnœa led Dr. Tyson to diagnosticate sarcoma of the lung, and in this opinion he was supported by two consultants.

*Autopsy.* The external appearances were the same as above described. On opening the thoracic cavity there was found a considerable quantity of pleural effusion of a serous nature in both sides. Attached to and involving the third rib of the right side and invading the lung was a hard, white tumor about as large as a middle-sized orange. This was irregular in shape and bound the lung firmly to the chest-wall. There was no attempt at encapsulation. The rib was involved on the inner surface alone, but was thinned and pushed outward by the tumor. (Fig. 2.) Both lungs were densely studded with secondary nodes, varying in size from that of a marble to that of a plum. These were encapsulated and for the most part quite soft. A number of the larger were quite pulpy. All parts of both lungs were involved. No other organ appeared in any way abnormal.

*Microscopic examination* showed the tumor to be a round-celled sarcoma.

The injury sustained and the close involvement of the periosteum of the rib in this case allow the suspicion that in reality this was the point of origin. The pleura and adjacent lung were, however, more decidedly

Fig. 2.

involved, and the appearance of the specimen suggested outward extension. In addition, it is more likely that a round-celled sarcoma would spring from the pleura than from the periosteum, though the latter situation is sometimes the seat of this form of new growth.

Case VI.—E. J. B., aged 7 years, came under observation in May of 1894. He lived in a distant part of the city, and was placed under the care of Dr. Moylan, to whom we are indebted for the clinical notes. His previous health had been entirely good, but for several months previous to May, while attending school, he began to ail. Later, he complained of severe pain in the left side near the lower border of the ribs in front. His attendant at that time diagnosticated pleurisy, and evidently thought lightly of it, as the patient was permitted to continue at school. The pain was always aggravated by gastric derangement, particularly by flatulency, and the child continued to lose flesh and strength, so that the father was obliged to take him from school. He was sent to the seashore, but did not recuperate. When he first came under notice, in the middle of May, the child was highly emaciated. On physical examination the apex-beat was seen to be displaced almost to the right axillary line. The left intercostal spaces bulged, and there was almost complete absence of the respiratory murmur, with flatness on percussion from about the third rib downward. There was no fever. He had no appetite, and severe paroxysms of pain in the left side and loss of sleep aided in reducing his vitality. There was practically no cough or expectoration.

The child was put to bed and carefully fed. Heart-tonics were administered, and after a few days an exploratory puncture was made with negative results. Sarcoma of the lung and pleura was now diagnosed by exclusion, but a resection of the rib was performed, and the diagnosis was completely confirmed. The operation was performed in the hope that it might prove otherwise. The child's condition deteriorated steadily, and he died a few days later.

At the *autopsy* there was found a rather circumscribed, whitish, soft tumor of the antero-lateral portion of the base of the left lung. This was about the size of a small orange; in places it seemed almost encapsulated, but in front it was firmly attached to the sixth rib, and invasion of the intercostal spaces had occurred. Above and inward the lung bordering on the tumor was highly œdematous, compressed, and pulpy. There was some slight infiltration from the growth. The upper part of the pleural cavity contained a small amount of bloody fluid. All the other organs were normal.

The microscopic examination showed the growth to be a mixed sar-

coma. Most of the cells were small and round, but some were spindle-shaped or irregular.

As to the origin of this growth, there is undoubtedly some room for difference of opinion. In places it seemed to be covered with pleura, and this suggested the form of sub-pleural sarcoma referred to by Coots and others; but the centre of involvement seemed, on the whole, rather to be the pleura itself, with extension inward to the lung, on the one hand, and outward to the periosteum of the rib and to the intercostal tissues, on the other hand.

The case is of interest also from the early age of the patient. This is not an unusual feature of intrathoracic tumors, however, as will be seen from the fact that Edwards has tabulated some 37 cases in his article in Keating's *Cyclopædia of Diseases of Children* and from my own experience. In three of the present series of cases the ages were, respectively, 7, 13, and 20, and I have seen a number of other cases in children of like age. Of course, the number becomes very considerable if instances of tuberculous disease of the glands of the chest are included.

Case VII.—The following case was under the care of Dr. A. Trau at the German Hospital. I wish to express my thanks to Dr. Trau for the privilege of reporting it and to Dr. Hand for the clinical notes.

H. S., a German clothier, aged 38 years, was admitted to the German Hospital April 15, 1893. Little was learned regarding his family history, except that one brother died of phthisis.

He had typhoid fever when 13 years old, but with the exception of an attack of malaria in 1881 he remained healthy until about eight months before his entrance into the hospital. About that time he began to suffer with pains in the back and a cough. He was not confined to bed and did not consult a physician. The cough was attended with little expectoration. Physical examination at the time of his admission to the hospital showed the following: The apex-beat of the heart was displaced to the right of the sternum. The right lung was clear. On the left side there were flatness on percussion, absence of fremitus and of the breath-sounds from the base as high as the third rib. Above this there were bronchial breathing and an almost tympanitic percussion-note. For some time after he came under observation severe pain was felt in the region of the left shoulder. There was no elevation of the temperature, and the patient was pallid, though not cachectic.

On May 2d seventy-four ounces of blood-stained serum were drawn off. A half drachm of this was injected beneath the skin of a rabbit, causing an abscess and death in four weeks, with no other discoverable lesion. Pus from the abscess was examined for tubercle bacilli, with negative result.

*3d.* There was little change in the physical signs following the aspiration.

*20th.* Eighty ounces of grumous blood and serum were withdrawn. Some of this was injected into the peritoneal cavity of a rabbit, and death occurred a month later. Nothing, excepting some coccidial nodules in the liver, was discovered.

FIG. 3.

*24th.* The pleural cavity filled again with fluid, and a drainage-tube was inserted.

*June 27th.* The case was now transferred to Dr. G. G. Davis, and a rib was resected. Following this the patient's condition grew steadily

worse. Violent cough, with slight expectoration, progressive emaciation, and continuously afebrile temperature preceded death, which occurred on July 26th.

*Post mortem.* The body was wasted to the last degree. In removing the superficial tissues it was found that the left pectoral muscles and the overlying skin were tightly bound together and to the chest-wall, and were infiltrated with white nodules. There was some pericardial effusion. The heart was pushed so far to the right that its centre lay under the right border of the sternum. There was a large effusion in the right pleural sac, with strong pleural adhesions. On the left side the pleura was enormously thickened, the costal reflection being in places quite an inch in thickness.

The visceral pleura was almost equally thickened and was everywhere firmly attached to the compressed left lung. (Fig. 3.) The lung itself was infiltrated with numerous whitish-yellow nodules. These were most densely placed near the surface; most sparsely within. The left pleural cavity was distended with liquid similar to that obtained by aspiration. The pleura was very hard and of a glistening whiteness; the inner surface was in some places somewhat irregularly elevated and soft, but this was not the usual condition. For the most part the inner lining was smooth.

The right lung was filled with white nodules. A small nodule was found in the left suprarenal capsule and another in the right kidney; the other organs were unaffected.

The first impression conveyed by the appearance of the pleura was that of chronic inflammatory thickening. Nowhere in this membrane was there a distinct suggestion of nodular or tumorous disease, and only microscopic examination could have revealed the nature of the case. The secondary implication of the lungs, however, showed even to naked-eye examination that there was something more than pleurisy, and the involvement of the chest-walls left little doubt that this was of the nature of a new growth. The microscopic examination revealed long columns of cells with more or less perfectly developed or preserved lumina (see Fig. 4). The cells composing these columns were large and of epithelioid character. In many places, as the illustration shows, there was a decided cylindrical character of the limiting cells, while those within presented irregular shapes. The nodules within the lung were similar in appearance, though the acini were not so much elongated. There could be no doubt at all in this case that the pleura was first involved, as the invasion of the right lung was unquestionably secondary, the pleura not being involved at all on that side, and the

appearance of the left lung being exactly the same, except that the nodules near the periphery merged into the diseased pleura.

Fig. 4.

Enough has been said regarding the nature of this growth before. It is best designated by the term endothelioma, and we would include it in the group of sarcomata. *December* 14, 1893, *et seq.*

---

3. *Three cases of intrathoracic tumor; cystic substernal goitre; sarcoma of anterior mediastinum; primary endothelioma of pleura.*

Exhibited by Dr. Frederick A. Packard.

The following cases are reported partly on account of the features of contrast presented by them, partly because of various peculiarities that rendered them of much interest to the writer.

Case I. *Calcified cystic goitre in neck; cystic substernal accesssory thyroid gland forming a tumor in the anterior mediastinum.*—Frederick H., white, aged 69 years, a native of Germany, was admitted to the Episcopal Hospital on March 6, 1894. The family history is negative.

He was never ill except for the fact that in 1842 there formed a growth in his neck, which measured at the date mentioned twenty inches in circumference. It apparently yielded to treatment, and soon became reduced to the size shown on admission. When large it caused much dyspnœa and dysphagia. He has had more or less difficulty of breathing for the past thirty years.

In December, 1893, he had an attack of "influenza," and since then had been growing progressively weaker, and had had steadily-increasing dyspnœa with painful cough and muco-purulent expectoration. Œdema of the feet and ascites soon became prominent sources of inconvenience, and he also suffered much from serous diarrhœa and from headache.

I found the patient in the ward when I went on duty on July 1, 1894. The physical examination revealed the following conditions:

Patient decidedly emaciated; skin of an earthy hue; conjunctivæ quite white; pupils rather small but equal, reacting poorly to light, promptly on accommodation; temporal arteries tortuous, pulsating visibly, their walls decidedly thickened; tongue coated in some parts, very naked in others; the left side of the mouth appears to droop; mucous membrane of the mouth pale; on lower lip dilated venous radicles.

Examination of the larynx, made by Dr. Gibb, the laryngologist to the hospital, showed "sclerotic condition of mucous membrane of pharynx; larynx capacious; mucous membrane reddened; cords approximate normally, and are of normal appearance; subglottic portion of larynx and upper joint of trachea on the right side present a somewhat bulging appearance as though from external pressure." In the median line of the neck anteriorly there was a lobulated, firm, hard tumor, moving readily upward with the thyroid cartilage in the act of swallowing. It was quite firm to the touch with a cartilaginous hardness. It did not pulsate, nor was any murmur to be heard over it.

The veins on both sides of the neck were much distended, and the arteries in the neck were plainly visible in their pulsation. Crossing the clavicles at a point about one inch from their junction with the sternum were two large venous trunks extending downward by a tortuous course to the second costo-sternal junction, the blood-current being evidently downward. On the left side a large venous trunk was seen extending to the point of deltoid attachment in the left arm; it then coursed horizontally and then downward to join another enlarged vein. The

blood-current in this trunk flowed toward the median line of the body. Over the surface of the thorax were numerous dilated venous radicles, most marked in the upper zone and in the left hypochondriac region. Distinct pulsation was present in the first and second, slight pulsation in the third right intercostal spaces. The same pulsation was present in a corresponding area on the left side, but to a smaller degree. The veins on the dorsum of the left hand were slightly more prominent than were those on the right.

There was marked epigastric pulsation. The apex-beat was feeble and diffuse, the point of greatest intensity as well as that furthest downward and to the left being in the fifth intercostal space in the left mid-clavicular line. Cardiac dulness extended from the third rib in the left parasternal line, and from the mid-sternum at the level of the fourth interspace. At the apex there was a harsh systolic murmur well transmitted to the left. The first sound at the aortic area was decidedly "choppy" and short, but no murmur was present at this, the pulmonary or the tricuspid areas.

Pulmonary expansion was very poor, especially upon the right side. The percussion-note anteriorly was decidedly impaired over the left side. Posteriorly there was dulness on the left side from the level of the seventh dorsal spinous process downward to base. Over the dull areas the breath-sounds were very distant; vocal resonance much impaired. In regard to tactile fremitus nothing positive could be affirmed owing to the extreme weakness of the voice. Over the body of the sternum and running outward on either side beyond the parasternal lines there was flatness with much increase of resistance. The abdomen was distended, the skin slightly yellow in color. The right hypochondriac and the right upper umbilical regions were distinctly more prominent than were the corresponding regions on the left side. No enlargement of superficial veins of abdomen. On the right side three fingers' breadth below the costal margin and from the middle line to three inches to the right there was yielding resistance, sinking on inspiration.

The area over the mass was dull, the dulness being continuous with the area of liver dulness—presumably an enlargement of the liver as a whole. Splenic area of dulness not increased.

Examination of the urine showed a specific gravity of 1015, neither albumin nor sugar, and a sediment composed of oxalate of lime crystals and pus corpuscles.

The old man rapidly lost strength, chiefly from profuse and uncontrollable serous bowel-movements, and died on July 12, 1894.

A hurried examination of the body was made, the only portion that

could be investigated being the thorax, and of this the best that could be accomplished under the circumstances was the removal by the resident physician, Dr. J. C. Da Costa, Jr., of the mediastinal growth. This was a slightly lobulated, heavy mass of an irregularly-flattended cone shape. The anterior face presented the shape of an almost equilateral triangle, with sides measuring from eight to nine inches. Section showed that it was made up of large cystic cavities with firm, not collapsing walls, the tissue between the cysts being scanty in quantity and of a reddish color. The cysts contained a reddish-brown, rather glairy fluid, although in a few the material was more watery. Examination of the fresh fluid showed no formed elements, no hooklets, but a few cholesterine crystals in some of the cyst contents. It is much to be regretted that it was impossible to make a more thorough and careful dissection in order to determine the exact relations of the tumor and to study the formation of the collateral venous circulation. The mass removed had no visible pedicle, nor was it supplied by any large arterial branches.

Microscopic examinations of portions of the growth, kindly made for me by Dr. Riesman, showed the structure of thyroid-gland tissue with marked cystic degeneration. (Section shown under microscope.)

Tumors formed of thyroid tissue within the thoracic cavity are not rare. The greater number found reported in the literature of the subject are, however, of the variety described by Fodéré (Turin, 1792) over a century ago as "goitre en dedans." In these the tumor-mass is simply an extension downward of a portion of one of the lateral lobes of the thyroid gland. In the literature one finds a by no means small number of such intrathoracic tumors dating from the observation of Fodéré to the case last reported by Anthony Bowlby[1] at the Clinical Society of London. A large number of the cases from the literature, together with many original examples of this condition, are collected in the most excellent article by A. Wölfler.[2] A complete transitional series of cases could be arranged showing the progressive stages through which an ordinary goitrous thyroid lobe may leave the neck and finally attain a position within the thorax. The intrathoracic growth may be a simple continuation downward of goitre in the neck, or the cervical and intrathoracic portions may be demarcated by a sulcus; this sulcus may be composed of true parenchymatous thyroid tissue, or may consist simply of fibrous tissue. Wölfler suggests[3] that it can well be conceived that, if the intrathoracic portion becomes connected with the pleura by adhesions contain-

[1] Clinical Society's Transactions, 1895, vol. xxviii. p. 197.
[2] Archiv für klinische Chirurgie, 1895, Band xi. p. 182.
[3] Loc. cit., p 191, foot-note

ing sufficient blood-suppy, the stalk connecting it with the cervical portion might in time become thinned or destroyed, and adds that it is not improbable that an old cystic or calcified goitre would need but very little nourishment.

Another source from which intrathoracic goitres may arise is the presence of thyroid tissue congenitally present within the thoracic cavity. According to Wölfler[1] and others there are found within the thorax in the median line of the human embryo and in dogs, fowls, lizards, and some batrachia accessory masses of thyroid tissue. Wölfler observed instances of enlargement of the aortic thyroid nodules in goitrous dogs —a fact that has much bearing upon the case here reported—and that the larger the goitre the greater was the size attained by the aortic accessory glands.

It is, of course, a question that cannot be definitely decided whether the intrathoracic growth in this case was in truth a degenerated and cystic enlarged aortic accessory thyroid gland, or whether the formation of the mass was primarily in the cervical thyroid gland with subsequent downward progression into the thorax, formation of adhesions with surrounding tissues, and final disappearance of the connecting isthmus. From the appearance of the mass I should have supposed the former theory correct, and am still so inclined. Against this view is the history of reduction in size of his goitre, which may have been due to one portion of his cervical goitre becoming subclavicular and later substernal, and the fact that the anatomical investigation was not sufficiently thorough to establish completely the absolute independence of the growth from the cervical goitre. It should, however, be said that careful examination of both the cervical and retrosternal goitres was made in a thorough and leisurely manner after removal from the body, and that no trace of any separated pedicle or divided connecting isthmus of tissue could be detected. It is, therefore, probable that this was an example of true primary intrathoracic goitre resembling that observed by Wölfler in goitrous dogs.

An analysis of the cases of this and analogous conditions of misplaced thyroid tumors would be useless, inasmuch as nothing of importance could be added to the most thorough and exhaustive work of Wölfler referred to above.

The author would, however, call the attention of those interested in

[1] Wiener medicinische Wochenschrift, 1879, No. 8; Ueber die Entwickelung und den Bau der Schilddrüse, etc., 1880; Archiv für klinische Chirurgie, 1890, Band xl.; Arthur Rivière: "La Glande thyroïdes et les Goitres," Paris, 1893; E. G. Ssalistschew: Archiv für klinische Chirurgie, 1894, Band xlviii. p. 452.

the question to Von Eiselberg's remarkable case.[1] Briefly stated, the main points of interest in it are the following: After extirpation of a goitrous thyroid in 1886 myxœdema appeared. In her second pregnancy thereafter a hard nodule formed in the sternal region. With the growth of this tumor (which, by the way, was noted to be larger during than between the menstrual periods) the symptoms and signs of myxœdema lessened. In 1892 severe lancinating pains in the sternal growth induced her to again apply for treatment. At this time there was no evidence of myxœdema or of tetany. In September, 1892, the tumor-mass with the surrounding bone was removed by the chisel, and showed the structure of cylindrical-celled carcinoma. Nine days after the removal of the growth tetany appeared in both arms and legs, and continued, although to a lessening degree, until the end of November of the same year. In December a sudden relighting of the tetany took place and lasted for ten days. In the summer of 1893 she again became pregnant, and toward the end of pregnancy suffered from frequent tetanic cramps. In the spring of 1894, after delivery, some of the symptoms of myxœdema reappeared. A small, orange-sized tumor of the left scapula and one in the extensor muscles of the thigh were present at the time when the report closed. Von Eiselberg suggests two possible explanations. Either it was a case of carcinoma occurring in an accessory thyroid, or it was a metastasis of carcinoma to the sternum (or possibly an adenoma later becoming carcinomatous), which had taken on compensatory action for the removed thyroid. He inclines to the latter view on account of the origin of the growth apparently within the tissues of the sternum.

Case II. *Round-celled sarcoma of anterior mediastinum; secondary involvement of the pericardium, heart, lungs, and pleura; exploratory puncture, with breaking of needle; death; autopsy.*—John G., white, aged 32 years, was admitted to the Philadelphia Hospital on November 24, 1894. He was a native of Ireland, but had been in America for twenty years. He had worked in a morocco factory.

He was always a strong and healthy man, his only illness being that for which he was admitted to hospital. He gave a history of a former attack of gonorrhœa, but denied other venereal disease. He had been a hard drinker, going on "sprees" of two weeks' duration. No history of traumatism.

The first signs of illness occurred six weeks before he came to the hospital. At that time he was "tramping" and in his usual condi-

[1] Archiv für klinische Chirurgie, 1894, 489.

tion of good health, when he was suddenly seized by a sharp attack of pain of a tearing character on both sides of the chest, and extending out to the shoulder on either side. The pain was very severe, and after it had subsided he still felt indefinitely ill. Four or five of these attacks occurred before he applied for admission, lasting sometimes for a day, sometimes for a shorter time. Although feeling sick between the attacks, he was still able to be about.

Upon admission he was found to be well-nourished and of powerful build. The whole body was much discolored by cyanosis. Respiration was labored, 46 to 50 per minute, and there was complete orthopnœa, except when he became exhausted and laid for a time upon the right side. The pulse was rapid and jerky. Short, spasmodic, unproductive cough, such as is so characteristic of pleural effusion, was almost constantly present. The voice was smothered but was otherwise unaltere l, the character mentioned being evidently due to the intense dyspnœa. The pupils were equal and natural. Tongue clean and protruded in the median line. The chest was well-formed, the left side, posteriorly, being apparently a little less in size than the right. Respiration chiefly abdominal, but little lateral expansion occurring, and the chest being somewhat elevated as a whole upon inspiration. The abdominal wall moved, in respiration, much less upon the left than upon the right side, so that there was a peculiar twisting of the abdomen toward the right on inspiration. The abdomen was somehwat distended and tympanitic.

The apex-beat was imperceptible to sight or touch. No area of pulsation was present at any part of the chest. The heart-sounds were most plainly audible at the normal position of the apex-beat. They were distant and feeble, but were neither accompanied nor replaced by murmur. As will be seen below, the area of cardiac dulness could not be separated from other non-resonant areas.

On the right side anteriorly the note from the clavicle to the upper border of the third rib was directly poor, being high-pitched and dull. At the upper border of the fourth rib there began an area of dulness that joined the hepatic dulness below and the cardiac dulness to the left, extending toward the right as far as the anterior axillary line. There was flatness over the whole body of the sternum, and over the whole left anterior surface of the chest. In the left axillary region there was profound dulness save at the inferior portion where gastric tympany was obtained.

Posteriorly there was flatness from base up to the angle of the scapula upon the right side, from base to level of fifth rib upon the left side. Change of posture showed shifting of the upper line of dulness upon the left but not upon the right side.

Anteriorly the breath-sounds upon the right side were feeble but of normal character from clavicle to upper border of third rib, normal from that point to the fourth rib, absent below that level. On the left side anteriorly there was complete absence of breath-sounds at all points. Posteriorly upon the right side the breath-sounds were distant and feeble below, normal above the angle of the scapula. On the left side there was silence with complete absence of tactile fremitus and vocal resonance up to the fifth rib, and in the left axillary region.

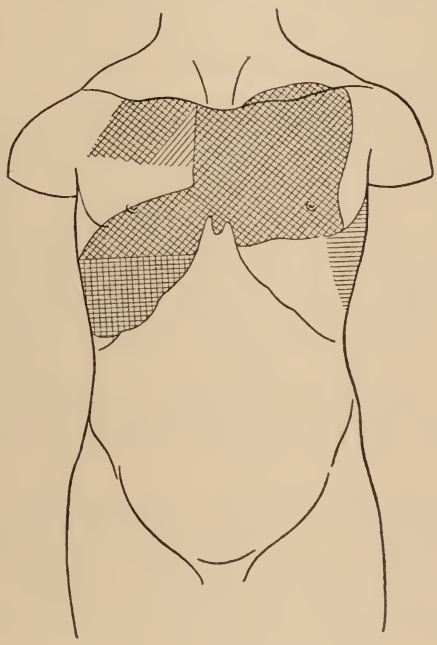

There was, therefore, evidently a considerable accumulation of fluid in the left pleural cavity in spite of the right decubitus, and upon the day after admission an aspirator-needle was inserted in the sixth interspace posteriorly, and twenty-five ounces of blood-stained, slightly turbid fluid were withdrawn. The patient was much relieved at once, and there was slight diminution of cyanosis. Immediately after the aspiration the respirations fell from 36 to 28 per minute, the percussion-note over the left lung posteriorly and in the left axillary regions became resonant, and vesicular murmur could be heard over the left chest except at the extreme base. Anteriorly the physical signs remained unchanged.

On November 26th he seemed better in the morning, but toward noon

became much cyanosed, and respiration became much embarrassed. The decubitus was persistently upon the right side save when the position of orthopnœa was assumued during the attacks of more marked dyspnœa. The apparent area of cardiac dulness extended from a half-inch to the right of the sternal border to an inch to the outer side of the left mid-clavicular line, and at the third rib could be differentiated from the area of less intense dulness that extended downward from the left clavicle. The heart-sounds seemed distant, and by no means indicated as good cardiac action as did the pulse, the latter at this time being of quite good force and volume. The breath-sounds could be plainly heard, and were of fairly natural character over the left lung posteriorly, but were absent in the left axillary region.

On the 27th friction-sounds were present in both axillary regions, and there were fine crepitations at the base of the right lung. Upon the left side friction-sounds were very distinct and close to the ear down to the eighth rib, below which point there was silence. Gastric tympany was elicited by the lightest percussion below the eighth rib in the left anterior axillary line. Posteriorly on the left side resonance was impaired, without flatness, and the breath-sounds were feeble and distant.

On November 28th distant tubular breathing was heard at a point three inches to the left and a little below the point of puncture. Posteriorly upon the right side there were fine crepitations, especially loud at the base. Otherwise the conditions present at the last examination still prevailed.

On the 29th there was considerable extension of the area of tubular breathing in all directions. This appearance of tubular breathing was unaccompanied by rise of temperature. Since his admission the patient's general condition had remained practically unchanged. The temperature was normal, the breathing rapid, the pulse of variable but usually good force. The dyspnœa remained persistently, and there was very marked capillary stasis from the costal margins upward on both sides. The patient usually lay curled up on the right side, but would at times sit up with the head bowed forward and resting on the knees, while the hands were extended forward to clutch the bed-clothes. It was about this time that there were noticed numerous dilated venous radicles running upward for about an inch from the costal border on each side of the chest; and also at this date the patient first complained of loss of power, numbness, and tingling in the right arm and hand, evidently the result of pressure exerted in the right lateral decubitus.

On December 3d there was marked dyspnœa and the physical condition of the patient was not so good as before. Owing to the persistence

of dulness and absence of breath-sounds below the left clavicle an exploratory puncture was made in the left mid-clavicular line in the second interspace, and about an ounce of dark blood was withdrawn with almost no suction being exerted on the piston of the syringe. Further withdrawal was deemed inexpedient on account of the certainty of absence of pleural exudate in that region. Owing to the strong suspicion of the presence of fluid still remaining in the left pleural cavity at a lower portion the needle was inserted in the sixth interspace just behind the posterior axillary line. Some difficulty was experienced in puncturing the interspace owing to the close approximation of the ribs. When the needle was fully inserted the patient made a sudden movement, the needle was snapped in two by the approximation of the adjoining ribs, and the distal portion remained hidden by the skin. I at once froze the skin and made an incision down to the intercostal muscles. Careful exploration with finger and probe failed to reveal the whereabouts of the missing portion of needle.

There was some pain of brief duration immediately after the accident, and again during the latter portion of the same afternoon, but it was quickly relieved by a single hypodermic injection of an eighth of a grain of morphine.

Upon the following day the patient seemed none the worse for the accident; in fact, he said that he felt better.

On December 5th a tumefaction appeared at the lower portion of the neck on the left side. By December 7th this could be distinctly outlined as a well-defined tumor beneath the left sterno-cleido-mastoid.

Until the time of his death, December 9th, the conditions remained nearly the same, save for extension of bronchial breathing over the whole of the left side of the chest posteriorly, increasing weakness, and cyanosis of the chest and face, increasing paresis of the right arm and rather rapid growth of the mass in the left side of the neck.

The *autopsy*, at which I unfortunately could not be present, was made by Dr. Bevan, assistant pathologist to the hospital. I quote his notes upon the examination:

Body well nourished; rigor mortis marked; peritoneal cavity contains a pint of clear serous fluid; pleural cavities contain fluid—the right thirty-six ounces, the left forty-five ounces. The fluid was thin and blood-stained.

Pericardium contains blood-stained fluid. A number of small nodules found on parietal layer. The right side of the heart was flaccid, the left contracted. The ear was covered with small nodules varying in size

from that of a pin-head to that of a pea, very firm and light-gray in color on section.

Left lung not adherent. There were a number of small nodules on inner surface penetrating into the lung tissue. Right lung similar to left.

In mediastinal space a large, dense, white mass, extending from diaphragm to clavicles, and from the sternum to which it was attached to the vertebræ, embracing at the upper part, the heart, great vessels, and trachea. The posterior surface was concaved and arched across the vertebræ and œsophagus. The thoracic contents (tumor, heart, lungs, etc.) weighed 3150 grammes.

Spleen large, soft, deep red in color; weight 175 grammes.

Kidneys large, round in shape, deeply congested. Relation of cortex to pyramids undisturbed.

Liver firm, reddish-brown in color; weight 1775 grammes.

I obtained a portion of the growth and found it to be a small round-celled sarcoma. No trace of the needle could be found at autopsy, nor could the place of puncture be discovered.

The clinical features of the case that are of interest, aside from the physical signs, are the absence of any tangible cause, the apparently sudden onset of symptoms, the difficulty of positively excluding the possible presence of pericardial effusion, the right-sided decubitus in spite of the left-sided effusion, the absence of dysphagia, change of voice and pupillary signs, the pressure palsy of the right arm, and the slight inconvenience produced by the presence of the fragment of needle within the chest. The clinical diagnosis was tumor of the lung, probably secondary, with pericardial involvement, the only reservation being absence of involvement of pulmonary structure. This freedom of involvement of lung tissue proper was suggested by the complete absence of blood in the sputa.

The sudden onset of symptoms did not cause us to exclude neoplasm, as such an onset is not entirely unknown, the chief difficulty being to explain the man's ability to be about with such serious mischief going on within his thorax. The presence of pericardial effusion was several times considered, but was excluded by the good condition of the pulse, the position of the point where the sounds were best heard (at the normal position of the apex-beat), and the fact that the symptoms were throughout pulmonary rather than cardiac. Although at autopsy there was found to be fluid in right pleural cavity, during life the signs of extra-pulmonary pressure were all upon the left side. The absence of pressure-signs is explained by the situation of the growth. That the paresis of the right arm was due to pressure by the weight of the body is certain.

There was at no time evidence of cerebral involvement, and the paresis was accompanied by numbness and tingling of about equally rapidly increasing severity. The portion of the needle that remained within the thorax was about two and one-half centimetres long, and little heavier than the ordinary hypodermic needle. That it was in the pleural cavity is shown by the fact that the needle was broken by the approximation of the adjoining ribs, as was perfectly evident to the hand holding the syringe.

From the pathological standpoint it is interesting to note the complete absence of metastasis to parts without the thorax, the only extrathoracic growth being the mass in the neck noted during life.

Case III. *Primary endothelioma of the left pleura; secondary involvement of lung, pericardium, and diaphragm.*—Jane M., white, aged 50 years, was brought to the Episcopal Hospital in July, 1894. She was wildly delirious on admission, and no history was obtainable from her. A friend of the patient said that she had been ailing since early in the preceding spring; but she could give no more definite facts in regard to her illness. On examination there was found to be absolute flatness from base to apex, anteriorly and posteriorly upon the left side of the thorax, with great increase of resistance. There was, however, no marked respiratory distress. Preparations were made for tapping on the next day, or sooner if necessary, but the patient died before aspiration was attempted. She was extremely weak on admission, and steadily wore herself out in her delirium in spite of active stimulation. At autopsy the following notes were dictated:

Body that of a well-nourished woman. Rigor mortis well marked. A superficial scar over the right patella. There is a large amount of subcutaneous fat of normal appearance. Costal cartilages not ossified.

Organs of abdomen in normal position. Vermiform process points upward and runs directy behind the cæcum. Pericardium contains the normal quantity of fluid. The visceral pericardium is normal. Parietal pericardium normal save for the presence upon the surface, at the left, of whitish plaques of cartilaginous hardness, firmly binding pericardium to left pleura.

Both auricles filled with currant-jelly clots; chicken-fat clots protrude from the cut ends of the pulmonary artery and from the pulmonary veins tough ash-colored clots. The heart is considerably larger than the patient's fist. Considerable amount of subpericardial fat. Foramen ovale closed. Tricuspid orifice admits three fingers. Right ventricle contains tough, adherent, ash-colored clots. Wall of right ventricle measures 7 mm. in thickness; the muscle of good color. Endocardium

and valves of right heart normal in appearance. Left auricle normal. Mitral orifice admits two fingers. Left ventricular wall measures 15 mm. in thickness; the muscle dark. Endocardium of left ventricle opaque and gray. Mitral valve leaflets thickened at edges; aortic leaflets thickened at bases. Very early atheromatous change at root of aorta. Weight of heart freed from clots ten and a half ounces.

The right pleural layers are united by a few old string-like adhesions. The left pleura was inseparable and was removed with the lung.

Right lung slightly emphysematous; everywhere crepitant; slightly œdematous; weight eleven and a half ounces. Left lung had to be removed with its pleura by cutting it away from the thoracic wall through tissue of cartilaginous hardness. The left lung was so firmly united to the diaphragm that the latter had also to be removed with the mass. In removing the lung the finger broke into the cavity in the lower portion of the thickened pleura(?). This cavity emptied itself before removal could be accomplished, and the nature of its contents could not be ascertained. The lateral and posterior surfaces of the mass removed from the left side of the chest shows distinct markings of ribs and intercostal spaces; the median surface shows enlarged bronchial glands; the lower surface shows the adherent diaphragm with infiltration thereof, and the presence on its inferior or abdominal surface of cartilaginous areas of infiltration. Section of the mass shows in the centre compressed lung tissues of chocolate-brown color occupying an area measuring six centimetres by eleven and a half centrimetres, surrounded entirely by white dense tissue measuring at different parts from five millimetres to two centimetres in thickness. In the cut surface are numerous sections of bronchi from which pus exudes on pressure. In the centre of the mass of lung tissue is a group of pale, solid points (carcinoma or catarrhal pneumonia(?). At the upper part of the mass the lung can be separated from the encasing dense white tissue by use of but little force.

Glands in the posterior mediastinum not enlarged.

Pancreas, adrenals, spleen, œsophagus, trachea, and larynx perfectly normal.

Kidneys similar. Both ureters and all vessels normal. Both organs large; cortex diminished; cut surface pale; vessels of cortex too distinct. Capsules stripped off readily.

Stomach normal save for some intense submucous ecchymoses in region of cardia. Duodenum and other parts of intestinal tract normal.

The fundus uteri is large and retroflexed. Appendages on right side low down in pelvis, on left side displaced slightly downward. Par-

ovarian cyst of small size on right side. Cervix large, mucous membrane congested ; unilateral laceration.

Liver weighs three pounds seven and a half ounces ; surface normal. On section the cut surface is slightly marbled and pale with reddish mottling. Evident fatty change present.

Sections of the mass in the left side of the thorax, of the nodules in the left lung, in the pericardium and diaphragm were kindly made for me by Dr. David Riesman. Sections of the cervix uteri were also made. No signs of any malignant formation was found in the latter. In sections from all of the other parts mentioned there was found to be a stroma of connective tissue containing in its meshes epithelioid cells. In the sections from the white mass encapsulating the left lung there was much dense connective tissue containing a rather small relative number of nests of epithelioid cells. These cells are of quite irregular shape and size, the prevailing type being large, with a well-stained nucleus situated near the centre and with a proportionately large protoplasmic mass surrounding the nucleus.

The growth was manifestly primarily located in the left pleura. This is shown not only by the greater size of the growth in that membrane, but also from the method of its involving neighboring tissues (lung, diaphragm, and pericardium) on all sides in about equal degree. That it was a primary growth of the lung secondarily involving the pleura can hardly be thought of in view of the distribution of the pulmonary growths, their small size, and the distinct absence of extensive involvement of the organ. Careful search was made for any other seat of primary malignant growth, but without success. The tumor was evidently, therefore, a primary tumor of the pleura.

The microscopic appearance is that typical of carcinoma. The absence of any epithelial structure in either normal or pathological pleural tissue, save in case of secondary growth of malignant epithelial tumors, and the character of the cells present in the sections, class this tumor among the endotheliomata.

Whether this variety of growth should be designated carcinoma or sarcoma is still an open question. It seems to the writer that the endothelioma present in this case shows no essential difference in its manner of growth and its arrangement of cells from epitheliomata save for the rather different type of the cells forming the nests. It would seem, therefore, that the classification of the endotheliomata with the sarcomata depends entirely upon embryological grounds, and apparently embryologists are not agreed among themselves in regard to the precise origin of the endothelium from the layers of the blastoderm.

*December* 27, 1894.

### 4. *Mediastinal sarcoma.*

Exhibited by Dr. Fussell.

The patient from whom this specimen was removed was a boy, aged 13 years. His father died of phthisis; his mother is living and well, as are five brothers and sisters. He was brought to me by Dr. J. V. Kelley, of Manayunk, October 1, 1894. He had never been ill until three or four months before Dr. Kelley saw him, when he began to have difficulty in breathing.

*October* 7. The child was the subject of a constant distressing dyspnœa, which was much increased by the least exertion. He had a harassing cough, which was metallic in character and suggestive of pressure upon the trachea or larger bronchi. His face was swollen, eyes protuberant, and neck swollen. On examination the chest was hyper-resonant throughout, the antero-posterior diameter being decidedly increased. The expiration was increased, and the breathing characteristic of emphysema. There was dulness under the sternum, reaching from the junction of the first and second process to the lower border of the third rib, and one inch on each side of the sternum. There was no thrill, pulsation, nor murmur over this dulness. The heart was not enlarged pulses; equal; pupils equal. Examination of the throat showed congestion of the larynx, but no paralysis of the cords. The urine was normal. There was a slight rise of temperature. In view of the physical signs a diagnosis of mediastinal tumor was made, probably due to tubercular glands.

He was seen two weeks after the first visit, and the dulness extended from just below the supra-sternal notch to the middle of the second piece of sternum and one inch on either side of the sternum. The following week the dulness extended from the supra-sternal notch to the level of the sixth rib, and one and a half inches on either side. On account of the rapid growth, the tumor was now supposed to be malignant in character. Just at this time the child was seized with a terrific attack of spasmodic asthma, in which he nearly died. There had been up to his time no marked loss of flesh. He went from under my care then, and I did not see him again until February 1, 1894. He was moribund; there was great emaciation; the mass under the sternum extended from the supra-sternal notch to the liver-dulness below. The liver was greatly enlarged, extending almost to the crest of the ilium.

There had been constantly increasing dyspnœa which prevented sleep for many days before death. He died in a few hours. On examination of the body the limbs were greatly wasted, the chest appeared large in comparison with the remainder of the body, measuring 26 inches at the nipple-line and 25 inches at the margin of the ribs. The belly was protuberant. The incision through the skin caused blood to flow freely from the superficial veins. On opening the belly there was found great thickening of the peritoneum. The liver extended from the margin of the ribs; it was pushed down by the mediastinal growth to within three inches of the symphysis pubis. The main enlargement of this organ was in the right lobe, and myriads of centres of new growths were scattered throughout the liver. There was no ossification of cartilages of the ribs. On removing the sternum with its cartilages a mass was discovered, reaching from the left costal junction with the cartilages to the right nipple-line, and from the xiphoid cartilage to the supra-sternal notch, and backward to the spinal column. The left lung has a few pleuritic adhesions; the right is adherent over its whole surface. The pericardium is full of liquid. The heart is small. The mass compresses the right lung and is adherent to its mediastinal surface. Other masses are found in both lungs. The trachea is embraced by the growth, and the œsophagus flattened. There were no enlarged axillary or cervical glands. The mesenteric glands were not enlarged. The growth was soft, and, on section, a milky fluid exuded.

The sections were kindly made by Dr. Alfred Stengel, our recorder. Notwithstanding the apparent pressure on the œsophagus there was never any difficulty in swallowing. The recurrent laryngeals were certainly involved in the growth, but their function was apparently unimpaired during life.

According to Hare, *Mediastinal Diseases*, sarcoma occupies the third place in frequency of mediastinal growths, and the age at which the growth occurred is below the average, by far the greater majority occurring in adults.

Dr. Griffith considered it an interesting matter how often hemorrhagic fluid means a malignant growth. He referred to a case of removal of a growth in the breast seven years ago. Four years later pain in the side and cough developed, and later intense dyspnœa. She was tapped repeatedly, and finally pure blood was obtained. The next year she was quite well, but now—still a year later—she is again running down. Probably it is a case of hidden tuberculosis or malignant disease.

Dr. Jurist said Dr. Hare had recently expressed it as his opinion that most of these cases are sarcoma.

Dr. Cohen agreed with Dr. Griffith in regarding malignant pleural growth as very likely in his case.

Dr. Hughes leaned toward tuberculous pleurisy. The initial serous fluid, he considered, was against cancer, whereas in tuberculosis the fluid often becomes bloody late in the case. The subsidence of the trouble and return to health in that case also spoke for tuberculosis as against cancer.

The President remarked that one should not always expect metastasis from cancer of the breast when mediastinal symptoms are present. He recalled a case in which the breast had been removed and later paroxysmal cough, dyspnœa, and emaciation developed. She was then tapped and clear fluid obtained. The mediastinal glands in this case were not much enlarged.

*March* 22, 1894.

---

### 5. *A fibrous tumor of the receptaculum chyli.*

Exhibited by Dr. Joseph McFarland.

The thoracic duct occupies so sheltered a position between the aorta and the spinal column that either its diseased conditions are few or they escape detection. A few lesions are recorded in literature, thus Eichhorst mentions a case of traumatism by which the thoracic duct was lacerated, and caused the development of chylothorax, from which, however, the patient recovered. Several similar cases are very briefly mentioned.

A case of primary tuberculosis of the thoracic duct is reported by Ponfick, in which there was widespread destruction of tissue, the distribution of tubercle bacilli to the whole body, and the establishment of an acute general miliary tuberculosis. A second somewhat similar case is also reported by Shilling.

The secondary tubercular lesions are more common, and it seems not unusual to find in the cases of intestinal and mesenteric tuberculosis that the thoracic duct contains a few miliary tubercles.

Weigert seems to be the first modern pathologist to have discovered a carcinomatous disease of the organ, though in the days when carcinoma and tubercle were not clearly differentiated Sir Astley Cooper in 1798 described a receptaculum chyli which had been invaded by the growth of cancer from a primarily diseased testicle.

Virchow, Enzmann, Andral, and Seydhecker have also described cases

in which the thoracic duct was invaded by secondary carcinomatous disease.

I have been unable to find mention in the literature of a single case of benign tumor of the duct, and report the following case as interesting because of its unique character.

The patient was a woman who had long been under treatment in the wards of the Hospital of the Protestant Episcopal Church in Philadelphia, where the autopsy was made, and through the kindness of one of the visiting physicians, Dr. D. J. M. Miller, I am able to report the case.

*Autopsy notes.* X. Y. Z., female, aged 40 years. Much emaciated. Autopsy forty-eight hours after death. The surface of the body covered by a large number of small tumors—molluscum fibrosum. The largest of these, nearly as large as a small orange, situated upon the sacrum was ulcerated, and with the surrounding tissue was beginning the formation of a decubitus.

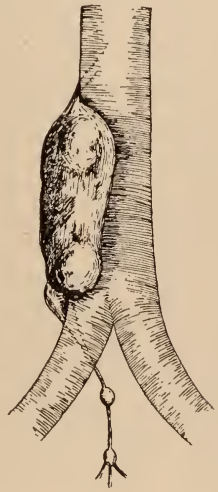

*Thorax.* Pericardium normal, containing a normal amount of clear fluid. Heart normal, valves competent, chicken-fat in left ventricle. Lungs normal, thoroughly crepitant throughout. The lungs were unusually clean, and of a beautiful pink color. The absence of deposits of dust probably is explained by the fact that the patient had been bedridden for many years. The remains of an old pleurisy was shown by the attachment of both apices to the parietes by old adhesions. No tubercles could be found in the apical tissue.

*Abdomen.* With the exceptions noted, the abdominal organs showed no changes from the normal. In the neighborhood of the sigmoid flexure some old peritoneal adhesions were discovered. The right adrenal was apparently about one and a half times the normal size. No pathological change was apparent, the increase in size apparently being a hypertrophy. Microscopic examination at a subsequent period proved the organ normal.

The stomach was normal except that from the lesser curvature near the pylorus a small tumor was observed projecting into the organ. The tumor was about the size of a small bean. Section showed it to be submucous, and to consist of lobulations made up of racemose glandular structure. Here and there descending processes were beginning to invade the muscular coats. Microscopically this little tumor was seemingly benign, and must be described as adenomatous. The beginning invasion of the muscular tissue, however, testified to its malignancy, and it seems that it was about to become an adeno-carcinoma. An interesting question excited by the structure of this little growth is whether carcinoma of the stomach always begins as a single glandular hyperplasia, or whether it begins at once the atypical growth of carcinoma.

After the removal of the intestines and the examination of the sympathetic ganglia, etc., it was discovered that the receptaculum chyli, or expanded commencement of the thoracic duct, was occupied by a tumor which projected from the right side of the upper lumbar vertebræ, between them and the aorta.

The tumor was moderately firm in consistence, smooth on the surface, without adhesions, and from its upper end the thoracic duct could be traced upward to the diaphragm. The tumor was between 6 and 7 cm. in length and about 2 cm. in diameter, slightly lobulated, and solid throughout, no continuation of the thoracic duct into its interior being discovered. The lower part terminated in a pointed extremity continuous with the pelvic lymphatics The cut surface was fibrous, somewhat suggesting the appearance of a uterine fibroid, but made up of finer fibres.

*Brain.* When the calvarium was removed and the membranes opened, a large quantity of a slightly sanguinolent fluid escaped. The membranes were congested. The ventricles were considerably dilated, so that the hand of a man could easily have been made to enter the ventricular system, had its shape allowed. The ependyma was also much injected. The amount of cerebro-spinal fluid must have exceeded 200 c.cm.

The further description of the brain and cord will be written at a subsequent period in conjunction with the interesting clinical conditions by Dr. Miller.

Aside from the hydrocephalus which caused the patient's death, the only features of interest brought to light by the autopsy were the gastric and receptacular tumors. The coincidence of these tumors with molluscum fibrosum upon the surface of the body would not be remarkable if of the same nature. In numerous cases of molluscum, numerous internal tumors have been observed. The gastric tumor, however, did not have any possible connection with the others. Whether or not the receptacular tumor was part of the molluscum or not is a matter of some doubt. Its microscopic examination showed it to be a soft fibroma with a few muscle-cells mixed among the fibres. It is poorly supplied with bloodvessels, but shows no areas of degeneration. A rather unusual number of round cells are distributed throughout the tissue.

As has been said, no central lumen can be made out, and whether the tumor has grown in an annular form or from one side of the tube is a question. It is interesting to note that the patient had no symptoms suggestive of any tumor obstructing the flow of the lymph. In all the cases in which the thoracic duct has been obstructed by the presence of aneurisms or tumors upon it, œdema of the extremities or the escape of chyle into the abdomen has been noted. It is possible that in this case there was no obstruction to the tube, but if it was patulous its course was undiscoverable. One case of tumor of the duct itself is reported by Weigert, in which complete occlusion was also noted, yet without any symptoms, even the lacteals being undistended.

Experiments have, furthermore, shown that ligation of the thoracic duct is followed by no regular sequelæ, but that occasional œdema results; occasionally nothing abnormal results.

The case under consideration adds further confirmation to the experiments quoted by showing that a good-sized tumor can occur, can apparently occlude the organ, yet produce no symptoms, and further shows pretty conclusively that the lymphatic channels of the lower extremities must have very numerous anastomoses with the lymphatic channels higher up. *May* 10, 1894.

---

### 6. *Fibroma of skin from back of neck.*

Exhibited by Dr. J. M. Swan.

O. T., a negro, and a cook by occupation, was admitted to the Presbyterian Hospital May 24, 1894. On the back of his neck was a good-sized nodular tumor. This tumor was hard, somewhat pedunculated, and

presented two surfaces of ulceration on the skin over it. The growth was of twelve years' duration and measured three by three and a half inches. There was no history of a scar having existed at this point previously, and no history of traumatism. After the removal of the tumor it was noticed that the growth had a layer of adipose tissue beneath it. Microscopically it is a pure fibroma, very hard, the cells being very few and the dura fibres interlacing in every direction. This growth answers nearly to the description of the true keloid, except that it is more pedunculated than keloid and it did not cause contraction of the fasciæ. Fibroma of the skin is a better name, since it is based on the structure of the growth. In the last edition of Delafield and Prudden's *Pathology* the word keloid is not used. *June* 28, 1894.

## IX. MISCELLANEOUS.

### 1. *Pustules from a case of variola.*

Exhibited by Dr. H. W. Cattell.

The specimen was removed from the extensor surface of the right wrist of a colored male, aged 21 years. In order to test the effects of different reagents in the hardening of the tissue, the following solutions were chosen: 2½ per cent. bichromate solution, 70 per cent. alcohol, 95 per cent. alcohol, Fowler's solution, and a saturated solution of the bichloride of mercury. The specimen giving the most natural appearance of the pustules was the one hardened in 95 per cent. alcohol and shown to the Society. The following conditions were also observed at the post-mortem: First, a peculiar aromatic offensive odor emanated from the body; second, the blood was fluid, resembling that seen in hydrocyanic-acid poisoning, though with a tinge of brown. Some chicken-fat clots were found in the heart; third, the muscles seemed in a healthy condition, and there was much rigor mortis, the post-mortem being made five hours after death; fourth, the liver seemed normal, though larger in size; fifth, areas of catarrhal pneumonia in both lungs, not so marked in the left as in the right; sixth, the solitary glands of the small intestine were enlarged and congested, and some were hemorrhagic. There were also numerous hemorrhagic spots in the large intestine. The bile was of dark, claret-brown color, and as thick as a currant-jelly clot; eighth, an acetone odor occurred on section of the kidney; ninth, the membranes of the brain were congested and the brain-substance soft.

*September* 14, 1893.

---

### 2. *Physicians' and surgeons' bacteriological case.*

Exhibited by Dr. D. Braden Kyle.

The case is adapted to the ready collection of material. It contains six small vials containing gelatin or agar-agar with an ose passing through the sterilized cotton plug. These were fitted in the case.

*October* 12, 1893.

### 3. *Miliary tuberculosis.*

Exhibited by Dr. Scott.

The specimens were from the body of a man greatly emaciated. The apices of both lungs were retracted. The left lung overlapped the middle line, and on the right side from the third rib to the base was a large empyæmic cavity containing about 65 c.c. of pus, in which there were fibrinous lumps. The right lung was small and dense. Near the posterior surface of the middle lobe was an atelectatic area. The costal pleura was thick and rough; the pulmonary pleura vigorous and tough. This lung had three cavities in the apex—one quite large. Near these cavities there was angry inflammatory tissue. The middle lobe was caseous, and the lower lobe also somewhat solid. The right lung weighed 1300 grammes. There was no spot of perforation. The left lung showed extensive miliary tuberculosis, all the tubercles being gray and nowhere caseous except near the apex. The bronchial glands contained tubercles. The heart was markedly fatty, in diastole, and full of blood. The liver was large and contained tubercles. The spleen was considerably increased in size and showed tubercles, as did the kidneys. The intestines showed tubercular ulcers with tubercles on the serous side. Ascites was present. The brain was normal.

The President said the patient had presented at first the clinical appearance of acute lobar pneumonia, but it was soon found to be tubercular, probably having its origin in a tubercular pleurisy.

*November* 9, 1893.

---

### 4. *Spleen from a case of miliary tuberculosis.*

Exhibited by Dr. Daland.

A. J., colored, aged 48 years, native of Philadelphia, married; admitted December 23, 1893. His family history is negative. He had no brothers or sisters. His parents died in advanced life—cause unknown.

*Personal history.* Patient asserted that he never was ill before the present trouble. No venereal history could be obtained. He drank to

excess at irregular intervals of from four to six weeks, but confined himself to beer. He did not drink between these debauches.

*Present illness.* He stated that four weeks previous to admission he began to feel "out of sorts" to cough a little, and to be feverish. He felt no pain, and had no localizing signs or symptoms. He received no medical care before admission, and thinks that his temperature was about the same as when first taken at the hospital. He had then a slight cough without expectoration; temperature 102° F.; respirations 31; pulse 104.

Physical examination showed no signs of disease in thorax or abdomen. For four days after admission his temperature ranged from 102° to 103.4°. No pain, slight cough, slight expectoration. His appetite was good; bowels constipated, but freely moved by laxatives. His bowels had been moderately constipated for four months previous to admission.

On the fourth day his temperature fell to 100.6° in the forenoon, and rose to 105° at four o'clock in the afternoon. There was no chill. Then it varied from 105° to 102.6° for the next three days; then it dropped to 98° in the early morning, followed by a marked general chill, and rose to 104.4° at eight o'clock the same morning. The next day the temperature fell to 98° in the morning and rose to 104.2° by noon. He had no chill. From this time until his death, on the seventeenth day, his temperature varied from 100.8° to 104°. The daily variation ranged from one degree to three degrees, and one day there was no variation. His pulse ranged from 96 to 104 until three days before his death. Respirations 23 to 30.

His blood was examined for hæmatozoa January 1st and 4th, with negative results. Sputum examined January 5th and 10th—two specimens each time—and no bacilli were found.

The patient's cough decreased until the fourth day before his death. Expectoration was mucoid and frothy.

A systematic examination of his chest each day revealed no change from the normal until ten days before his death (January 4, 1893), when the right apical region showed impaired resonance, slightly harsh on vesicular breathing, and a little increased vocal resonance (these signs were doubtful). This condition continued until three days before his death. Cough increased, expectoration more copious, purulent, and contained specks of blood. Sputum at this time showed a few lanceolate diplococci.

Two days before his death (January 12, 1893) chest examination showed probable consolidations in areas at root of lungs in the inter-

scapular region posteriorly, more marked on the right side (these signs were doubtful at the best). His respirations ranged from 30 to 40; pulse 100 to 120. Forty-eight hours before his death he had six ounces of intestinal hemorrhage—clear arterial blood. No abdominal symptoms either preceded or followed this hemorrhage.

Patient in carphologia picked his nose, and this was the point of infection of erysipelas, which developed thirty-six hours before his death. Patient complained of pain at upper thyroid cartilage, but repeated examinations showed no changes in tonsils, pharynx, or externally.

The erysipelas did not modify the course of the original disease. The only localized pain was referred to the lower margin of the liver. This lasted for ten days, but the liver was not enlarged. Bronchial râles could be heard mostly on the right side, and these disappeared before death.

Patient died January 14 at 8.30 P.M., apparently from exhaustion.

*Post-mortem.* Miliary tuberculosis of the lungs and spleen was found. The spleen, which was exhibited, showed tubercles remarkable for their size.

Dr. Cohen said the spleen resembled a case of sarcoma he had had.

Dr. Jamison recalled specimens that he had seen five years ago of tuberculosis of the liver and spleen. In the liver there were large nodules which were bile-stained in the centre. In the spleen the nodules were quite as large and grayish-yellow. There were, in fact, few nodules that were not large. *February* 8, 1894.

---

## 5. *The pathologic changes caused by certain so-called toxalbumins—an experimental study.*

Read by Dr. SIMON FLEXNER, of Baltimore.

The crystalline principles called ptomaïnes which have been isolated by Selmi, Nencki, Brieger,[1] and others from cultures of bacteria do not, as was once supposed, represent the essentially active agents produced by pathogenic bacteria. Since the isolation by Roux and Yersin,[2] in 1888, from cultures of the diphtheriæ, of an amorphous toxic albuminous substance which, as they showed, was capable of causing all of the symp-

[1] Berliner klin. Wochenschrift, 1889, No. 39.
[2] Annales de l'Inst. Pasteur, 1888, No. 12, p. 629.

toms of diphtheria, excepting the pseudo-membrane, other albuminous substances have been obtained from a number of pathogenic bacteria.

The researches of Kobert and Stillmark,[1] Martin,[2] and Hellin[3] have led to the isolation from the castor-bean and the jequirity-bean of two amorphous substances—ricin and abrin respectively—which in many respects resemble the toxic albuminous principles obtained from bacteria.

We owe to the investigations of Weir Mitchell and Reichert[4] the knowledge that the toxicity of snake-venom depends upon certain albuminous constituents, and later Mosso and Springfield[5] separated from the blood of eels an exquisitely poisonous albuminous substance. Moreover, the well-known effects which the blood-serum of one species of animal exerts upon another species has led to the conclusion[6] that the blood of different animals contains distinctly toxic substances.

As to the precise nature of many of these substances, to which the name of toxalbumins has been provisionally given, there is little agreement. They are regarded by some investigators as being enzymes, while a few deny altogether their albuminous nature.

It has been suggested by Roux and Yersin that the diphtheria toxalbumin is an enzyme, and Stillmark holds the same view concerning ricin, while Nencki[7] considers that the proteids of the blood-serum, to which it is believed by many that animals owe their immunity from disease, belong to the same category.

The recent statements of Brieger and Cohn,[8] based upon the study of the properties of a highly refined tetanus-toxin, that this body, which fails to react with Millon's reagent, and responds to the xantho-proteic test, is not an albumin, is not regarded as sufficient to disprove its proteid nature.[9]

Brieger and Fränkel[10] oppose the view of the enzyme-nature of these bodies; and Fermi,[11] who also objects to this view, considers as militating against it the fact that of 114 described pathogenic micro-organisms

[1] Kobert, Lehrbuch d. Intoxicationen, 1893; also, Kobert and Stillmark, Arbeiten des pathologischen Institutes, Dorpat, 1889, iii.

[2] Martin: Proceedings Royal Society, London, vol. xlvi.

[3] Hellin: Dissertation, Dorpat, 1891.

[4] Smithsonian Contributions, Washington, 1886.

[5] Rend. Acad. Linc., Rome, 1888, 1889.

[6] Loew: Ein natürliches System der Giftwirkung, München, 1893, p. 79.

[7] Correspondenzblatt für Schweizer Aerzte, 1890.

[8] Zeitschrift für Hygiene, vol. xv. p. 1.

[9] Uschinsky (Centralblatt f. Bakteriologie, Band ix. p. 316) succeeded in cultivating the tetanus-organism in a medium composed of salts and asparagin, and free from albumin. The tetanus-poison obtained from this source still gave the reactions mentioned.

[10] Berliner klin. Wochenschrift, 1890, p. 241.

[11] Archiv. für Hygiene, vols. ix. and xiv.

which produce toxins, only 26 produce proteolytic ferments, and that, on the other hand, of 134 known enzyme-producing bacteria only 25 are pathogenic—that is to say, toxalbumin-producing.[1]

The blood-serum of the dog acts with great energy upon the red blood-corpuscles of the rabbit, and Buchner[2] observed that while the blood-serum of these animals is separately capable of destroying a considerable number of typhoid-bacilli, yet when the serum of the dog and rabbit are mixed, the destructive influence of the mixture upon the typhoid-bacilli is less than that possessed by either serum alone. As bearing on this question, the experiments of Robert Hartig[3] on the fungus-parasites of plants are interesting. Thus, while certain of the ferments of this origin dissolve the cellulose of plants and not the intercalated wood-gum, there are others that dissolve the gum and have no effect upon the cellulose. According to Hartig the oak is attacked by ten distinct parasites, each of which produces a different ferment. Two of these dissolve starch—are amylolytic—when acting separately, but when combined they are entirely without action on this substance. Does this not suggest an analogy with the mutual destruction of neutralization of the bactericidal principles of the blood of the rabbit and dog?

Further, we have grounds for believing that the blood possesses the power of destroying the true ferments, as it does certain of the bacterial products, and, moreover, that the true ferments may act in a manner similar to the vegetable toxalbumins in conferring immunity. Hammersten[4] has shown that if rennet and milk are injected separately into the circulation of rabbits the coagulating influence of the ferment upon the milk is much diminished; and Hildebrand[5] has demonstrated an antiferment in the blood of animals rendered immune from certain of the enzymes, especially emulsin. He[6] has succeeded, moreover, in rendering rabbits more resistant to the bacillus cuniculicida, and even of protecting them against the organism by previously inoculating them with and making them immune to emulsin.

Heating solutions of many of the toxalbumins or blood-serum to 60° C. destroys their activity. Blood-serum kept for thirty minutes at a temperature of 55° C. loses, according to Buchner, its power to destroy

[1] Fermi and Pernossi (Zeitschritt f. Hygiene und Infektionskrankheiten, Band xvi. Heft 3, p. 435) believe that they have proved that the enzyme produced by the tetanus-bacillus is distinct from the poison tetanin, and that the latter is not a ferment.

[2] Münchener med. Wochenschrift, 1892.

[3] Lehrbuch der Baumkrankheiten, Berlin, 1882. (Quoted by Loew, ibid.)

[4] Schmidt's Jahrbücher, 1887, Band ccxvi. p. 115.

[5] Virchow's Archiv, vols. cxxi., cxxii., cxxxi.

[6] Hildebrand: Münchener med. Wochenschrift, 1894, No. 15, p. 283.

bacteria and likewise its globulicidal action. Exposed to a temperature of 54° C. for the same time I have found that dog's serum is still globulicidal for rabbits, although its activity is diminished.

Blood-serum that has lost its bactericidal and globucidal properties by being kept at a temperature of 60° C. for thirty minutes has not suffered coagulation, nor have demonstrable optic or chemic changes occurred in it. The lost bactericidal property, it is believed by Emmerich and Tsuboi,[1] can be restored by alkalinization and dialysis, a circumstance that they bring forward as bearing upon the question of the chemic *versus* the vital action of the serum. Buchner,[2] it must be mentioned, disputes the results of Emmerich and Tsuboi and claims that the difference that they observed in the effects of the heated serum before an dafter alkalinization is explicable on other grounds, as, for example, the alteration in the heated serum as a culture-medium. None of these authors, however, mention the effect of this treatment upon the globulicidal property of the serum, and to determine this I have made the following experiments:

The blood-serum[3] of a dog, collected after twenty-four hours, was tested as to its toxicity, by injecting 1.5 per cent. of the body-weight into the ear-veins of a rabbit. The animal was profoundly affected, soon manifested hæmoglobinuria, and died in ten hours.

A second half-grown rabbit, whose blood-count at 11.15 A.M. was 6,080,000 red corpuscles to the c.mm., received 1 per cent. of its weight of unheated serum. It was dead in five minutes, from thrombosis of the right side of the heart. A second blood-count, made from the lake-colored blood of the left ventricle taken during the death-struggle, showed 3,872,000 red corpuscles per c.mm.

A third control-rabbit received 1 per cent. of its weight of the same serum heated to 55° C. for one hour, without any effect whatever.

Seventy-five c.cm. of the heated serum were now made alkaline with 7.5 c.cm. of a 3 per cent. solution of pure caustic soda and dialyzed through gut for forty-three hours against seventy-six litres of normal salt-solution. The whole volume of serum now equalled 90 c.cm.

A white-mixed rabbit weighing 1600 grammes, whose blood-count on March 21st was 5,664,000, and on March 22d 6,368,000 per c.mm., received at 10.20 A.M. an amount of dialyzed serum which corresponded to 1 per cent. of the body-weight of the original serum (16 c.cm. of the

[1] Centralblatt für Bakteriologie, vols. xii. and xiii.

[2] Centralblatt für Bakteriologie, vol. xii. p. 855.

[3] In all cases in which blood-serum was used the drawn blood was placed upon ice immediately after having been obtained.

original = 19.5 c.c. of dialyzed serum). No immediate effect was produced. At 11.10 A.M. the blood-count was 4,938,000 per c.mm. No hæmoglobinuria or other unfavorable symptom had appeared. On April 11th the rabbit was still alive and apparently well, the blood-count on this day showing 5,856,000 per c.mm.

Another rabbit, weighing 1800 grammes, whose blood-count on March 21st was 6,112,000 per c.mm., and on March 22d 6,208,000, received at 10.30 A.M., March 22d, 1.5 per cent. of its body-weight (27 c.c. of the original = 32.5 c.c. of dialyzed serum) of the dialyzed serum. At 11.25 A.M. the blood-count was 5,180,000 per c.mm. At 2 P.M. this rabbit, which appeared perfectly well, received a second quantity of 1.5 per cent. of its body-weight. The blood-count at 3 P.M. showed 4,980,000, and on April 11th, at which time the animal appeared normal, it was 5,952,000.

The second animal, it will be noted, received double the certainly lethal dose of the normal, unheated serum, with relatively slight effect. From these experiments it must be concluded that the globulicidal action of the serum is certainly not entirely restored, and if at all, to a minor degree only, by alkalinization. The animals are still living, and so far show no evidence of the toxic effects of the serum. Hence, it would appear that the toxic properties are also lost at this temperature.

In considering the pathologic action of the toxic proteids derived from the several sources mentioned upon susceptible animals we shall find reason to treat of them together. If we consider for a moment the production of immunity, which, for many bacteria and their products, is such a well-known fact that it need not detain us, we shall find that evidence is not wanting for the albumins derived from the higher plants, the phytalbumoses. However, up to the present time no one has succeeded in rendering animals permanently immune to the animal toxic proteids, although Sewell[1] claims to have secured in pigeons an immunity to snake-poison which disappeared after a time.

Ehrlich[2] has shown that mice, which are relatively quite susceptible to ricin and abrin, can be rendered in a high degree immune from the action of these bodies. As concerns ricin, he found that a solution having a concentration of 1 to 750,000, in the quantity of 1 c.c. per 20 grammes of weight will often kill mice in from two to four days; and in the same dose a solution of 1 to 200,000 will kill these animals without exception. The local effect of the drug is so intense that it is necessary to resort first to feeding, by which means a low grade of immunity

[1] Journal of Physiology, 1887.

[2] Deutsche med. Wochenschrift, 1891.

is established, which can then be increased by subcutaneous inoculations. The immunity appears quickly. I have repeated Ehrlich's experiments and have confirmed his results.

For example, two mice were fed with gradually increasing doses for ten days, and at the end of this time an immunity equal to the natural resistance of five, as determined by subcutaneous inoculations with control-anmials, was already present. From now on the doses were rapidly increased, so that on the twelfth day the resistance was equal to ten; on the sixteenth, to eighty; on the eighteenth, to one hundred and forty; and on the twentieth day, to two hundred and fifty.

These figures are all low, as the calculation is based on the surely lethal dose of 1 to 250,000, and the highest grade of immunity was not determined. Even at this time the immune animals were found not to be indifferent to the mode of introduction; for of two mice, which up to this point had acted in all respects alike, one was inoculated into the peritoneal cavity, and died in one and a half hours, while the other, after subcutaneous inoculation with the same amount (1 c.c. of a 1 to 1000 solution), became slightly sick, but was perfectly well the next day. The blood of the mouse that succumbed was laky. The blood of immune animals, *i. e.*, in a condition that Ehrlich denominates ricin-proof, contains an antitoxic body, which by simple admixture outside the body with a solution of ricin is capable of rendering the latter innocuous.

Having in mind the production of immunity from this substance, I have experimented on rabbits with dog-serum, but so far without success. On the contrary, I found that animals that had withstood one dose of a dog's serum would succumb to a second dose, given after the lapse of some days, or weeks, even when this dose was sub-lethal for a control-animal.

Two rabbits received ½ of 1 per cent. and 1 per cent. of their body-weight respectively of dog's serum, twenty-four hours old, on January 19, 1894. With the exception of hæmoglobinuria, indisposition to move, and increased respiration, no ill-effects were noted. The animals still showed hæmoglobinuria on the following day. These symptoms disappeared, and apparently the rabbits entirely recovered. On February 12, 1894, each received 1 per cent. of their body-weight of dog's serum intravenously. A control-animal also received 1 per cent of its body-weight of the same serum. The two animals that had been previously inoculated died in two and twelve hours respectively; the control-animal showed only hæmoglobinuria, which disappeared after a day or two.

The pathologic lesions produced in animals by these various poisonous substances have been very imperfectly studied up to the present time.

The contributions that have been made to this subject refer almost exclusively to the gross changes in organs and tissues, or consider simply the effect that is produced upon the blood, especially the alterations in coagulability. Hellin, who studied, he says, one hundred organs or parts of organs obtained from animals dead of abrin-poisoning, could discover nothing abnormal, except thrombi composed of red blood-corpuscles. The whole pathologic process in these cases has been considered to depend upon an active gastro-enteritis, thrombosis of the vessels of the stomach and intestine, necrosis and ulceration from digestion. To this is to be added, for those cases in which death occurs rapidly with symptoms of convulsions, thrombosis of the cerebral vessels. Just as little attention has been given to the tissue-changes caused by the inoculation of animals with foreign serum. Heretofore it has sufficed to consider as the cause of death in the immediately fatal cases the coagulation of the blood, especially in the right heart and main pulmonary vessels, or the production of widespread capillary thrombosis. All experimenters have, however, encountered cases in which, as death has been delayed for several days, this explanation was insufficient, as thrombi were not demonstrable. Ponfick has shown that the kidneys suffer injury in secreting the hæmoglobin liberated by the breaking up of the red blood-corpuscles, and he attributes many cases of death to the resulting nephritis and blocking of the kidney-tubules with methæmoglobin casts.

It will be my especial purpose to point out the insufficiency of these views. A study of the pathologic changes in the organs has convinced me that the extent, and not the absence of tissue-alterations, is most remarkable.

At this time there are comparatively few that accept the bacterial origin of disease who will question the mode in which the organisms act, *i. e.*, whether it is the presence of the bacteria as such in the tissues, or the products of their vital activities, that is responsible for the harm that is done. Neither the mechanical influence, nor the effects of depriving the body of a certain quantity of oxygen and albumin, will longer suffice to explain their action. It is true that as living beings the bacteria require certain materials in order to build up their bodies and maintain their functions, and these they secure from the available stores of their surroundings, but it is just as certain that in the performance of their activities they produce excrementitious substances, which are in turn discharged into the host. It is to these substances, of which we have already spoken, that the attention of chemists and pathologists has of late been directed. And the study of their composition and properties has not only brought much light into this field of work, but has opened

up new avenues of investigation, at the same time awakening new and unexpected hopes for the future of therapeutics.

It is now three years since Professor Welch and myself[1] published a short communication on the lesions produced in the tissues by the soluble products of diphtheria-bacilli. This paper, following one describing the histologic lesions in kittens, guinea-pigs, and rabbits caused by the inoculation of the bacilli themselves, confirmed in all essential respects the first paper.

The study of the relation of the bacillus diphtheriæ to the disease diphtheria indicated that the constitutional symptoms of the disease, which, in human beings, are often of the gravest nature, were due to an absorbed poison, and not to the organisms themselves. The separation of the poison from cultures in a dry, but impure state, by Roux and Yersin, and the reproduction through its agency of the constitutional symptoms, including the paralysis, of the disease may be said to have been conclusive. Yet it remained to find in the animals experimented upon lesions similar to or identical with those described by Oertel in human beings.

I shall not here undertake to give an account in detail of these changes. They have since been seen and studied by a number of investigators, and constitute an additional link in the chain of evidence of the causal relation of the bacillus diphtheriæ to diphtheria in human beings. But I wish to state that these lesions are found extensively in the tissues. They are present in the lymphatic glands generally, in the spleen, liver, intestinal canal, kidney, and heart-muscle, and are characterized by a death of cells in the affected parts. Strangely enough, the peculiar changes are not equally distributed throughout the affected organs, as one would naturally infer when it is considered that we have to deal with a soluble substance circulating in the blood; but in the lymph-glands and viscera these lesions tend to occur in well-marked areas or foci.

This, then, has brought us face to face with a new problem in pathologic histology. Heretofore we were wont to separate the focal from the diffuse lesions. The latter class, such as commonly attend infections and intoxications, we have long since learned to know under the term given by Virchow, of "parenchymatous degeneration," the "cloudy swelling" of the older writers. This is the type of lesion that was believed to result from the action of a soluble poisonous substance in a certain concentration when the influence is continued for some time. The focal lesions, such as tubercle, a focal abscess, were regarded as the result of the lodgement and increase of the particular injurious agent in the areas affected.

[1] Johns Hopkins Bulletin, 1891.

Nor are we required to alter our views of the relation of the focal lesions in diphtheria to the soluble poison by the observation of Frosch,[1] since confirmed by several others, that in human beings a few diphtheria-bacilli are often found in the liver, the spleen, and other organs. The number of organisms is, in the first place, altogether insufficient to explain the lesions; there is, moreover, an entire absence of evidence of relation between the organisms and the tissue-changes, and, finally, there are cases in which no organism can be demonstrated, and, in animals, we now know that they are not necessary to the production of the focal lesions.

But I wish to present still more conclusive evidence of the relation between soluble poisons and focal lesions. For example, certain lesions ought long ago to have led to the suspicion that even soluble substances may act upon one part of the body and not upon another.

Consider, for instance, the action of snake-poison. What could be more impressive than the production of capillary focal extravasations of blood in the serous membranes in consequence of a subcutaneous inoculation of the poison? In this case the action of bacteria or other essentially "living agent" can, by the experiments of Mitchell, Reichert, Formad, and others, be entirely excluded.

I have made a series of experiments with poisons of another kind. From the published accounts of the action of ricin and abrin upon animals, little can be learned concerning the minute pathologic changes induced by these bodies. Manifestly these substances offer an opportunity to study the question of the relation of soluble poisons to focal lesions. In them we have, as I have already shown, substances that in many respects resemble the bacterial poisons; and, according to Martin, the action of abrin is suggestive of snake-poison. They thus seemed to constitute ideal substances for study.

The first experiments which I made showed me that the picture of the pathologic changes given by Kobert, Hellin, Stillmark, and Ehrlich was very incomplete. In the main, subsequent work enabled me to confirm their results; but they have overlooked, it seems to me, the most striking and significant changes.

The samples of ricin and abrin which I employed in my experiments were made by Merck. The substances, which are supplied in the form of grayish-white amorphous powders, are insoluble in water, but dissolve readily and completely in a 10 per cent. salt-solution. After solution they can be diluted without change by addition of physiologic salt-solution or distilled water.

[1] Zeitschrift f. Hygiene u Infektionskrankheiten, Band xiii. Heft 1, p. 49.

One of the impressive results in the use of these bodies was the certainty of their action. After one has experimented with bacteria, the virulence of which is open to fluctuation, this constancy of action is a very striking characteristic. In this respect, again, we can see an analogy with snake-poison. Kobert has pointed out that 0.03 mg. per kilogramme of ricin is fatal to rabbits and cats, and probably dogs, if injected into their veins, and Ehrlich has shown that guinea-pigs are so susceptible that one gramme of the substance would suffice to kill not less than 1,500,000 of these animals.

My experiments have been completed only so far as to enable me to report upon the effects produced upon mice, guinea-pigs, and rabbits. I have had among these animals very acute and chronic cases. The acute cases present such a characteristic clinical and pathological picture as to be unmistakable.

The lesions about to be described could be produced almost with the certainty of a chemic reaction.

I shall not give the detailed protocols of the cases, but will content myself with a description of the pathologic changes in general, and shall, in the first place, summarize a few typical cases.

The intravenous inoculation of ricin dissolved in 10 per cent. salt-solution in the proportion of 0.3 mg. to 3 mg. per kilogramme of weight kills rabbits in from eighteen to twenty-six hours. In the cases of most rapid death, the axillary, inguinal, bronchial, and cervical lymphatic glands are found slightly swollen and softened. The peritoneal cavity may or may not contain an excess of clear fluid; the mesenteric glands at the attachment of the mesentery are also swollen and œdematous. The intestines, especially the small intestine, are distended and pale, their contents being soft, glutinous, and grayish-white in color, and resembling in appearance cholera-stools. The patches of Peyer, in both the small and the large intestine, are elevated, swollen, and pale. They present a reticulated aspect in consequence of the greater swelling of the lymphatic follicles than of the intervening mucous membrane. The heart is filled with blood, the right ventricle being especially distended. The blood is fluid; or soft, dark clots may appear. Neither the kidneys nor the lungs show especial alteration. The spleen is slightly swollen and softened, the liver large, soft, and yellow in color.

The animals that receive a smaller dose and live longer, say from twenty to twenty-six hours, show more pronounced lesions. All the superficial lymphatic glands are greatly swollen and dark in color. The spleen is often much enlarged, tense, and deep purplish-red in color. The kidneys are congested; sometimes the adrenals also. The mesen-

teric glands are much swollen, œdematous, and hemorrhagic. The peritoneal cavity often contains bloody fluid, and there are many subserous hemorrhages into the peritoneal layer of the intestines and mesentery. In some cases there are so many hemorrhages into the omentum that the picture presented reminds one of snake-poisoning. The intestines are distended with semi-fluid, glutinous contents, which often shows streaks of blood. The mucous membrane of the intestines is congested, and here and there small hemorrhages are observed; the latter correspond at times with dilated bloodvessels in the serosa filled with dark, clotted blood. Peyer's patches present the most striking lesions, and are uniformly swollen and congested. The swelling is apparent at once through the serosa upon opening the peritoneal cavity and examining the intestines, and the glands often reach such a size that they project into the lumen of the intestine for a distance of two millimetres. At times small points of hemorrhage occur in and around the swollen patches, which always present a reticulated surface. In the stomach ulcers are sometimes found. The liver is dark in color, often much congested, and presents to the naked eye foci of yellowish or yellowish-white color, which at times are surrounded by hemorrhagic zones. A few of the inoculated animals were pregnant, and in these there were without exception hemorrhages into the fœtal sacs.

The microscopic changes are well marked. In the lymph-glands hemorrhages are commonly present, and the vessels are greatly dilated and packed with red blood-corpuscles. Many of the lymphatic elements are necrotic; cells with fragmented nuclei are common, and this fragmentation is often extensive. Intermingled with the foci of fragmentation are numerous karyokinetic figures. The lymphatic apparatus of the intestines shows in an analogous manner the destructive influence of the poison, but in this situation the cell-death is much more extensive, and the swelling of the follicles is clearly due in part to an increase in number of lymphoid elements. Nuclear figures are found in considerable numbers. In the intestines the destructive process is not limited to the lymphatic elements in the follicles, but those in the villi suffer extensively, and the epithelial elements are as little spared. Fragmentation and necrosis with rapid cell-multiplication by karyokinesis are present here also. The spleen shows changes similar to the lymph-glands, and these are localized in part in the Malpighian bodies.

The liver presents in many respects the most interesting changes, and a variety of forms of cell-death are met with in this organ. In the capillaries of the liver, which are greatly dilated, the endothelial cells are sometimes fragmented and necrotic, and the leucocytes suffer a sim-

ilar change. But in the liver-cells themselves the process reaches its height. The yellowish and yellow-white areas visible to the naked eye correspond to foci of coagulation-necrosis of liver-cells. The liver-cells in these areas are still preserved in some instances, but they are hyaline in appearance and devoid of nuclei. At times the nuclei can still be made out in the form of fragments. In other foci the cells are much altered in appearance and staining properties, and the nuclei have undergone another form of necrosis. They have not fragmented, but have died as a whole, becoming paler and paler until they finally fail to stain, with apparently a synchronous alteration in the cell-protoplasm. Still other cells have given up most of their protoplasmic material and appear as almost empty vesicles, with here and there a trace of protoplasm. Again, a group of cells will be converted into a reticulated substance suggesting fibrin ; and, indeed, these foci of necrotic cells often give a reaction with Weigert's fibrin-stain, while the remainder of the tissue does not retain the dye.

These foci of necrosis are often surrounded by large quantities of nuclear detritus—to such an extent, indeed, as to exclude the possibility of its having been derived altogether from the tissue nuclei. Some of the detritus must have come from emigrated cells, attracted, as we now know commonly happens, to these necrotic foci, where they suffer the same fate as the tissue-elements. An interesting feature was noticed in connection with the lymphatics in the interlobular spaces of the liver. They were at times choked with nuclear detritus. Manifestly such an amount of nuclear material could not come from the cells lining the lymphatics, nor from the cells of the lymph. There is only one interpretation possible of this appearance : it represents the nuclear detritus of the tissues and emigrated cells which had been swept by the lymph-vessels into the current. To accomplish this it is probable that an increased lymph-current is necessary.

That in the short space of time—about twenty-four hours—rapid cell-proliferation occurs in the lymph-glands we have adequate evidence, and we also have reason to believe that the same thing occurs in the liver. Around a focus of necrosis, about 1 mm. in diameter, in the periphery of which the capillaries were greatly dilated and literally choked with nuclear fragments, there were evidences of cellular proliferation in the rapid multiplication of the liver-cells, forming at times actual giant-cells.

The studies of Podwyssozki[1] have shown that in rabbits, after injury

[1] Zeigler's Beiträge, vol. i

to the liver, cell-division by karyokinesis has already begun on the second day, and by that time the various stages of nuclear division are present. He also observed on one occasion liver-cells with colossal dividing nuclei, in which no indication of division of the cell-bodies could be made out; from these he believed that giant-cells were formed.

That the liver of rabbits under certain circumstances possesses marked capacity for regeneration has been shown by the experiments of Ponfick, who, after removing large portions of the organ, found that compensatory hypertrophy of the remaining parts took place.

In this description I have had nothing to say of the alterations of the blood described by Kobert. The thrombi of red blood-corpuscles which he found were also met with in my specimens. But they cannot, I think, be regarded as playing an essential part in the production of the lesions.

When we attempt to explain the phenomena that we have just described, great difficulties are at once encountered. There are, as will be readily admitted, several questions of no small interest involved. For example, what determines the localization of the activity of the poisonous agent to such a large extent upon certain structures? Why do the lymphatic elements everywhere suffer so disproportionately? Are there in the body special tissues whose function it is to destroy, render innocuous, or eliminate the injurious substances? And as regards the lesions in the intestinal tract, is it not a matter of indifference whether we introduce the poisonous agent into the blood, by the stomach, or subcutaneously?

Moreover, how are we to account for the selection (for such it seems to be) of certain groups of cells on which the greatest stress of the poison is exerted? Shall we be obliged to fall back upon an hypothesis with which we are familiar enough in form, but as far as ever from understanding? I refer to the assumption of a difference of resistance of certain cell-groups of an organ, in consequence of which they fall an easy prey to the poisons which other cells can resist. Or, again, do the areas of necrosis, as has also been suggested, represent foci of especial enzyme-activity, points at which the poison increases, with the result finally of causing the death of the animal, and the lesion described? These are fundamental questions, and doubtless not all to be answered at the present time. But we have certain facts in our possession, derived from experiments, which may aid us in the solution of some of these problems.

Koeppe,[1] working in Ludwig's laboratory, and proceeding on the basis

[1] His u. Braune's Archiv, 1891.

that the lymph flowing into lymph-gland is poorer in cells than the outflowing lymph, supposed that if the lymph-entrance and lymph-exit were both closed an increase in the size of the gland would take place. He accordingly ligated the afferent and efferent lymph-vessels of one of the cervical lymphatic glands of the dog, and examined the gland, comparing it with its fellow on the other side. To his entire amazement, he found that after two weeks the gland operated upon was much smaller than its fellow, and showed upon microscopic examination fewer mitotic figures. The interpetation of this experiment seems clear: the lymph is the normal excitant of the lymph-gland, and upon its presence depends the production of lymph-corpuscles within the gland. This conclusion is made the more probable by the further observations of Koeppe, that the arterial blood supplied to the gland, so far from being an aid, is a hindrance to the multiplication of the lymph-corpuscles.

From his experiments on lymph-formation, Heidenhain believed that he had proved that the separation of lymph from the blood does not depend upon a process of filtration, but is to be regarded as due to a secretory activity of the cells lining the capillaries. According to him a number of substances are capable of so acting on the capillary walls in the dog as to cause an elimination of an increased quantity of lymph, amounting often to several times the usual amount as measured by the outflow from the thoracic duct. Among the most active agents are the enzymes derived from the salivary, pancreatic, and gastric secretions. Although Heidenhain[1] considered that his experiments proved that the increased lymph-flow is quite independent of the blood-pressure, yet Starling[2] has just shown that in a number of his experiments there was an increased capillary pressure in the liver, whence a large part of the lymph was derived, and it will be recalled that in the liver in our experimental animals the capillaries are much dilated, often compressing the rows of liver-cells.

These facts are, I think, very suggestive. On the one hand, we have learned that the lymph is an excitant of the lymphatic glands, and on its presence depends the formation of lymphoid cells, and, on the other hand, it has been demonstrated that certain ferments may act as the cause of an increased lymph-flow. It is pertinent, I think, since the histologic evidence that an increased flow was actually induced by these enzyme-like bodies is before us, to inquire whether or not the rapid increase in the lymphatic elements can in part be attributed to this cause.

[1] Pflüger's Archiv, Band xlix. See also Hamburger Zeitschrift für Biologie, Band xxx. p. 143.

[2] Starling: Arris and Gale Lectures on the Physiology of Lymph-formation. Lancet, 1894, 3683 et seq.

The variations in the circulation of the blood in the organs must be considered as bearing on the production of such focally distributed lesions as are here described. That the circulation is not equal in all parts of an organ at all times is indicated by observations upon living animals, and the capillary circulation especially is subject to wide variation.

I would ask a consideration of the effect this difference may have in bringing about such focal effects as we have encountered in the liver. We have seen that the action of the poisonous agent is exerted in part upon the capillary walls. The necrosis, fragmentation, and regeneration of endothelium indicate this. I would also point out that the injury to the capillary wall is nowhere so great as in the areas in which the necrosis is found. This fact suggests the possibility that, in certain capillaries in which the circulation was much diminished in rapidity or was temporarily at a standstill at the time when the irritant acted with the greatest intensity, such damage was done the capillary wall that a freer transudation took place into the tissues than elsewhere, resulting in the destruction of cell-groups; and Cohnheim[1] has shown that the lymph will be more concentrated the greater the permeability of the vessel-wall.

I have already alluded to the fact that in such areas there is an abnormal accumulation of leucocytes. The general blood contains an increased number of these cells, but there are relatively many more in the areas of necrosis.

We now know, thanks to the researches of Stahl,[2] Pfeffer,[3] Leber,[4] Buchner,[5] and others,[6] that certain stimuli of a chemic nature attract and repel these as well as other cells. In undergoing necrosis, certain chemic changes take place in the tissues, through which the leucocytes are attracted to them, but some bacterial products are still more positively chemotactic than are those substances derived from cells. In order that this attraction shall be exerted, Pfeffer discovered from the sperm-threads of ferns that the attracting substance could not be equally diffused throughout the fluid, but must exist in a greater concentration in one part than in others. There is an immediate movement toward the areas of concentration. It seems plausible at least that the poison

[1] Allgemeine Pathologie, 1882.

[2] Stahl: Botanische Zeitung, 1884.

[3] W. Pfeffer: Untersuch. a. d. botan. Institut zu Tübingen, Bd. i. and ii.

[4] Leber: Fortschritte der Medicin, 1888; Die Enstehung der Entzündung, etc., Leipzig, 1891.

[5] Buchner: Berliner klin. Wochenschrift, 1890.

[6] J. Massart and Bordet: Journal de la Soc. R. des Sciences Médicales et Naturelles de Bruxelles. 1890. Steinhaus: Die Aetiologie der acuten Eiterungen, Leipzig, 1889. O. Hertwig: Ueber die physiologische Grundlage der Tuberculin-wirkung, Jena, 1891.

which is conceived to be in greater concentration in the areas of necrosis exerts a positively attractive influence upon the leucocytes. To test this point the following experiment was made:

Capillary tubes were filled with a solution of ricin in normal salt-solution of varying strength, 1 to 100,000, 1 to 200,000, 1 to 500,000, 1 to 1,000,000, and introduced beneath the skin of rabbits. Control-tubes of sterilized physiologic salt-solution were also introduced. At twenty hours the ricin-solution of 1 to 100,000 proved to be strongly chemotactic, the open end of the tube being plugged by a thrombus of leucocytes, fibrin, and granular material. The weaker solutions exhibited positive chemotactic properties directly in proportion to the concentration. Only a few leucocytes were found in the tubes containing simple salt-solution.

There remains one other class of ricin cases, those of chronic character. These are more difficult to obtain, and very small doses must, therefore, be employed. I give a typical case:

On November 9th, a guinea-pig, weighing 600 grammes, received 1.5 c.c. of a 1 to 200,000 solution of ricin, subcutaneously. There was considerable local reaction; a hard node appeared over the site of injection, which, however, gradually disappeared. The animal lost weight for several days, but ten days subsequently to the inoculation had about regained the loss. On December 11th, seeming to have recovered, it was allowed to run about freely, and was often noticed to eat voraciously. Notwithstanding this fact, it grew more and more emaciated until December 29th, when its death occurred. At this time its weight was 270 grammes.

At the autopsy the emaciation was extreme. The lymphatic glands were not enlarged; the spleen was small and dark, the liver dark. The intestines contained semi-fluid, mucus-like and turbid contents, and the mucous membrane was much attenuated. Cultures made from the organs were entirely negative.

This picture is strikingly different from that observed in the other class of cases, and presents the features of a profound disturbance of nutrition. The microscopic examination of the tissues showed by the amount of iron-containing pigment in the spleen and liver that great hæmolysis had taken place. But of especial interest is the occurrence of atrophic patches in the kidneys.

Up to the present time we have considered the histologic lesions that are produced by the vegetable toxic proteids. I would now ask attention to the action of the blood-serum of man and dogs upon rabbits.

We know the experience of Landois,[1] Ponfick,[2] Daremberg,[3] Buchner,[4] Carter,[5] and others, that the immediate effect of the injection of serum is the destruction of the red and colorless blood-corpuscles. The animals, as often happens, may succumb immediately, in consequence of thrombosis of the right side of the heart and pulmonary artery, the respiratory function ceasing before the heart's action. Not uncommonly the animals experience less severe effects, and after a variable period of depression, increased frequency of respiration, weakness and hæmoglobinuria, apparently recover.

I have found dog's serum strongly globulicidal for rabbits. This statement is based upon the common occurrence of hæmoglobinuria that lasted from one to two days, as well as upon actual counts of the number of red blood-corpuscles. Doses of 1.5 per cent. of the body-weight were usually fatal to rabbits. In these cases death occurred either immediately or after ten or twelve hours. Quantities of 1 per cent. of the body-weight caused profound disturbances, including hæmoglobinuria and albuminuria, and less commonly anuria, and in a few instances immediate death. Some of these animals survived several days or weeks, and some even appeared to recover. They were, however, as we have seen, more susceptible to subsequent inoculations.

When death follows at once upon or soon after the inoculations, it is usual to find thrombi in the right side of the heart, which may extend into the pulmonary artery and its main branches. The rapid breaking up of the corpuscles liberates the fibrin-ferment, with consecutive coagulation of the blood in the vessels. The experiments of Naunyn[6] have shown that the red corpuscles yield the necessary ferment, and those of Schmidt and others that the white corpuscles, which are likewise destroyed by the foreign serum, are especially rich in this substance.

There are cases, however, in which great destruction of corpuscles has occurred, but in which coagulation has not ensued, and, indeed, under these circumstances the coagulability of the blood is diminished. We owe to the researches of Pekelharing,[7] Wooldridge,[8] Löwit,[9] Schmidt,[10] and

[1] Landois: Med. Centralblatt, 1874, p. 419.

[2] Ponfick: Berl. klin Wochenschrift, 1874, No. 28. Ponfick u. Bamberg: Arch. f. Path. Anat., Bd. lxii. p. 273.

[3] Daremberg: Soc. de Biologie, 1891, p. 719.

[4] Buchner: Münchener med. Wochenschrift, 1892, p. 120.

[5] Carter: University Med. Magazine, 1893, p. 170.

[6] Archiv für exp. Pathologie, Bd. i.

[7] Pekelharing: Festschrift f. Virchow, 1891, Untersuchungen über das Fibrin-ferment, Amsterdam, 1892; Ueber die Gerinnung des Blutes, Deutsche med. Wochenschrift, 1892.

[8] Wooldridge: Die Gerinnung des Blutes. Leipzig, 1891.

[9] Löwit: Studien zur Physiologie und Pathologie des Blutes und der Lymph. Jena, 1892.

[10] A. Schmidt: Zur Blutlehre, Leipzig, 1892.

others[1] a partial understanding of this difference. It will not be possible for me to enter into the details of this matter here; it will suffice to state that much depends upon the capacity of the organism to dispose of the liberated fibrin-factors and upon their behavior with regard to the calcium salts of the plasma.

The cases already alluded to, in which the death of the animals is delayed for a time, are of especial interest, as they show certain well-marked lesions. While the observations that I have made are more complete as regards the action of the serum of the dog upon rabbits, the serum derived from human beings apparently acts in much the same way. Permit me to say that these lesions resemble, but are not identical with, those described in connection with the toxalbumins of diphtheria, ricin, and abrin.

The tissues of animals dead of serum-poisoning which I have so far studied consist of the spleen, liver, kidneys, and lymph-glands. In the acute cases the spleen shows a tolerably rich fragmentation of nuclei situated especially in the Malpighian bodies; the liver contains foci of necrosis of liver-cells, and the renal epithelium is degenerated, and many methæmoglobin-casts block the kidney-tubules.

Of especial interest is an animal that died on the thirteenth day in which very extensive lesions were found:

A rabbit received on December 25, 1893, 1 per cent. of dog's serum, twenty-four hours old, intravenously, and was dead in twenty minutes after completion of the inoculation. A second rabbit weighing 1200 grammes received ½ of 1 per cent. of serum from the same source. There were no immediate perceptible effects. After the lapse of thirty minutes the expressed urine contained hæmoglobin-casts. For some days following the inoculation the animal appeared to be in perfect health, but about the seventh day it began to lose in weight, grew perceptibly weaker from day to day, and died on January 6, 1894.

The autopsy showed great emaciation. The peritoneum contained an excess of fluid; the axillary lymph-glands were enlarged; the intestinal lymphatic apparatus was apparently normal. The liver, which was firm in consistence, was roughened externally and dark in color. The kidneys appeared small; their capsules were not adherent, but their surface was granular. In the spleen, which was enlarged, were a number of white, wedge-shaped areas, the bases at the capsule, and quite firm in consistence. Attached to the chordæ tendineæ of the tricuspid valve was a

[1] Artur et Pagès, Arch. de physiol., ii. 1890. Lilienfeld, Du Bois-Reymond's Archiv, 1892, pp. 115, 167, and 500.

calcified thrombus as large as a split-pea. The urine contained albumin and tube-casts.

The microscopic changes were those of chronic interstitial processes in the liver and kidney. In the latter the tubules were in places atrophied and surrounded by a new growth of connective tissue; in other places the tubules were dilated and the epithelium lining them degenerated; but it was in the liver that the pathologic alterations could best be studied. The chronic changes were well-marked here also, and were such an accurate reproduction of cirrhosis in human beings that a separate description seems superfluous. Areas of newly formed and forming connective tissue, proceeding from the portal spaces and also from the capsule, were irregularly distributed throughout the organ; newly formed bile-ducts were numerous; but what was of especial moment was the association with this of another process, viz., acute degenerative changes in the liver-substance, which were often distinctly the starting-places of the sclerotic process.

In rabbits that died at a somewhat earlier period, after five or six days, I have not infrequently found coagulation-necrosis of liver-cells. To these areas leucocytes are not attracted in such numbers as in cases of diphtheria or poisoning with abrin or ricin; and in keeping with this difference I have found that capillary tubes containing dog's serum, when introduced beneath the skin of rabbits and removed after twenty-six hours, showed very slight positive chemotaxis only.

It is possible in the chronic cases to follow the progress of the pathologic process. The degenerative changes and the new growth of connective tissue can be studied side by side. There are necrosis and disintegration of liver cells, emigration of leucocytes and growth of connective tissue. The new tissue comes both from the surface-capsule and from the interlobular connective tissue, but not exclusively from these. Independent new-formations in the midst of the lobule occur, just as there are independent foci of necrosis in this situation. Here and there, where the connective tissue is advancing, the fast disappearing remains of necrotic cells can be seen; but where the sclerotic tissue is already well developed and new bile-ducts are well formed, this is not always possible. Finally, in the spleen, the white nodules resembling infarcts are masses of fibrous tissue.

The changes found in the organs in cases of serum-poisoning are, if I mistake not, of no slight importance. They indicate that it is necessary to enlarge our views of the damage that serum is capable of doing, a damage not limited to the corpuscular elements of the blood, for the tissue-cells are not indifferent to its action.

In the end the differences in the action upon the blood and tissues of the toxic agents discussed are not so great as their correspondences—a fact that emphasizes their chemic similarity. These substances so affect the tissue-elements as to cause degeneration and death, and their effects are followed by reparative processes that do not restore the integrity of the tissues. The relation that Weigert[1] several years ago maintained between parenchymatous degeneration and interstitial tissue-proliferation in the kidney, and which Ackermann[2] urged for the liver in chronic phosphorus-poisoning in rabbits, I have been able to follow in the cases mentioned in both organs, although most satisfactory in the liver.

Moreover, the chronic lesions, such as we have just studied, seem to be open to us for experimental study. Heretofore we have had to content ourselves with the production of degenerative changes, and have been excluded from imitating by experiments on lower animals the chronic proliferative processes in the internal organs of man.

In conclusion, the study of the tissue-changes that I have had the privilege of bringing before you has brought us from the consideration of acute degenerative changes of a focal character due to soluble poisons to the realization of the probability of their playing an important part in the production of chronic interstitial changes in animals, which find in cirrhosis of the liver and chronic nephritis analogies in human beings.

*April* 26, 1894.

---

## 6. *Disseminated tuberculosis.*

Exhibited by Dr. Daland.

There was tuberculosis of the lungs, with thick, adherent pleuræ and pericardium. Miliary tubercles were present in the brain and on the peritoneum, liver, and spleen, and the intestines were ulcerated. There were never any tubercle bacilli found in the sputum. The course of the disease was over six months. *May* 25, 1894.

[1] Volkmann's Sammlung klin. Vorträge, 1879, Nos. 162, 163.
[2] Virchow's Archiv, 1889, Bd. 115.

### 7. *Organs from a case of general tuberculosis in a child.*

Exhibited by Drs. McKee and Riesman.

William H. L., aged 4 years, colored. Father healthy; "mother takes cold easily;" she had one miscarriage, and three children died shortly after birth. One younger child in splendid health.

*Previous history.* A breast-fed baby. Dentition normal. Whooping-cough when two years of age, and measles three months ago. Had marked genu valgum, necessitating the use of braces.

*History of previous disease* dates from the attack of measles, since which time a cough has persisted. He had never been robust, but has lately lost much flesh. Fever is a nightly phenomenon, and when feverish he perspires freely, especially around the head. He is quite weak, and seldom cares for play.

*Status præsens, March* 25, 1894. An emaciated child with a large, somewhat rhachitic head. The limbs are thin, with loose flesh and prominent superficial veins (resemble the extremities of an old person). The child is a mouth-breather, and speaks in a harsh voice. Both chains of anterior cervical lymphatics present enlarged glands, and quite a mass is present in the right subclavian triangle; brassy voice.

The throat is somewhat bell-shaped, and the epigastrium is prominent. The chest movement is chiefly up and down, scarcely at all expansile.

Vocal and tactile fremitus are much increased all over the right chest. Percussion demonstrates imperfect resonance over both apices. Bronchial breathing is present over the right axilla, and expiration is somewhat prolonged at the left. Sibilant râles are present over the chest, and, upon taking a deep inspiration or coughing, moist râles are detected high in the right axilla.

*Treatment.* Cod-liver oil, raw-beef juice, salt-water bathing, and inunctions with sweet-oil.

12*th.* Mother states that the boy is better. Besides the afore-mentioned signs, there is now present over the left chest dulness below the angle of the scapula, and also a line of dulness running parallel with the vertebral column (the so-called stripe-dulness). There is also marked dulness at the right axilla, with a small patch of cavernous breathing toward the outer third of the clavicle. Very little information obtained by auscultation.

Marked stridor is present, and a ringing laryngeal cough. He was examined by Dr. Freeman, who reports:

"No enlargement of the faucial, pharyngeal, or lingual tonsils. The epiglottis and arytenoids are reddened and the vocal cords white."

16*th*. Much worse. Dr. Taylor saw him at home. Found his respirations very rapid, pulse running, and fever high. Complained of pain in the right side. His surroundings practically excluded physical examination. Under large doses of whiskey and the external application of poultices, followed by friction with camphor and sweet-oil, he rapidly rallied.

20*th*. Much better. Begged to be taken out, and, as the weather was mild, his mother carried him down stairs. Breathing not markedly accelerated and not at all embarrassed. Pulse strong—120. Evening temperature reached 103°. Moist râles are heard all over the chest, and the right side is *quite* flat upon percussion.

For over a week we lost sight of the boy, as the people moved.

29*th*. Died quite suddenly. He had seemed better all day, and toward evening asked to lie down. Died almost immediately.

Body of an emaciated mulatto boy of about 5 years of age. Marked wasting of all the muscles; rigor mortis moderate.

On opening abdomen the intestines appear pale; there is no fluid and no adhesions in the abdominal cavity. The vermiform appendix is larger than usual, but perfectly normal. There are a few tubercles on the parietal peritoneum.

*Thorax*. Lungs adherent to costal pleura. Pericardium normal; no tubercles on either surface; no excess of fluid.

Heart small and soft, but without microscopic abnormality.

At the root of the neck, corresponding to the manubrium sterni, there is a large mass about the size of a small apple, consisting of enlarged tuberculous glands. It is possible that the remains of the thorax form a part of this mass, but all its elements are so pressed together that separation is not readily accomplished. The mass was in contact with the posterior surface of the sternum anteriorly and posteriorly with root of the great vessels. Some of the glands showed moist, cheesy necrosis in the centre.

The left lung was tuberculous throughout, the disease being most advanced in the lower lobe posteriorly, where there was extensive cavity formation. The pulmonary tissue about the excavations was soft and pliable, and the finger readily penetrated it. The right lung was similar, but not so far advanced. Both lungs contained abundant fluid. The

bronchial glands at the hilus of the lung were enlarged and, to some extent, cheesy.

*Abdominal cavity.* The spleen was the seat of many large-sized tuberculous masses, yellowish in color, which gave to its surface an uneven, knobby character.

*Kidney.* The left kidney contained a few small tubercles on the cortex; the right presented no distinct nodules, but contained a few small whitish areas, ill-defined, about a millet-seed in size, the nature of which did not seem clear. The kidney substance was pale and the structure obscure. The suprarenals appeared normal.

*Liver.* Enlarged and light in color, and presenting a few rather large-sized tuberculous masses, which were peculiar in their exact circumscription from the surrounding hepatic tissue. At the transverse portion there was a large mass of glands forming a sort of collar about the vessels and ducts, enclosed in the gastro-hepatic omentum.

The gall-bladder was of rather light-green color, but the contained bile seemed normal.

The intestines were not opened. Externally nothing of a tuberculous or inflammatory nature was visible. Nevertheless, the mesenteric glands were greatly enlarged, although not cheesy.

The pancreas was soft, but appeared to be free from tuberculosis.

The brain and cord were not examined.

*Pathologic diagnosis.* Tuberculosis of lungs, miliary, and also cavity-formation; also caseous pneumonia. Old pleurisy. Tuberculosis of liver, spleen, and kidney. Tuberculosis of bronchial, mediastinal, and mesenteric glands, and those of the gastro-hepatic omentum. Tuberculosis, slight, of the parietal peritoneum.

*Microscopical examination.* Lungs: Section shows areas of a peculiar coagulation-necrosis, peculiar in the fact that they take the stain, and do so even more intensely than normal tissue. Contiguous to larger accumulation of this degenerate tissue are smaller foci, apparently produced by spreading along the intervening lymphatic channels. In addition, there is a caseous pneumonia—the affected air-vessels being filled with large round cells having distinct nuclei. This form of tuberculosis is common in children, in whom also the lymphatic channels are particularly apt to be the seat of the disease. The caseous pneumonia in children was formerly known as scrofulous pneumonia. It is almost invariably associated with enlarged and cheesy bronchial glands.

*Kidney.* The section through a tubercle presents the same anomalous coagulation necrosis to which reference was made when speaking of the lung. The non-circumscribed, pale, millet-seed-sized focus in the one

kidney, which was described in the notes of the autopsy, proved to be tuberculous, showing the same degenerative change.

The renal tissue, especially the convoluted tubules, were in an advanced degree of degeneration—cloudy swelling and fatty changes.

The cells are converted into finely granulated masses, and the lumina of the tubules around them are filled with cell-débris. There are no distinct casts.

The clinical symptoms must have been modified by the inadequacy of the kidney, which is so evident on microscopic examination. Amyloid change is not visible.

*Liver.* Here we find similar necrotic areas, which are surrounded by a concentric zone of newly formed cells, the nuclei of which are directed toward the centre of the degenerated patch. An approach to such an arrangement of spindle cells is visible in the other organs, but is most perfect in the liver. There is, in addition, considerable fatty infiltration of the liver.

*Pancreas* apparently normal. *June* 28, 1894.

---

### 8. *Alcoholic purpura hemorrhagica, associated with chronic interstitial nephritis.*

Exhibited by Dr. Daland.

The patient was a woman, aged 44 years, widow for three years; she had borne several children, and had had no miscarriages. She had led a rather hard life; no specific history; was subject to chronic alcoholism for some years, and her friends state that she drank, on an average, six glasses of whiskey daily. She remained in the hospital three weeks, during which time she showed œdema, shortness of breath, and hemorrhage from the nose, stomach, bowels, and bladder. The arteries were rather thick, the heart was enlarged, and there was an apex systolic murmur. The temperature was subnormal and the respirations were normal. These conditions continued until two days before death, when she complained of shortness of breath, and became somewhat delirious. One day before death she became unconscious, with grinding of the teeth and dropsy of the legs. A hot-air bath was administered with no immediate effects; the lips were cyanotic; the external jugulars were distended; the extraction of eighteen ounces of blood gave prompt

relief, consciousness was regained, breathing improved, and the horizontal nystagmus, 12 to the minute, disappeared. For some hours she had been breathing 6 or 8 per minute. This improvement endured for several hours, but the following morning death took place. The autopsy showed no ulcerative endocarditis, no phthisis, and no explanation for the purpura hemorrhagica, excepting the marked changes in the arterial system, which were due, in all probability, to chronic alcoholism. The changes due to chronic alcoholism were well marked by atheroma of the aorta and its larger branches throughout their course, and also in the bloodvessels at the base of the brain, in cirrhosis of the liver, chronic catarrhal gastritis with dilatation. The kidneys showed chronic interstitial nephritis, and one was reduced to fully one-half its normal size. There was œdema of the lower extremities and of the brain. Heart weighed fourteen ounces. Both right and left heart were considerably hypertrophied, more especially the left ventricular wall, which measured from one-half to three-quarters of an inch in thickness. The valves were normal, and the apex systolic murmur could be best explained by the dislocation of the papillary muscle, permitting regurgitation through the mitral orifice.

The following purpuric spots were present: A few spots, purplish in color, on the right shoulder, and occasionally one over the body, one on the neck, right side below the jaw, and still another over the right ramus of the jaw.

The nose and throat were not examined. The lungs showed no hemorrhage, but were œdematous. Stomach showed signs of an old hemorrhage, and beneath the mucous membranes were considerable extravasations of blood, and at one point a shallow ulcer, from which blood had oozed. There was acute hemorrhagic duodenitis and enteritis, and at various points considerable extravasations of blood had taken place beneath the mucous membrane. This was also true to a less extent of the mucous membrane of the bladder. The lining membrane of the uterus was hemorrhagic, and blood had been effused in the veins immediately above the tunica externa of the thoracic and abdominal aorta, in the region where the bronchial arteries are given off.

*September* 13, 1894.

## 9. *A review of some of the disputed points in connection with diphtheria and conditions with which it has been confounded.*

Read by Dr. A. C. Abbott.

A retrospective view of the confusion of ideas that existed upon diphtheria prior to the discovery of its etiology illustrates how essential to a correct understanding of the manifold phases of a disease is a knowledge of its cause. From the time of Bretonneau to the date of the observations of Klebs and of Loeffler much valuable information was accumulated, but in the state of knowledge in existence at the time it could hardly be estimated at its true value.

It may be of profit to pass in review some of the more important features of the disease. and endeavor to learn in how far opinions expressed by the early observers have been supported or refuted by the results of later methods of investigation.

The first observations that attracted attention to the disease, diphtheria, as we know it, were made in 1826, by Bretonneau, of Tours, who endeavored to extricate from the chaotic mass of ideas existing at the time some definite conception of a malady that had hitherto been loosely classed with a group of gangrenous and necrotic conditions with which it had but little in common, either clinically, anatomically, or etiologically. He suggested the use of the term "diphtheritis" for the disease, which was characterized by the presence of a skin-like pellicle upon the mucous membrane of the throat, for the reason that he considered this the feature by which it was distinguishable from all others with which it might be confounded. It may be mentioned at this point that in 1771, Samuel Bard, of New York, in a monograph entitled *An Inquiry into the Nature, Cause, and Cure of the Angina Suffocativa, etc.*, gave a description of the clinical and anatomical manifestations of diphtheria that was quite comparable, in its essential details, with that subsequently given by Bretonneau.

Though Bretonneau's teachings constituted a step in the right direction, and did much to relieve the confused notions upon the malady, it was not long before objections were raised to the grounds taken by him. The teachings of Home, from 1765, to the effect that there existed a disease, designated as croup, and characterized by the formation of pseudo-membranes in the larynx, were revived, and there was henceforth a division of opinion, some adhering to the teaching of Breton-

neau, viz., that all the pseudo-membranous processes in the upper air-passages were identical, while others, with Home, believed in the existence of two distinct affections. With the hope of clearing away doubts and shedding some light upon the disputed point, the question was taken up by the pathologists, and through the labors of Virchow, Weigert, Cohnheim, and their pupils, the two processes were subjected to histologic study. The outcome of this work was a classification based entirely upon anatomic grounds, and a nomenclature that was used only in its anatomic sense. From this standpoint it was taught that there existed: First, a true croupous process, characterized by the deposition of a fibrinous pseudo-membrane upon the surface of the mucous membrane; second, that there existed a true diphtheria, similarly characterized by the local appearance of a fibrinous condition, which was not, however, confined to the surface of the mucous membrane, but extended into it; and, third, that there existed a mixed anatomic condition known as diphtheric croup, in which there appeared both the superficial pseudo-membranous deposit and the involvement of the deeper underlying structures; this latter being the local condition commonly seen in true diphtheria. The entire process in all cases was seen to be a coagulation-necrosis, the direct effect of the causative irritant, a process characterized by a combination of cell-death and inflammation, the coagulation and fibrin-formation resulting from the contact between the inflammatory serous exudate and the fibrin-ferment supplied by the dead cells.

While this is the anatomic nature of the local process in diphtheria, and constitutes the condition known as diphtheric, it is, nevertheless, one that occurs as a result of the action of many irritating agents; and, while always present as the local manifestation of diphtheria, it is often seen in other parts of the body than the throat, and in conditions that are etiologically distinct from diphtheria.

It is easy to see, therefore, that the use of the terms diphtheric and croupous in their anatomic sense, regardless of the causes underlying them, may, and doubtless often does, give rise to confusion. Though of the utmost importance in elucidating the nature of the tissue-changes seen locally in laryngeal and pharyngeal pseudo-membranous inflammations, these observations afforded but little aid to the clinician in recognizing the nature of the various exudates *intra vitam*. He was still obliged to rely, as hitherto, upon the symptoms and the naked-eye appearances of the exudations; and it was then, as now, the experience of every clinician that these features of the disease are far too variable to admit of a positive diagnosis in all cases.

The means afforded for the correct diagnosis of the nature of these

conditions constitute the first and most important outcome of the discovery of the cause of diphtheria. With the demonstrations by Loeffler, that there existed in the diphtheric deposits in the throats of all persons sick of diphtheria a distinct species of micro-organism that was not present in other anatomically similar exudates, that the organism could readily be recognized, isolated and cultivated, and that it possessed the power, when introduced into susceptible animals, of reproducing conditions anatomically identical with those occurring in man afflicted with the disease, grounds for confusion could no longer exist, and from that time the question has been not so much with regard to the anatomic character of the local pathologic changes as to the presence or absence of the specific causative factor. If this agent is present, diphtheria exists; if it is absent, then the local conditions and constitutional manifestations must be attributed to some other cause, and the disease is not diphtheria.

Thus it soon becomes manifest that the dispute over the relation between diphtheria and so-called membranous croup was to be incontestably settled. By the bacteriologic and histologic study of the latter condition it has been found to be due to the activities of the same micro-organism that is concerned in the production of diphtheria, and to present fundamentally the same histologic conditions that are found in the diphtheric exudate. I am aware that there are still individuals who adhere to the opinion that true, specific, fibrinous laryngitis occasionally occurs spontaneously; but, unfortunately for this view, it is usually supported by clinical evidence alone, and has rarely, if ever, been formulated from the results of bacteriologic study of the cases.

Still another local process characterized by fibrinous exudation has been shown by bacteriologic analysis to be etiologically identical with diphtheria. I refer to the affection of the mucous membrane of the nostrils known as membranous rhinitis, a condition that receives but little attention because of the mildness of its clinical course, but which, nevertheless, depends for its existence upon the activities of the same organism that is concerned in producing diphtheria. Because of their apparently innocent nature these cases are not considered as menacing to the health of individuals with whom they come in contact, and are not, therefore, regarded as dangerous, and yet examples are not wanting to show that they are communicable from one person to another, and there is some evidence to prove that true diphtheria has been contracted from them.

Another important question upon which there has been a conspicuous divergence of opinion, and which was also answerable only through the

light shed by modern methods of research, is as to the local or constitutional origin of diphtheria. The careful study of an enormous number of cases occurring in man, and produced experimentally in animals, has demonstrated that the disease is purely local in its origin, and that the pseudo-membranous processes in the throat, the secondary manifestations in the internal organs, and the clinical symptoms, are one and all the result of a soluble poison, produced by a micro-organism that has its seat of primary invasion in the mucous membrane of the upper air-passages. It is important to note that the disease is not a septicæmia, in the sense of being associated with a distribution throughout the body of the micro-organisms causing it, but is strictly a toxæmia primarily, though a septic condition may be engrafted upon the toxic one later in its course.

Even the tissues in the throat in which diphtheria-bacilli are growing give evidence of the effect of the poison independently of the immediate presence of the bacteria by which it was produced. In sections through the pseudo-membranes one sees that the most superficial layers contain bacteria in large numbers, among which the bacillus diphtheriæ can easily be recognized by its peculiar morphology; beneath this one sees a feebly stained layer rich in cells but containing little or no fibrin, and in this layer the Klebs-Loeffler bacillus is often the only organism present; and especially is this the case just above the still deeper densely stained fibrin-layer. The layer next to the mucous membrane is rich in fibrin, but contains no bacilli, and, as a rule, no bacilli are found in the underlying necrotic mucous membrane.

The Klebs-Loeffler bacilli, we see, not only do not invade the infected mucous membrane, but do not usually even penetrate through the entire thickness of the diphtheric pseudo-membrane. The picture presented suggests a conflict at long range, so to speak, the invaders being the bacteria whose weapons are the easily soluble poisons manufactured by them upon the surface of the affected part, and through the absorption of which the tissues undergo the peculiar metamorphosis seen in this disease. If our bacteriologic investigations are conducted further into the remote internal organs, there too, we find an absence of the specific micro-organisms. This is true not only for the internal viscera generally, but likewise for those organs affected with the peculiar form of localized necrosis described by Oertel as so common in this malady.

It is not, however, unlikely that during the course of the disease a few scattered organisms may accidentally gain access to either the lymphatic or vascular circulation, and thus become deposited in remote organs, as they may also be carried thither through the phagocytic activities of

wandering leucocytes. The possibility of finding diphtheria-bacilli in the internal organs at autopsies upon individuals dead of the disease has recently been demonstrated by Frosch, Wright, and others; but nothing that we have learned from the study of the conditions occurring in the deeper tissues leads to the belief that they are in any way dependent upon the immediate presence of the specific bacilli.

The poisons produced by the bacilli at the seat of primary invasion, to the absorption of which, as has been said, the secondary manifestations and constitutional symptoms are due, are likewise produced by the bacilli when growing under artificial conditions of cultivation.

When isolated, free from the organism by which it was manufactured, it is seen to be capable of causing in susceptible animals identically the same group of tissue-changes that are produced when the bacilli themselves are introduced. The interesting and important features in connection with it are its nature, being analogous chemically to the venom of serpents, and the potency of its poisonous properties, which exceeds in degree that of almost any other substance with which we are acquainted. Roux and Yersin present some idea of the intensity of its action; they have estimated that 0.4 milligramme of the dried poison is sufficient to kill eight guinea-pigs weighing each 400 grammes, or two rabbits weighing each 2 kilogrammes, a degree of toxicity almost beyond the grasp of our imagination.

In 1888 Oertel directed attention to a group of pathologic conditions that he found in the internal organs of individuals dead of diphtheria; and more recently this subject has attracted additional attention through similar observations made by Welch and Flexner upon animals that had died of the experimental form of the disease. These changes consist of foci of a peculiar form of necrosis, varying in extent and scattered irregularly through the internal organs. They are characterized by nuclear fragmentation of the cells of the parts affected. The fragments into which the nuclei are seen to disintegrate are conspicuous for the readiness and intensity with which they become stained and for the manifold shapes which they are seen to assume, at times appearing as little else than dust-like particles strewn through the necrotic and hyaline area, or again as clusters of granules indicative of the location of the nucleus from which they originated; again, all manner of irregular shapes that may be likened to whetstones, crescents, balloons, clubs, dumb-bells, etc., will be seen. Frequently a nucleus will appear as if drawn out so that it may present a tail-like elongation, and again it may be pinched and distorted. In certain spots there may be almost an absence of stained cells and fragments, but it is usually possible to detect faint outlines of

cells and more or less of a refractive, granular substance that give the staining reaction of fibrin. In the investigations of Oertel and of Welch and Flexner these necrotic areas in greater or less extent have been detected in all the internal viscera, being particularly prominent in the lymphatic apparatus, in the liver, and in the spleen. To a limited extent the same process was also detected in the muscles of the heart. While not strictly confined to the disease, diphtheria, this nuclear fragmentation is nevertheless always an accompaniment, and affords, by the rapidity with which it is produced, another illustration of the energy of action possessed by the poison producing it. It has been seen to occur in the internal organs of animals with all its characteristics in so short a time as thirty-eight hours after inoculation with small quantities of cultures of the bacillus diphtheriæ.

Through similar methods of investigation a satisfactory understanding of the pseudo-membranous anginas of scarlatina and measles has also been reached. These processes are not, as has been supposed, of a diphtheric nature, etiologically speaking, though it is often impossible to distinguish them from diphtheria by the means ordinarily possessed by the clinician. When not complicated with diphtheria the local manifestations in these diseases are etiologically quite distinct. They are due, as a rule, to a streptococcus similar to and probably identical with that concerned in the production of erysipelas and phlegmonous forms of inflammation. A clearer understanding of the pathology of these conditions has recently been reached through the studies of Booker, who states that from the material examined it is safe to say that the local changes seen in the throats of patients with scarlet fever and measles are anatomically distinct from those seen in diphtheria, and that the anatomic alterations observed in the deeper structures of the body resulting from the scarlatinal virus, unlike those secondary to diphtheria, are accompanied by the immediate presence of streptococci, and are largely suppurative in nature, appearing to be the direct outcome of the organisms associated with them.

From this imperfect view of the more important of the mooted questions in connection with diphtheria and allied pseudo-membranous inflammations of the upper air-passages, it is manifest that such doubts could only have existed as a result of incomplete acquaintance with the causes underlying the several processes; and with the exact means of differentiation that have been afforded by newer methods of investigation our conception of the nature of these processes, particularly of diphtheria, occupies a place on a par with that of tuberculosis, anthrax, and other infectious maladies from which so much of value has been learned.

The discovery of the bacillus diphtheriæ and the practical application of the knowledge gained by this discovery has shed a flood of light upon these processes that could not possibly have been obtained through any other channel of study.

As bacteriological study of diphtheria and conditions with which it might be confused met with wider application, certain irregularities were encountered. It was discovered that the causative factor, the genuine bacillus diphtheriæ, was simulated in morphologic and biologic peculiarities by what was believed to be another organism which was distinguishable from it only by the absence of pathogenic properties. This latter organism was known as the pseudo-diphtheric bacillus, and was considered as distinct from the genuine diphtheric bacillus simply because of its inability to kill susceptible animals when inoculated into them subcutaneously. As this organism has been seen in conditions not believed to be diphtheria, as it had been seen in mild cases of a doubtful nature, and as it had been seen in genuine diphtheria in association with the true diphtheria-bacillus, it became necessary to determine its relation to the virulent bacillus diphtheriæ before the value of the latter organism as an absolute means of diagnosis could be firmly established. The simplest way out of the difficulty was to consider them as in no way related, but as entirely distinct species, and this, in fact, is what was done.

It was, however, soon observed that the genuine, virulent diphtheria-bacillus was liable to fluctuate in the degree of its pathogenic properties, at times possessing these to such an extent that when inoculated into guinea-pigs death resulted in from thirty-six to forty-eight hours, while again the period of incubation was much longer, often reaching five and six days, and in not a few cases organisms were obtained from undoubted cases of diphtheria that failed to give more than a temporary local reaction when inoculated into these animals. In many cases of diphtheria the two organisms have been seen to be simultaneously present, and in the observations of Roux and Yersin it was detected that as the disease advanced toward recovery the number of the less virulent and non-virulent forms became more numerous in proportion. Singular as it may seem, the only or principal point of distinction between these two organisms, if distinct they are, was held to be the ability of the one to cause the death of the inoculated animals, and no attention whatever was paid to the nature of the local reaction that was caused by the organism that failed to kill. I have taken occasion to examine the condition of the tissues at the seat of inoculation in animals into which non-virulent forms of this organism had been introduced, and have found that, though the death of the animals did not follow the inoculations, locally, tissue-

changes indistinguishable, save in degree, from those produced by the fully virulent forms were to be found; there was the same œdema, though less in extent, the same hyaline condition of the muscle-fibres, the same fibrin-exudation, and the same characteristic fragmentation of nuclei that one finds locally in the animals inoculated with the true, fully-virulent bacillus of diphtheria. This, I think, offers another argument in favor of the opinion already expressed elsewhere by Roux and Yersin, myself and others, that the diphtheric bacillus and the so-called pseudo-diphtheric bacillus are one and the same organism, the latter representing the former, whose virulent properties have become diminished.

It must not be inferred, from what has been said in regard to the gradual appearance of the attenuated forms of this organism with the establishment of convalescence, that when recovery is complete the organisms are no longer virulent. Such a conception would not accord with the results of observations upon convalescents from diphtheria. The study of a large number of cases has demonstrated that with recovery many of the diphtheric bacilli in the throat not only do not lose their virulence and vitality, but retain both these properties for days and weeks, and it is often possible to isolate from the throats of convalescents from diphtheria virulent diphtheria-bacilli for as long as two or three weeks after all traces of the disease have disappeared, a point of inestimable importance in establishing rational prophylactic measures against the spread of the malady.

It is interesting that it is not always possible to establish a dependence between the clinical course of the disease and the degree of virulence possessed by the organisms causing it. From many of the most alarming cases organisms are often isolated that are much less virulent, as determined by their period of incubation in animals, than those seen in other cases, the clinical manifestations of which are much milder. There are undoubtedly modifying conditions at play, upon whose nature we can do little more than speculate—conditions possibly, of individual susceptibility or tolerance to the action of the poison, or some local factor favors or retards the absorption of the poison from the point at which it is produced. Certain it is that in its clinical, anatomic, and certain of its bacteriologic phases, diphtheria varies within very wide limits, but possesses at the same time certain features that serve to distinguish it from other diseases with which it is likely to be confounded.

With the further application of bacteriologic methods to the study of diphtheria, attention was turned to the question of immunity against the disease, and finally to the discovery of a cure.

The outcome of experiments conducted principally by Behring, Kita-

sato, Wernicke, Wassermann, Brieger, Ehrlich, Roux, Martin, and others is to apply to diphtheria the principles of the important observations made by Behring and Kitasato upon tetanus, to the effect that the blood-serum of animals that have been immunified against tetanus possesses not only the power of conferring immunity against this disease to animals into which it may be injected, but that it also possesses the property of arresting the malady after it is already in progress. This observation represents the foundation-work of blood-serum therapeutics, around which so much interest has lately centred.

Through the combined labors of those cited, and more especially through the investigations of Behring, it has been found possible to do in diphtheria just what he and Kitasato did in tetanus, viz., it is possible to render susceptible animals immune to diphtheria by the introduction into their tissues of the modified poisons produced by virulent diphtheria-bacilli, and to obtain from the blood of these animals serum that will not only afford immunity to other susceptible animals, but which, as in the case of tetanus, has the power of arresting the disease after it has already been in progress for a time. When this method of treatment is applied to animals that have purposely been infected with pure cultures of the bacillus diphtheriæ, and not too long after infection, the results are so uniformly favorable as to place the operation far beyond the experimental stage. If, however, the disease is permitted to proceed for a time, the results are not to be counted upon with such certainty; in short, the success of the operation is dependent upon the stage to which the disease has progressed. In mixed infections, that is, those in which some other organisms, especially the streptococcus, commonly associated with the bacillus diphtheriæ in human diphtheria, are present, the experiments of Roux and Martin indicate that the results of the treatment are still less certainly favorable.

You are all too well acquainted with the astonishingly favorable statistics that have been presented recently for hospitals in which this method of treatment has been employed to require mention of the reduction in the death-rate from diphtheria since the use of this method, and I believe it safe to predict that as our knowledge upon the subject increases and as we become more familiar with some of the obscure points the results of the treatment will be still more favorable.

As to the *modus operandi* of the immunifying process and the therapeutic action of the serum of the immunified animals, we are still in the dark; but the hypothesis of Buchner, to the effect that the introduction into susceptible animals of the modified poisons produced by virulent bacteria serves as a stimulus to the integral cells of the tissues, and

awakens a reactionary change that results in the appearance in the circulating blood of a something that is highly antagonistic to the fully toxic poisons that may subsequently gain access to these animals, seems most reasonable, and at present meets the requirements of the case more satisfactorily than any of the other explanations that have been advanced.

*November* 8, 1894.

---

10. *A case of accidental sponge-grafting of the conjunctiva of eighteen months' duration.*

Reported by Dr. A. G. Thompson.

The case herewith reported presents two interesting features:

I. The conditions under which the foreign material was introduced and the length of time it remained attached to the conjunctiva.

II. A beautiful illustration of the so-called process of sponge-grafting, which may suggest for it some further uses in eye-surgery.

The case was that of a colored girl, sixteen years old, who came to Wills Hospital, complaining that there had been something growing in her right eye for the preceding eighteen months. On examining the eye I found a small swelling on the outer portion of the lower lid, giving the appearance of a fair-sized chalazion. As I drew down the lower lid to expose the palpebral conjunctiva a small mass protruded, yellowish in color, from which exuded a thin, purulent discharge, and resembling a papillomatous growth in appearance. Subsequent questioning showed that the girl had been an inmate of the House of Correction, having been discharged from that institution last August, after two years' confinement, and that six months after admission she noticed one morning this growth in the eyelid. She consulted one of the female attendants, and was told to bathe the eye in hot water. After two weeks of this treatment and the growth not disappearing, the attendant resorted to surgical means and attempted to remove it with a pair of forceps. This time she was more successful, securing a portion of the sponge and with it some of the conjunctival tissue, and causing some bleeding from the lid.

As I could not account for the presence of the growth, and also as it resembled sponge in character, I directed my questions with that object in view. The girl then stated that all the girls in her department washed themselves with one large sponge several times a week, and that often after washing she had noticed small particles of sponge adhering to her

skin. With this history I then examined a piece of the mass microscopically, and found it to be indeed sponge. The photograph taken did not turn out well, so I cannot show the position and relation of the sponge in the conjunctival sac. On examining the lid more closely I found the sponge firmly implanted in the palpebral conjunctiva toward the outer side of the lid, yellowish in color, oval in shape, and with ragged edges; it was 8 mm. long, 7 mm. wide, and 3.5 mm. high. As for the remaining portions of the eye, they were apparently normal, with the exception of that portion of the ocular conjunctiva that came in contact with the sponge when the eyelid was closed. Here the vessels were somewhat enlarged and the conjunctiva slightly hyperæmic.

It would seem improbable that a foreign material the size of the piece of sponge stated, consisting of a substance subject to very septic surroundings (*i. e.*, a sponge used in the House of Correction on all kinds

FIG. 1.

Showing granulation-tissue intersected by sponge fibres. × 300.

of people until it became so rotten that it was falling to pieces), could remain so long in the conjunctival sac without causing the slightest discomfort and only a very little irritation; but I think, if we look into the condition more closely, the absence of symptoms can be accounted for, as the sponge, being of soft animal tissue, becoming attached to the conjunctiva, the granulations springing up in the interstices of the sponge virtually made it a part of the lid itself, and it therefore caused no more irritation than any other small piece of granulation-tissue in the same position.

As a case of sponge-grafting, the formation of new tissue, as seen in the sketch of the section, shows it to be a perfect success.

This method of using sponge to replace lost tissue was first suggested by Prof. D. J. Hamilton, of Edinburgh, in 1881, who recognized the fact that in the organization of tissue the blood-clot or fibrinous lymph plays only a mechanical and passive part in any situation in which the organized tissue becomes replaced by a fibrous cicatrix. This being the case he hit upon the idea of using sponge as a substitute, as the interstices of the sponge resembled the fibrinous network in a blood-clot or in fibrinous lymph, and at the same time being an animal tissue it would undergo tissue-digestion.

The process that occurs when a piece of sponge is placed in contact with an exposed surface and remains long enough is that a quantity of fibrinous lymph is effused into the sponge; this lymph becomes organized, and then is replaced by granulation-tissue, which extends and fills the interstices of the sponge, with, finally, a total absorption of the sponge-skeleton itself, leaving only a mass of cicatricial tissue.

The girl refused to allow me to remove the entire sponge at that time, but agreed to the removal of a small portion. This was excised, with a small piece of the surrounding tissue, which was cut and mounted by Dr. Charles W. Burr. In hardening the section the free portion of the sponge, that part not being infiltrated by new tissue, was detached from the remainder of the graft. This accident is almost impossible of avoidance, owing to the destructive effect of the hardening fluid on the sponge. I am, therefore, unable to show all the stages from the deep granulation-tissue to the lymph in free sponge.

The section presented the following appearance: A mass of granulation-tissue in different stages of development intersected in all directions by a network of yellowish bands that represent the sponge-skeleton. The base of the new growth is composed of embryonic, more or less developed, connective tissue, which in the deeper layers has quite replaced the sponge-fibres. Above the deep part, gradually shading from it and filling the interstices of the sponge, is the new tissue, which consists of new granulation-tissue, blood-cells, leucocytes, giant-cells, etc.

The evidence of tissue-growth by aid of sponge-graft is clear, but the mode of absorption or disappearance of the sponge-skeleton is as yet unknown, although this undoubtedly occurs, as we find in the deeper layers that the sponge-skeleton is more reduced in size and the fibres are fewer in number.

It is commonly believed, although the section does not show it, that absorption is due to an eroding influence of the giant-cells analogous to

the action of the osteoclasts in bone-formation, as they are found in great numbers closely adhering to sponge-fibre.

In my sections there are several places showing giant-cells in close contact with the fibres, but I cannot see any evidence of absorption from this cause. I find, also, that these giant-cells are numerous in only the superficial portions of the graft, where we would not as yet look for absorption, and are extremely rare in deeper portions where the absorption takes place. My own opinion is that absorption is more probably due to a softening or separation of the fibre of a laminated structure by the pressure of the densely packed surrounding granulation-tissue, and, finally, absorption by the juices of the tissues, as the disappearance of the sponge is seen in only the deeper layers and apparently affecting the whole fibre at the same time.

Fig. 2.

Showing absorption of sponge-fibres. × 450.

So far as I can learn, this is the first instance in which sponge has been grafted, either intentionally or accidentally, on the conjunctiva. From the undoubted evidence of formation of new tissue, from the non-irritating properties of the sponge as seen, from the means under which it was introduced and the length of time it remained in the conjunctival sac, and from the microscopic proof of its final absorption, we have every reason to believe that sponge-grafting is a valuable means of replacing tissue lost by burns or injuries to the eyelids, which are eventually followed by ectropion, entropion, symblepharon, etc., and from the disfigurement caused by shrinking cicatrices.

Dr. Abbott: The sponge, of course, acts the part of a blood-clot.

Dr. McFarland remarked that demineralized sponge was used by Hamilton. He considers the giant-cells analogous to osteoclasts. The greatest argument in favor of the degeneration origin of giant-cells is the fact

that the nuclei are in the periphery and the degeneration near the periphery. He has never seen any distinct evidences of karyokinesis, and only once saw anything approaching it. *January* 24, 1895.

---

11. *A case of primary sarcoma of the spleen, with extensive metastasis.*

Exhibited by Dr. S. Solis Cohen and Dr. Riesman.

The body from which these specimens were procured at autopsy was that of a married man, aged 42 years, an insurance agent by occupation, who had been under the care of Dr. James Robinson, to whom we are indebted for the following history:

Six months ago the patient began to complain of dyspepsia; previous to that time he had always been healthy; his family history was also good.

In October, 1894, he was seized with sharp pain in the left hypochondrium, and had frequent eructations of gas. The pain increased, and he became gradually very feeble, and was forced to abandon his work on January 2, 1895.

He was most comfortable when sitting upright; the pain in the left side was not constant, but when it occurred required morphine to control it.

The urine on two occasions contained a trace of sugar; albumin was not present. There was no vomiting; the anorexia was absolute. A slight cough existed.

On examination the patient was found profoundly anæmic; the spleen was greatly enlarged, extending nearly to the umbilicus, and the notch could be plainly felt; its surface was smooth. Separate, firm nodules extended in a chain entirely across the epigastrium. The base of the left chest was dull on percussion.

A parotid abscess (on the right side) developed ten days before death, and was opened, but only a small amount of pus was obtained. The patient had an intermittent fever. The first blood-count showed 3,600,000 red corpuscles, 50 per cent. hæmoglobin, and white to red as 1 : 69. Later the relation of red corpuscles to white corpuscles as about 1 : 20. A differential count of the leucocytes showed a great increase in multinuclear cells; the eosinophiles were not much increased.

The autopsy was made on February 15, 1895, and the following notes taken:

Body of a greatly emaciated man; the right parotid region is enormously swollen, and presents a gaping incision. The abdomen is distended, and the area of splenic dulness is greatly enlarged; hard masses are palpable in the epigastrium.

*Abdomen.* Muscles and subcutaneous fat almost wasted away; some dirty, grayish-yellow fluid in the peritoneal cavity; in the left hypochondrium a large mottled tumor involving the spleen; along the greater curvature of the stomach large, firm masses representing enlarged lymphatic glands. The mesocolon is studded with numerous nodules the size of a cherry; the stomach is enlarged and presents hard masses along both curvatures.

The spleen is adherent in the lower part to several intestinal coils; the gastro-splenic omentum is infiltrated with new growths; there is considerable perisplenitis in the region of the spleen involved by the tumor. The organ is enormously enlarged and estimated to weigh from six to seven pounds. The tumor occupies chiefly the lower part of the spleen, extending upward to the second notch. On superficial examination it seemed not to involve the spleen at all, but to be simply attached to it; this is due to the fact that the upper part of the spleen is quite normal in appearance and is sharply demarcated from the diseased portion. The splenic vessels, however, enter the tumor, and on section the continuity of the tissues becomes evident.

The surface of section of the tumor is bright yellow, and moderately soft. The tumor occupies an area about the size of two fists, and is pretty well circumscribed, although not really encapsulated. An apparent capsule is formed by a narrow rim of splenic tissue about one-half or three-quarter inches thick, which is also infiltrated. The rim has a different color from that of the tumor, being a mottled reddish-white, the white area representing the neoplasm.

The liver is slightly enlarged, pale, somewhat fatty; not cirrhotic, and free from new growths.

The kidneys present nothing of special interest. The suprarenal capsules appear normal.

The stomach is extensively infiltrated with tumor-tissue along the curvatures, the mucous membrane is not much altered, except at the cardia, where the new growth has been broken through and has become ulcerated on the surface. The œsophagus is normal. The lesser omentum contains large tumor masses; the cœliac glands form a large, infiltrated and fixed mass.

The pancreas cannot be fixed in its usual position, as all the remaining tissues occupying this part of the abdomen are united in one large

mass of new growth. On section of a part of this mass a little pancreatic tissue is discovered.

*Thorax.* On the left half of the diaphragm, or rather on the pleura covering it, there are numerous secondary growths varying in size from that of a millet-seed to that of a half-dollar. The larger ones are somewhat pigmented and form expanded polypoid growths with a short pedicle.

The left pleural cavity contained about 1500 c.c. of a straw-colored fluid; a small amount of fluid is found on the right side.

The left lung contains numerous small nodules on the surface and along the lower edge. The bronchial and mediastinal glands are enlarged.

The heart contains chicken-fat and currant-jelly clots; the mitral valve and the intima of the aorta are atheromatous.

*Pathologic diagnosis.* Primary sarcoma of spleen with secondary deposits in the spleen, the stomach, the omentum, the mesocolon, the pancreas, the diaphragm, the lung, the retroperitoneal, bronchial, and posterior mediastinal glands; parotid abscess; pleural effusion.

*Microscopic examination.* The primary tumor as well as the secondary nodules present the typical features of small, round-cell sarcoma.

Remarks. The number of cases of primary sarcoma reported in literature is very small. Weichselbaum has reported two cases—one a small tumor in a man aged twenty-one years. It was a fibro-sarcoma and was situated in the convex surface of the somewhat enlarged spleen. The other was a case of multiple endothelium, also in a man of twenty-one years. Billroth extirpated a spleen the seat of lympho-sarcoma from a woman aged forty-three years. The blood had been normal. In one case there was marked leucocytosis. The patient died from a recurrence of the new growth. Fritsch has also recorded a case of sarcoma of the spleen in a woman aged thirty-one years. The blood-count was normal. The patient was living a year after extirpation of the spleen, but in a wretched state; the liver, curiously, had become greatly hypertrophied. Cases of primary lympho-sarcoma are also reported by de Ritis, Lancéreaux, Trélat, and Clark.

One of the points of interest in our case was the blood state—there was a marked leucocytosis, which seemed to justify the original diagnosis of splenic leukæmia, but the differential count not showing normal increase of eosinophile cells was a point against the diagnosis. This fact, together with the existence of the large nodes in the epigastrium that could be traced from the spleen across toward the right, led to the thought that the case might be one of primary and splenic sarcoma.

Another interesting feature is the course of the distribution of the

secondary nodules. The absence of involvement of the liver, while the lymphatic glands of the abdomen were involved, seems to indicate that metastasis followed the course of lymphatics instead, as is the general case in sarcoma, the bloodvessels. Yet it is remarkable that the liver escaped, since the blood of the spleen passes through it.

The glycosuria noted on two occasions may have been due to involvement of or pressure on the pancreas by the tumor-mass.

The existence of secondary nodules in the left lung and left pleura, and not in the right lung and pleura, would point to the probability that the spread to these parts had occurred through lymphatic paths passing from the under surface of the left diaphragm to the upper, and not through the blood.

It is worthy of note that the pleural effusion, which evidently was connected with the malignant growth of the left pleura, was not hemorrhagic. *February* 14, 1895.

---

12. *Section of nodule of glanders from the lung of a horse, showing the bacillus mallei.*

Exhibited by Dr. H. W. Cattell.

The clinical diagnosis had been made by the use of mallein. At the post-mortem typical ulcers were found in the mucous membrane of the nose, and nodules, some of which were already calcified, were seen in the lungs. A section of one of the uncalcified nodules stained by Loeffler's method was shown in which the bacillus mallei were well seen both in and without the cells. Attention was also called to the normal but adenomatous-like bunching of the bronchi. *March* 14, 1895.

---

## The Pathology of Diphtheria.

13. *The bacillus diphtheriæ and some of the characteristics by which it may be identified.*

Read by Dr. A. C. Abbott.

The portion of the discussion that has been allotted to me to-night does not admit of my bringing to your notice anything of which you

have not already heard from other sources, or anything that is not now to be found in modern text-books on bacteriology.

In view of this fact I have thought it advisable to utilize the time allowed me by making a general demonstration rather than by presenting to you a formal paper on the subject. I shall not, therefore, make many allusions to the important literature bearing upon the histological development of our knowledge of diphtheria and its etiology, but shall confine myself strictly to an objective consideration of the morphological, cultural, and pathogenic peculiarities of the Klebs-Loeffler *bacillus diphtheriæ*, and wherever possible will supplement the remarks by the exhibition of illustrative specimens or diagrams.

If in the course of our studies upon diphtheria as it occurs in man one scrapes from the diphtheritic deposit in the fauces a minute particle of the false membrane and smears it upon a cover-slip, dries and stains it, one will find upon microscopic examination that there is present a variety of bacteria of different morphology; some of them being spheres, others coarse rods; some long, others short. Associated with this heterogeneous collection, however, a group of organisms will be observed, the individuals of which, though differing in outline the one from the other, have, nevertheless, more or less of a general family resemblance to one another. Some of them will be spindle-shaped; others will be like little dumb-bells; pairs of lancet-shaped bodies joined at their broad extremities will present; again, short rods appearing to be made of shorter segments will be noticed, and, in addition, a number of irregular, clubbed, flask-shaped, and bizarre varieties may be detected in the field. These are the diphtheria bacilli, and it is by their marked lack of uniformity in outline that one identifies them in the scrapings from the diphtheritic false membrane. Not only does the irregularity in their outlines point to their nature, but the peculiar manner in which they take on the staining material is an important aid to their identification. They are rarely stained uniformly, but, as a rule, are seen to present alternating faintly and deeply stained areas, and not rarely present a peculiar appearance, consisting of the presence of minute, round, deeply stained, almost black dots or points at different parts of their protoplasm.

The diphtheria bacillus grows well on the majority of artificial culture media, but on some much more rapidly and luxuriantly than on others. It is easy, therefore, to obtain a growth of the organism by smearing a bit of the diphtheritic false membrane over the surface of suitable nutritive media and retaining this at the temperature of the body. The growth thus obtained is not, however, a pure culture of this organism, but is usually mixed with colonies developing from some of the other

organisms associated with the *bacillus diphtheriæ* in the pseudo-membranes.

The medium that is most satisfactory for the cultivation of this organism, and through the employment of which it can be most easily isolated from the throat in pure culture, is the solidified (coagulated or gelatinized) blood-serum mixture recommended by Loeffler, which consists of a mixture of three parts of blood-serum and one part of neutral or slightly alkaline nutritive bouillon, containing 1 per cent. of glucose.

If one inoculates a tube of blood-serum with a particle of membrane from the diseased throat, and keeps it at the temperature of the body, there will appear upon the surface of the serum in from twelve to eighteen hours a number of dull, dense, whitish, or yellowish-white points of 0.5 to 1 mm. in diameter. These, as a rule, represent colonies of the diphtheria bacillus, from which it is easy to obtain, by appropriate means, the organism in pure culture.

There will also be seen on the surface of the serum smaller points of different appearance, which represent colonies of other organisms with which the *bacillus diphtheriæ* was associated. They are rarely as far advanced or as conspicuous as the colonies of *bacillus diphtheriæ*, and it is this distinction between the diphtheritic bacillus and the non-diphtheritic organisms in their rate of growth on blood-serum that renders this medium such an important aid to the rapid detection and isolation of the *bacillus diphtheriæ*—it grows much more rapidly, as a rule, on blood-serum than do the other bacteria with which it is commonly associated.

If the diphtheria bacillus be isolated in pure culture on blood-serum and kept at 38° C. for three or four days, the appearance presented by its individual colonies is that of round, elevated, grayish-white, or yellowish-white masses of from 1 to 3 mm. in diameter. They are usually elevated at the centre, where they are denser than at the periphery. The surface of the colony is at first slightly moist, but gradually becomes dull and dry in appearance. Sometimes cultures will be encountered that gradually take on a yellowish appearance, often becoming decidedly yellow after a week or ten days.

If one makes a similar inoculation from the membrane in the throat on agar-agar, one finds, after twelve to eighteen hours at the temperature of the body, that here colonies will be seen, many of which are conspicuous for their size, while others will be so small as hardly to be discernible by the naked eye. The conditions found, however, on microscopic study, will be just the reverse of those seen on the blood-serum

tube. Here the diphtheria bacilli develop very slowly and are among the smallest of the colonies, while the other bacteria, in which we are not interested, grow rapidly, and usually go to form the larger, more conspicuous colonies.

If the colonies of *bacillus diphtheriæ* be studied on plates of nutrient agar-agar, and especially agar-agar to which 6 per cent. of glycerin has been added, they will be found to pass through a series of interesting and characteristic phases in the course of their development—beginning as microscopic, coarsely granular masses in the depths of the medium, they ultimately reach the surface as growth progresses, and spread laterally over the surface, giving rise to small, very thin, dry, irregularly scalloped or serrated pellicles that often present a number of longer or shorter cracks or rents extending from the periphery toward the centre. Under the microscope they are now usually marked by a dense central mass, the original colony around which has developed, and spread laterally for 1 to 2 mm., the thin pellicle above referred to.

Another medium in which this organism grows in a more or less characteristic fashion is bouillon. The bouillon is not uniformly clouded, as a rule, but presents the appearance of a clear, transparent fluid, in which, when shaken, small, white clumps are seen to have settled to the bottom. Sometimes, however, there is a uniform clouding, but if a drop of such a culture be examined microscopically in the form of a "hanging-drop," it will be seen that the clouding is due to the presence of clumps of bacteria, too small to be detected by the naked eye, and probably of such low specific gravity that they do not readily settle to the bottom of the liquid.

In ordinary neutral bouillon the reaction is changed to acid by the growth of this organism, which acid reaction ultimately (after a week or ten days) gives way to alkalinity, which is permanent. There are exceptions to this.

It grows on ordinary nutrient gelatin, but so slowly that this is not considered a favorable medium to employ for its isolation. Its colonies on gelatin do not reach their full development much before a week. When fully developed they appear as elevated, dense, slightly umbilicated, round masses that are more or less marked by concentric rings.

It grows on potato, and presents usually a condition analogous to that given for the genuine *bacillus typhi abdominalis* as seen on this medium—viz., the growth is invisible, though it may be tolerably abundant. At times cultures are encountered that grow slightly visible on

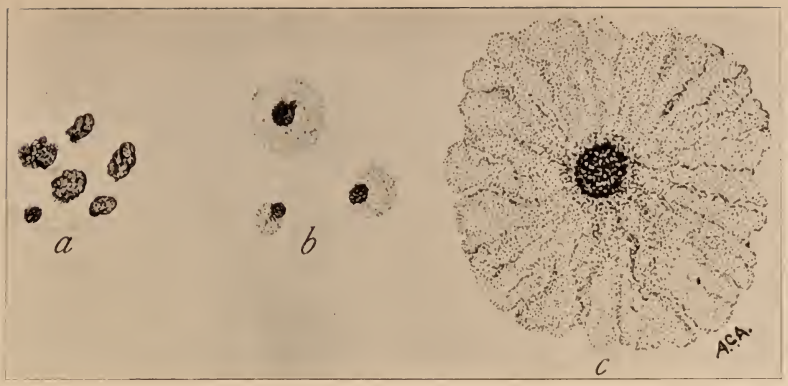


FIG. 1.—Colonies of *Bacillus diphtheriæ* on six-per-cent. glycerin agar-agar, in various stages of development (*a*, *b*, *c*).



FIG. 2.—*B. diphtheriæ* on Lœffler's *alkaline* blood-serum.

FIG. 3.—*B. diphtheriæ* on *acid* blood-serum mixture (Lœffler's).

FIG. 4.—*B. diphtheriæ* on six-per-cent. glycerin agar-agar.

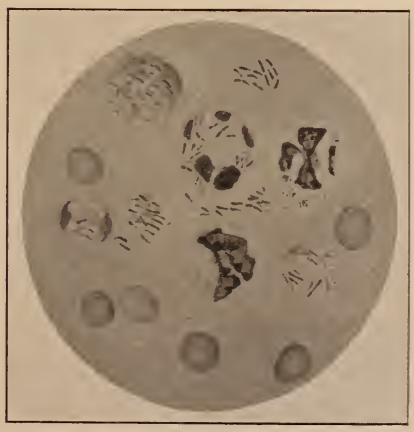

FIG. 5.—Microscopic appearance of a cover-slip preparation from site of inoculation of guinea-pig dead of experimental diphtheria.

FIG. 6.—Diagram showing necrotic area in spleen.

potato; it then appears as a very thin, dull, dry deposit at the point inoculated.

It grows with varying degree of luxuriance in the other media used in the laboratory, but those mentioned are the most important for its study under artificial conditions of cultivation. It does not possess the property of independent motion, nor is it one of the spore-bearing organisms.

It is destroyed by an exposure of ten minutes to a temperature of 58° C., but grows at temperatures ranging from 22° C. to 38° C., the development being most active at the latter point.

Of primary importance in the recognition of this organism is an acquaintance with its morphology under varying conditions of artificial environment.

It is impossible to say just what its normal pathology is, for one rarely encounters the organism when all the individuals are of uniform shape and size.

As obtained directly from the throat, the predominating form is perhaps that of a slender lancet or spindle. This changes more or less according to the medium on which it is cultivated. For example: On solidified blood-serum of alkaline reaction it appears in the form of comparatively long, irregularly staining threads that are sometimes clubbed at one or both ends, sometimes bulged out at or near the centre, and sometimes pointed at the extremities; often single bacilli will be found that appear as if broken at or near the middle. Many of these irregularly stained bacilli may present one or more points that take up the staining much more deeply than the balance of the cell, so that they look as if marked by black or very dark-blue round points.

In studying these morphological changes it must be remembered that the bacilli of greatest length and irregularity of staining are obtained from cultures on alkaline blood-serum that has been solidified (gelatinized) by the old method (Koch's), viz., fractional sterilization, and, finally, long-continued heating (from one to three hours) at 80° to 85° C. On blood-serum prepared by Councilman's method—that now commonly used—viz., rapid coagulation at high temperature with subsequent sterilization by steam—the morphology of the bacilli is shorter, while on coagulated egg-albumin (hard-boiled egg) the rods are still shorter.

If instead of blood-serum of alkaline reaction one employs a serum that has been very slightly acidified (not sufficiently to arrest growth), one encounters an alteration in the morphology of this organism that is both striking and peculiar. The cells here appear to be regularly swollen,

to be much shorter, oval cells predominate, and all stain in a remarkable way. Instead of the staining being taken up in the regular way seen in the culture on alkaline blood-serum, the bulk of the cells from the slightly acid serum are only very faintly tinged except at one point (usually). At this point, which may be at either end or at the centre, the staining is taken up very readily, so that the cell appears as a very faintly tinted oval body, in which is an intensely stained, small, round point. Very few conspicuously irregular forms will be found in cultures on the acid serum.

Another striking appearance of this organism is that obtained from glycerin-agar cultures (6 per cent. glycerin). Here the cells are smaller and much more regular in contour than on any of the other media. They are quite small, are lancet- or spindle-shaped, are sometimes clubbed, and stain tolerably regularly. They present throughout an appearance suggestive of their being composed of very short segments. Many of the stained cells contain deeply stained points.

On agar-agar without glycerin, on gelatin and in bouillon, the morphology is about intermediate between the extremes seen on alkaline blood-serum, on the one hand, and that on glycerin agar, on the other.

Long, irregularly staining, clubbed, and curved forms similar to those that are constantly seen upon Loeffler's blood-serum, even after only twenty-four hours at the temperature of the incubator, are often referred to collectively as involution or degenerate forms of this organism; but I feel justified in questioning the accuracy of this view; at all events, it is difficult to reconcile the voluminous growth of this organism, as seen upon blood-serum after twenty-four hours, with the opinion that the organisms of which it is composed are in a condition of degeneration. To what these variations are due it is impossible at this time to say. Experiments have been made with the view of shedding some light on the subject, but as yet the results are not satisfactory.[1]

The bacillus of diphtheria stains readily with all the basic aniline dyes. The stain most commonly used is the alkaline methylene-blue solution of Loeffler. It retains the stain when treated by the method of Gram. (Cultures and specimens illustrating these conditions of morphology and growth were exhibited.)

Of greatest importance in contributing to our knowledge of the relation of the *bacillus diphtheriæ* to diphtheria in man are the observations that have been made upon animals inoculated with cultures of this

[1] See paper by the author, "Inoculation of Milch Cows with Cultures of the Bacillus Diphtheriæ," Journal of Pathology and Bacteriology, Edinburgh and London, October, 1893.

organism. As a result of these studies we know that diphtheria is primarily a local trouble, and that the general symptoms and remote pathological lesions are the result, not of the presence of the diphtheria bacilli throughout the body, but rather of poisons that are produced, by the bacilli at the seat of local trouble in the throat, and which poisons, when disseminated through the circulating blood, possess the power of getting up a group of lesions in the internal organs now recognized as one of the characteristics of this malady.

If one inoculate a guinea-pig subcutaneously in the abdominal wall with a small portion of a pure culture of the virulent diphtheria bacillus, one finds that after twenty-four hours the animal is manifestly unwell. It will sit in the corner of its cage with the nose depressed, its back humped, the hair roughened up, and is disinclined to move. If laid on its side it may have difficulty in regaining its feet. If the hand be passed over the site of inoculation, tumefaction with œdema of the surrounding tissues is readily felt. At the end of thirty-six to forty-eight hours the animal is usually dead. The autopsy reveals an extensive œdema of the subcutaneous tissues, extending often from the pubes to the chin ; the subcutaneous lymphatic glands, in both inguinal and axillary regions, are enlarged and red. Immediately at the site of inoculation the skin is found to be bound down to the underlying tissues by a more or less dense, yellowish-gray patch of necrotic tissue that is everywhere marked with minute points of hemorrhage. It is from this necrotic mass, in the immediate neighborhood of the point at which the bacilli were deposited, that they may be recovered by culture methods, and that they may be found on microscopic examination. In the cover-slips made from the necrotic tissues at the site of inoculation one commonly finds numerous leucocytes, the nuclei of which are in various stages of disintegration and distortion, manifestly the direct effect of the poison that is being produced by the bacilli growing in the immediate neighborhood. Again, it is common to find at this point phagocytes containing diphtheria bacilli, many of which are advanced in degenerate changes.

At a distance of but two or three centimetres from this point one may fail to get the bacilli. They are not disseminated throughout the œdematous tissues, and are not usually found in the nearest lymphatic glands. The histological structure of the fibrino-purulent, necrotic tissues at the site of inoculation is essentially that of the diseased area in the throat of diphtheritic human beings.

On opening the great serous cavities it is common to find them (one or both) containing more or less of clear serum, sometimes but a cubic cen-

timetre or two; again, they may be almost filled. The small intestines may appear normal to the naked eye, or they may be œdematous and filled with clear or blood-stained fluid. Often their lymphatic apparatus is prominent and evidently affected. The liver may appear normal, or it may present minute, irregular, white markings, ranging in size from about that of a pin's point up to areas of 1 to 3 mm. in diameter. Similar areas may be seen to be scattered through the organ on section. The spleen may be normal, or may present areas similar to those seen on the liver The kidneys do not often present naked-eye changes, though at times pale points may be seen on them, too.

The adrenal bodies are practically always enlarged and markedly congested, and on section are found to be filled with a dark, blood-like mass. The retroperitoneal lymph-glands are enlarged and reddened. Very commonly groups of ecchymoses may be seen at different points on the peritoneum, especially that covering the abdominal wall just beneath the site of inoculation, and upon the diaphragm. The lungs are not commonly altered in appearance. The pericardial sac is often distended with clear fluid, and the tissues of the anterior mediastinum are usually œdematous.

The study of the internal organs and the blood of these animals by bacteriological methods does not, as a rule, reveal the presence of bacteria. By the use of larger amounts of material than are usually employed in making cultures one may succeed in detecting the bacilli in the internal organs. They are always few in number, however, and are most probably present as a result of being carried there by the blood-current from the site of inoculation. At all events, we have no evidence to justify the opinion that their appearance in the internal organs is of necessity followed by diseased conditions that can be attributed to their immediate presence.

The irregular pale areas referred to as appearing in the liver, spleen, and elsewhere, represent a very peculiar form of necrosis, to which Oertel[1] first called attention, in the cadavers of human beings after death from diphtheria, and which Welch and Flexner[2] have since detected in the bodies of animals dead of the experimental form of the disease. These changes consist of foci of a peculiar form of necrosis, varying in extent and scattered irregularly through the internal organs. They are charac-

[1] Oertel: "Die Pathogenese der epidemischen Diphtherie. Nach ihrer histologischen Begründung." Mit Atlas. Leipzig: Vogel, 1887.

[2] Welch and Flexner: "The Histological Changes in Experimental Diphtheria." Johns Hopkins Hospital Bulletin, No. 15, August, 1891. Also, "The Histological Lesions Produced by the Toxalbumin of Diphtheria." Ibid., No. 20, March, 1892.

terized by fragmentation of the nuclei of the cells of the parts affected. The fragments into which the nuclei are seen to disintegrate are conspicuous for the readiness and intensity with which they become stained and for the manifold shapes which they are seen to assume, at times appearing as little else than dust-like particles strewn through the necrotic and hyaline area, or again as clusters of granules indicative of the location of the nucleus from which they originated; again, all manner of irregular and bizarre shapes that may be likened to whetstones, crescents, balloons, clubs, dumb-bells, etc., will be seen. Frequently a nucleus will appear as if drawn out so that it may present a tail-like elongation, and again it may be pinched and distorted. In certain spots there may be almost an absence of stained cells and fragments, but it is usually possible to detect faint outlines of cells and more or less of a refractive, granular substance that gives the staining reaction of fibrin. In the investigations of Oertel and of Welch and Flexner these necrotic areas in greater or less extent have been detected in all the internal viscera, being particularly prominent in the lymphatic apparatus, in the liver, and in the spleen. To a limited extent the same process was also detected in the muscles of the heart. While not strictly confined to the disease, diphtheria, this nuclear fragmentation is nevertheless always an accompaniment, and affords, by the rapidity with which it is produced, another illustration of the energy of action possessed by the poison producing it. It has been seen to occur in the internal organs of animals with all its characteristics in so short a time as thirty-eight hours after inoculation with small quantities of cultures of the *bacillus diphtheriæ*.[1]

The poisons produced by the bacilli at the seat of primary invasion, to the absorption of which, as has been said, the secondary manifestations and constitutional symptoms are due, are likewise produced by the bacilli when growing under artificial conditions of cultivation.

When isolated, free from the organisms by which it was manufactured, it is seen to be capable of causing in susceptible animals identically the same group of tissue-changes that are produced when the bacilli themselves are introduced.

As bacteriological study of diphtheria and conditions with which it might be confused met with wider application, certain irregularities were encountered. It was discovered that the causative factor, the genuine *bacillus diphtheriæ*, was simulated in morphological and biological pecu-

[1] At this point autopsies were performed on guinea-pigs dead from diphtheria, and the naked-eye lesions demonstrated. Sections of tissues showing the foci of cell-death were also exhibited under the microscope.

liarities by what was believed to be another organism which was distinguishable from it only by the absence of pathogenic properties. This latter organism was known as the pseudo-diphtheritic bacillus, and was considered as distinct from the genuine diphtheritic bacillus simply because of its inability to kill susceptible animals when inoculated into them subcutaneously. As this organism had been seen in conditions not believed to be diphtheria, as it had been seen in mild cases of a doubtful nature, and as it had been seen in genuine diphtheria in association with the true diphtheria bacillus, it became necessary to determine its relation to the virulent *bacillus diphtheriæ* before the value of the latter organism as an absolute means of diagnosis could be firmly established. The simplest way out of the difficulty was to consider them as in no way related, but as entirely distinct species, and this, in fact, is what was done.

It was, however, soon observed that the genuine, virulent diphtheria bacillus was liable to fluctuate in the degree of its pathogenic properties, at times possessing these to such an extent that when inoculated into guinea-pigs death resulted in from thirty-six to forty-eight hours, while again, the period of incubation was much longer, often reaching five or six days, and in not a few cases organisms were obtained from undoubted cases of diphtheria that failed to give more than a temporary local reaction when inoculated into these animals. In many cases of diphtheria the two organisms have been seen to be simultaneously present, and in the observations of Roux and Yersin it was detected that as the disease advanced toward recovery the number of the less virulent and non-virulent forms became more numerous in proportion. Singular as it may seem, the only or principal point of distinction between these two organisms, if distinct they are, was held to be the ability of the one and the inability of the other to cause the death of the inoculated animals, and no attention whatever was paid to the nature of the local reaction that was caused by the organism that failed to kill. I have taken occasion to examine the condition of the tissues at the seat of inoculation in animals into which non-virulent forms of this organism had been introduced, and have found that, though the death of the animals did not follow the inoculations, locally, tissue-changes indistinguishable, save in degree, from those produced by the fully virulent forms were to be found; there was the same œdema, though less in extent, the same hyaline condition of the muscle-fibres, the same fibrin exudation, and the same characteristic fragmentation of nuclei that one finds locally in the animals inoculated with the true, fully virulent bacillus of diphtheria. This, I think, offers another argument in favor of the opinion already

expressed elsewhere by Roux and Yersin, myself, and others, that the diphtheritic bacillus and the so-called pseudo-diphtheritic bacillus are one and the same organism, the latter representing the former, whose virulent properties have become diminished.

In closing this demonstration I wish to apologize for the number of points in connection with this organism, and the conditions produced by it that have been either ignored or insufficiently dwelt upon; but as the time at my disposal is limited I must ask your indulgence, and hope that at some time in the future an opportunity may again present for me to ask your attention to an object-lesson upon this interesting topic.

---

## 14. *Preparation of the diphtheria antitoxin.*

Read by Dr. Joseph McFarland.

The beautiful demonstration by Ehrlich of the production of an antitoxic substance in the blood of animals gradually immunized to ricin was one of the foundation-stones upon which Behring and Roux have built up the new theory and practice of the treatment of diphtheria. Whatever exceptions may be taken to the antitoxic treatment as a method of alleviating the sufferings of our patients, it must be granted by all that it is one of the most scientific and interesting methods ever suggested, as well as the only one capable of positive demonstration upon animals with mathematically accurate results. However, I accepted the invitation to speak upon the antitoxin this evening with the direct understanding that its therapeutic merits were not to be discussed from the clinical or statistical aspects. I shall therefore devote myself to the laboratory experiments exclusively.

The theory of antitoxins as now generally accepted is that the body-cells of immune or partially immune animals are able, under proper stimulation, to produce a substance capable of annulling the effects of certain poisons. Sometimes, indeed generally, the stimulation of the cells depends upon the presence of the poisons to be neutralized. In the preparation of the antitoxins we make use of this fact, and accustom the animals to gradually increasing amounts of it, until the doses administered are so great that the immediate disorganization of nervous centres and necrosis of tissues all over the body would result, if the tissues were not able to produce a corresponding amount of a neutralizing sub-

stance. Ehrlich found this the case with ricin. As long as the amounts introduced were within a certain limit the animal simply endured them, but when the endurance was no longer able to cope with the increasing experimental dosage, the tissues began—and, as he found, suddenly began —to effect a neutralization. That which Ehrlich showed for ricin, Behring has shown to be true of the diphtheria toxin. Animals endure small doses, gradually accustom themselves to increasing doses, and neutralize the large ones.

The stimulation which produces antitoxin may also result from the presence in the tissues of the antitoxin itself. We can scarcely suppose that the one-hundredth cubic centimetre of antitoxin which we introduce into a poisoned guinea-pig, or the few cubic centimetres which we inject into a diseased child, can penetrate all the tissues and effect a universal neutralization of a circulating poison. Much more rational is the conclusion that the introduction of a given amount effects some neutralization *per se*, but that the great work is accomplished by a stimulation of the depressed, inactive body-cells.

One fact of prime importance is never to be forgotten when theorizing upon antitoxins—*the blood of immune animals does not normally contain a trace of it.* It has been suggested by many, and I have been asked again and again what effect the injection of 10 c.cm. of simple serum from the horse would have upon a case of diphtheria. *It would not have any effect.* The rat is a much more immune animal than the horse, and seems immune to any dose of diphtheria toxin, yet Kuprianow has shown that the blood-serum of the rat does not contain a particle of antitoxin and does not offer the slightest protection to guinea-pigs or mice when introduced into their bodies in considerable amounts.

Diphtheria is a disease whose pronounced symptoms are due to a violent toxæmia. The bacilli which cause it produce a local lesion where they multiply, but this is generally a mild inflammation in uncombined cases, dangerous only as a mechanical obstruction to the respiration, and is practically nothing in comparison to the results of the absorption of the toxins.

That the bacilli operate by toxins was first shown by Roux and Yersin, who found filtered cultures to be fatal to susceptible animals. It remained, however, for Behring to give us a correct estimate of the strength of the toxins. Behring's experiments upon this subject were made with toxins from a flask containing a very old bouillon culture of the *bacillus diphtheriæ.* The flask had been inoculated, and stood away in his incubator for two years before being tested. When opened it was perfectly sterile, the bacilli having long since died, but its alka-

linity was great and its toxic property of high virulence. Of this toxin he found that one-tenth cubic centimetre was fatal to a 500-gramme guinea-pig in about twenty-four hours. This flask furnished the material for many of Behring's experiments, although what is generally called his "standard toxin" is five-tenths cubic centimetre of a bouillon culture two days old.

The preparation of the toxin, according to Behring, was simple. Ordinary flasks of bouillon were inoculated, stood away in the incubator, and examined from time to time. As is well known, these flasks first are alkaline, but soon become acid as the bacillus develops. When the culture grows old and the bacilli cease to multiply, the alkalinity returns and marks the acme of toxin production. According to Behring, this takes about six, sometimes eight, weeks.

As the consumption of toxin in the preparation of antitoxin is great, a large amount must always be on hand, and a method which can provide it in a shorter time is desirable. Fernbach, observing an important fact in connection with the biology of toxic bacteria, has given us a new method of producing toxin which has met with excellent results in the hands of Roux. This method depends upon the exposure of a large surface of a liquid culture to a passing current of atmosphere. By this means the longevity of the bacilli is greatly diminished, their multiplication stimulated, and their disintegration accelerated, and a greatly-improved toxicity of the culture results, for, as the bacilli produce the toxin and liberate it when disintegration occurs, the increase in number and accelerated destruction greatly favor its production.

For the prosecution of this method a special flask—rather, a number of special flasks have been devised. I am not sure that I have seen the original Fernbach flask, that which I employ being a form of it, the pattern of which I secured from Dr. J. J. Kinyoun, of the United States Marine Hospital Service. After sterilization and inoculation the cotton stoppers which have closed the neck and tubulature are burned, then pushed down into a bulbous expansion below, and a sterile, perforated cork with a glass tube introduced above each. Rubber tubes are connected with the glass tubes in the corks; that in the tubulature being attached to a suction-pump; that in the neck with a wash-bottle, so that when the pump is started a stream of fresh, moist air passes through the flask from neck to tubulature, and constantly aerates the culture. (See Fig. 1.)

The New York Board of Health has a modification of Fernbach's flask, which I use, but which I do not like nearly as well as the one shown in the illustration.

The chief difficulty in the use of all flasks with passing air-currents is the danger of contamination. In that first described the danger is in part removed by cotton plugs which act as filters, but, as everyone knows, the spores of moulds will occasionally work unexpected havoc in cotton, so that now and then one unexpectedly finds his flask contaminated. At first I lost a number from moulds and the hay and potato bacilli, but now every precaution is taken ; the flask is sterilized preferably with its cotton stopper protected by a little hood of cotton, which

Fig. 1.

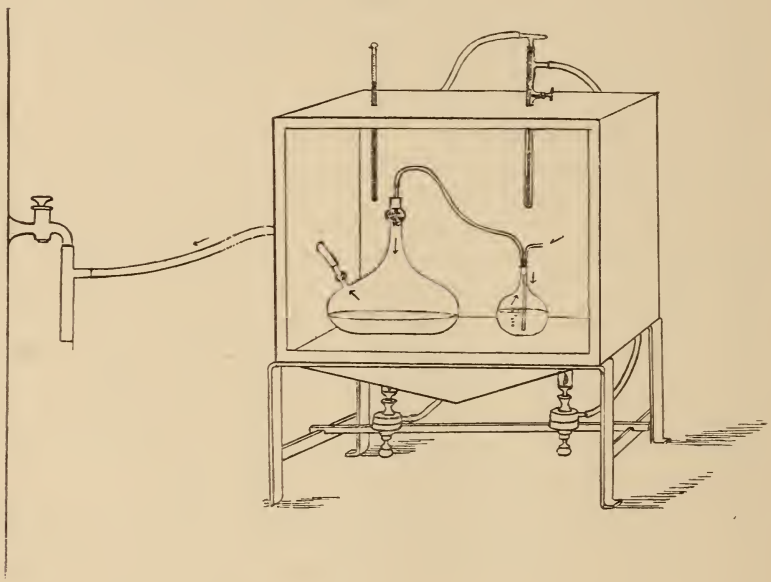

Incubator containing a culture of the diphtheria bacillus in the modified Fernbach flask, as shown to the writer by Kinyoun.

is only removed for filling and for inoculation. The rubber tubes are sterilized with carbolic acid, connected with the glass tubes and corks, and then boiled. When connected, a sterile cotton plug should be kept in the open tube of the wash-bottle, a sufficient amount of bichloride solution is added to the water in the wash-bottle to prevent moulds from growing in it, and I prefer to introduce a sterile flask between the pump and the large flask, so that any accidental regurgitation or the downward flow of any water of condensation from the tube may cause no danger.

The cultures in these flasks are grown in a strongly alkaline bouillon,

and must be *virulent* cultures. There can be no more important principle laid down than that it requires a *highly virulent* culture to produce a powerful toxin. The culture chosen should be one of which one-half centimetre of a bouillon culture two days old will kill a standard guinea-pig (500 grammes) in from twenty-four to thirty hours.

While the bacilli grow and produce toxin, the flasks are kept in an incubator at the temperature of 37° C., and the current of air allowed to pass through. The production of toxin requires about three weeks.

The cultures grown in such flasks are much more massive than one ordinarily sees, and a rather thick mycoderm often forms. This mycoderm is not perfect but ragged, fragments hanging from it and often dropping off. If the flask be moved, the growth on the surface, being very brittle, at once breaks up into small fragments which soon sink. I think observation will bear me out in the assertion that the greater the amount of surface growths, the greater the toxicity of the culture.

I make it a point to test every flask for purity (microscopically) before preparing the toxin for use. If the flask be pure, the exact quantity of culture which it contains is measured, and either $\frac{5}{10}$ per cent. of phenol or $\frac{4}{10}$ per cent. of trikresol added to kill the bacilli and insure the material from contamination. I have found trikresol preferable to phenol.

The toxin thus prepared is ready for use, and is the same as that employed in the experiments of Ehrlich, Behring, Wassermann, Kossel, Boer, and Aronson.

I have used toxin in this condition upon a number of horses, but in two cases have noted that which Kinyoun points out, that the dead bodies of the bacilli possess irritating properties, and sometimes set up a local inflammation terminating in suppuration. Lesions of this kind, with distinct abscess-formation, occurred after each injection in one horse. The discharged pus was sterile.

This local irritation can, as Behring has pointed out, be overcome by the addition to the toxin of trichloride of iodine, or, as Roux prefers, of Gram's solution, but the best means of avoiding it is to filter the toxin through a porcelain filter before employing it. The filtration should not be done too long before using the toxin, as it is said to deteriorate more rapidly afterward than before. (See Fig. 2.)

Toxin prepared as described should be of sufficient strength of one-tenth cubic centimetre to kill a 500-gramme guinea-pig in twenty-four hours (Roux). Very few observers seem to have secured exactly this strength, and I must confess that the best I have done is to secure it sufficiently strong for one-tenth cubic centimetre to kill in thirty hours.

There seems to be a rather exaggerated idea of the value of air-currents in connection with toxin production. I have succeeded in producing a toxin as strong as that mentioned above in a one-hundred cubic centimetre Erlenmeyer flask under most ordinary conditions. Ohlmacher sees no difference in the toxins from ordinary and special flasks, and, though I believe they have not mentioned it in print, Professor Prudden and Dr. Abbott have both informed me that in their opinion special flasks were of no very particular value. However, I have had fewer failures with the modified Fernbach than with the ordinary Erlenmeyer flasks, and continue to use them.

Fig. 2.

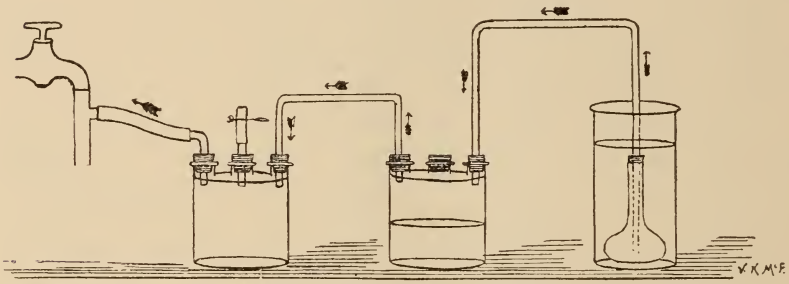

Author's method of filtering the toxin.

The antitoxin is produced by the increasing injection of this toxin into a partially immune animal, as has been described. The animal ordinarily employed is the horse—not because the horse will furnish either the strongest antitoxin or because the horse is most easily handled, but because, while it will produce good antitoxin and do it rather easily, it will also furnish an enormous amount of the serum. Behring in his experiments used a great variety of animals. Aronson used the goat. Roux introduced the horse. The first animal upon which I experimented was a goat, furnished through the liberality of Professor John Guitéras, to whom my sincere thanks are due for much personal kindness in the pursuit of my antitoxic studies.

The horses which we buy are strong horses of middle age with some unsoundness which disables them from active physical service. We never employ any with an organic disease. Each one is tested by Dr. Pearson for tuberculosis and glanders, and so far we have been fortunate in having had but one to react to mallein. This horse was, of course, rejected.

The general *regimen* of the animals is well cared for; they are well

fed, are cleanly kept, the temperature and pulse are taken several times daily, and they are weighed once a week. Every day those whose conditions permit are taken out for exercise.

The injections begin with 1 c.cm. of strong toxin, and the greatest variation in susceptibility soon manifests itself as the doses increase. The treatment of a horse of marked susceptibility requires care, judgment, and avoidance of haste. Immune horses may be immunized rapidly, dose after dose being given before slight indisposition to eat or fever shows a slight effect from the toxin.

The injections are made in two ways, varying according to the size of the dose of toxin to be given.

In the beginning, the dose being small, a burette with a fine rubber tube, connecting with a needle below and an atomizer-bulb above, is used. With the gentle elastic pressure of this bulb a very exact estimation of the force exerted can be made, and the exact quantity can easily be given.

The injections are generally made in the subcutaneous tissue of the neck, though any other point where the skin is loose will answer as well. The large amounts are allowed to flow in slowly by gravitation. I think that the care with which the injections are given bears a distinct relation to the severity of the after-effects. My horses show much less swelling than others that I have seen.

A general outline of the injections for an average horse would be as follows:

| Week. | Cubic centimetres. | Week. | Cubic centimetres. |
|---|---|---|---|
| First | 1 | Seventh | 100 |
| Second | 2 | Eighth | 150 |
| Third | 5 | Ninth | 200 |
| Fourth | 10 | Tenth | 250 |
| Fifth | 25 | Eleventh | 250 |
| Sixth | 50 | Twelfth | 300 |

After receiving the 300 c.cm. of strong toxin the blood generally contains considerable useful antitoxin.

The immediate effect of the injections as observed in my animals is only of importance in susceptible animals or after large doses. Under these circumstances the temperature begins to rise, ascending from the normal (about 101° F.) to 103° to 105° F. The pulse is slightly accelerated, the animal develops œdema at the point of inoculation, and shrinks from the pressure of the finger. The swollen area is hot. The appetite diminishes, so that only one-half or one-quarter of the next meal is eaten. After this the animal appears better, and by the second

or third day the symptoms ameliorate, the swelling rapidly diminishes, and the animal seems as well as ever.

Kinyoun points out the interesting fact that when the horse is receiving 100 to 200 c.c. of toxin one would naturally expect to find some antitoxin in the blood, but on testing is surprised to find it absent. It seems only to develop after the large doses, which is exactly what we would expect from what Ehrlich has taught us about ricin.

About four days after the horse receives his final well-borne dose 300 c.c. of toxin a slight incision is made into the skin over a compressed jugular vein, and a trocar plunged in. As the trocar is withdrawn a canula-plug, attached to a rubber tube, is introduced, and the blood, to the amount of six or seven litres, withdrawn into sterile bottles. Roux uses ordinary wide-mouth bottles, the tops of which are covered with paper, and protected by paper caps before sterilization. When one is to be used its cap is removed, and a glass tube in the end of the rubber tube plunged through the paper, so that the interior of the bottle is never exposed. When full, the tube is withdrawn and the cap replaced. I have used this method and greatly prefer it to anything else that I have tried.

The blood is stood away in a refrigerator as soon as coagulation occurs, and the serum may be pipetted off on a number of subsequent days. When the trocar is withdrawn from the neck of the horse the wound is closed by a pin suture, and always heals kindly in a short time.

The serum, as pipetted off, is slightly clouded, and is best stood aside for awhile longer, with a piece of camphor floating upon it, in tall glass cylinders of about 300 c.c. capacity. The corpuscles then precipitate and the clearness is improved.

There are a variety of methods of preserving the antitoxic serum. Roux prefers a piece of camphor, Behring phenol (0.5 per cent.). I prefer $\frac{4}{10}$ per cent. of trikresol.

The estimation of the protective value of the antitoxin serum is of great importance. Unfortunately it consumes much time and a considerable number of guinea-pigs.

There is an absolute standard of strength, and the serums made by Behring, Aronson, and Roux all differ considerably. Roux does not give the strength of his, but states as the dose a considerable quantity, so that compared, for example, to Aronson's, it is comparatively weak. Behring furnishes three varieties: No. 1, week, useful for immunization; No. 2, strong, useful for treatment; and No. 3, very strong, but not very highly recommended.

Behring gives an exact measurement of his serum, which is not only

useful but exemplary, for without it an exact estimation of the dosage is impossible.

The unit of strength given by Behring is what he terms the "immunity unit." It is an amount of antitoxic serum required to protect a standard guinea-pig (500 grammes) against ten times the minimum fatal dose of diphtheria toxin. Thus, if by experiment it is proved that one-hundredth cubic centimetre of the antitoxic serum when mixed with the one-tenth cubic centimetre of toxin, which constitutes the ordinary fatal dose, and injected into a healthy guinea-pig of 500 grammes weight, will cause the animal to recover from the effects of the poison, it is obvious that one cubic centimetre of the antitoxic serum contains one hundred immunity units, and would save one hundred guinea-pigs, that ten cubic centimetres would contain one thousand immunity units, and would save one thousand guinea-pigs, and so on.

The advantage of this system of denomination is that the estimation of the dose is simple. The standard guinea-pig weighs one pound. If the serum have a strength of one hundred immunity units per cubic centimetre, one cubic centimetre of it should protect one hundred pounds of animal, and will do so if the animal to be protected be a guinea-pig. Unfortunately, animals vary greatly in susceptibility to diphtheria, and experimentation has shown that guinea-pigs are ten times as susceptible as men, both to the toxin and to the antitoxin, and that, in proportion to the body-weight, ten times as much must be given a member of the human species as would be given to a guinea-pig.

It will be of interest to observe the charts of some of the animals which have been subjected to the toxin injections:

I. This was a large goat, subjected to injections of Behring's toxin. The animal was covered with long hair, and atrophied very much before the condition was detected. The temperature reaction was very great after each injection, showing that the dose was out of all proportion. The animal suddenly died in the ninth week of treatment—not without cause.

II. This was one of the horses to which I referred as showing suppuration after the injection of unfiltered cultures. The animal was remarkably susceptible, and died, after five cubic centimetres of phenolized culture, with all the signs of profound toxæmia observed ordinarily in guinea-pigs.

III. Another susceptible horse which seemed to be doing well, though the temperature reactions were marked. One day he abruptly fell dead from heart-failure. The autopsy showed an advanced fatty degeneration of the heart-muscle and a peculiar hemorrhagic infarction of the kidney.

CHART I.

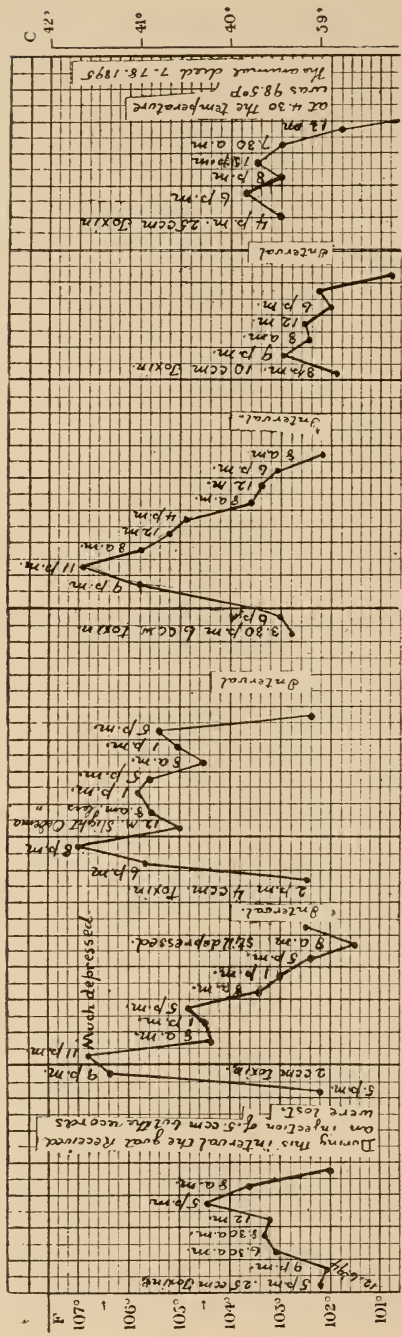
F
C
101°
102°
103°
104°
105°
106°
107°
39°
40°
41°
42°
Goat.
Interval
Much depressed
Interval
Interval

CHART II.

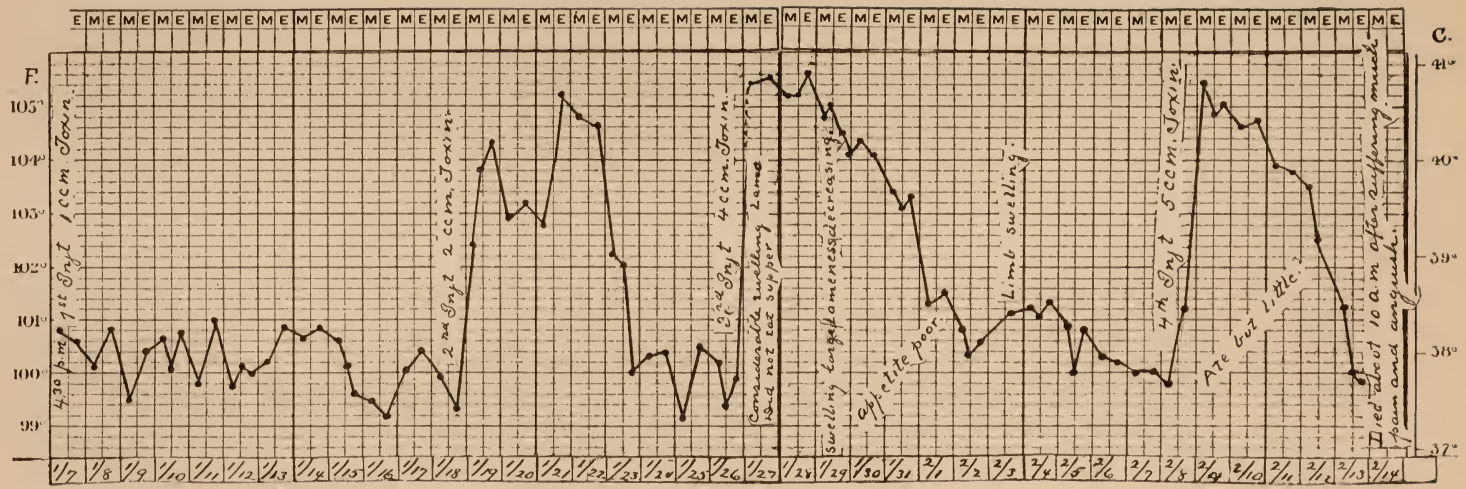


Horse.

IV. This chart is from a horse now producing strong antitoxin.

My experience seems to show that light-colored horses are more susceptible to the action of diphtheria poison than those of dark color.

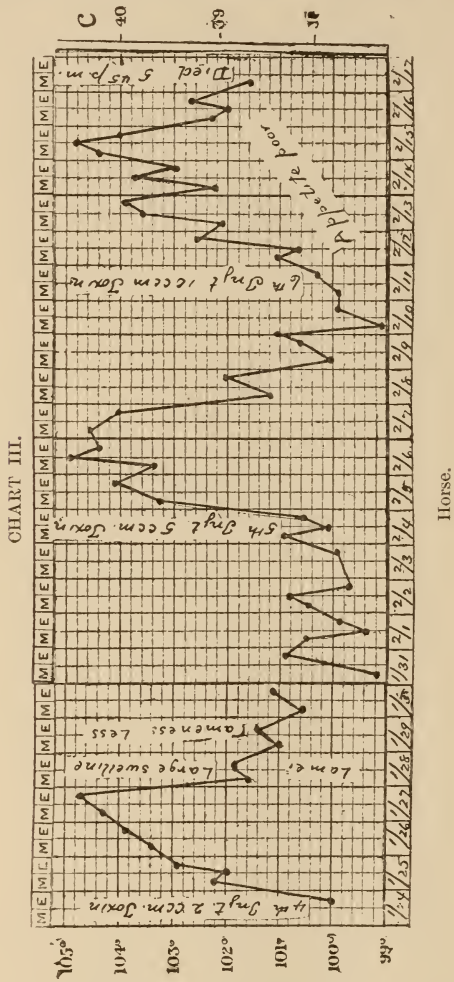


The temperature, pulse, respiration, appetite, body-weight, amount of local reaction, and general behavior of the animal must all be very carefully considered before opinion can be expressed as to the tolerance shown to the injections. Sometimes an animal seems in perfect health, but the careful estimation of its weight will show a steady decline into an incurable cachexia.

CHART IV.

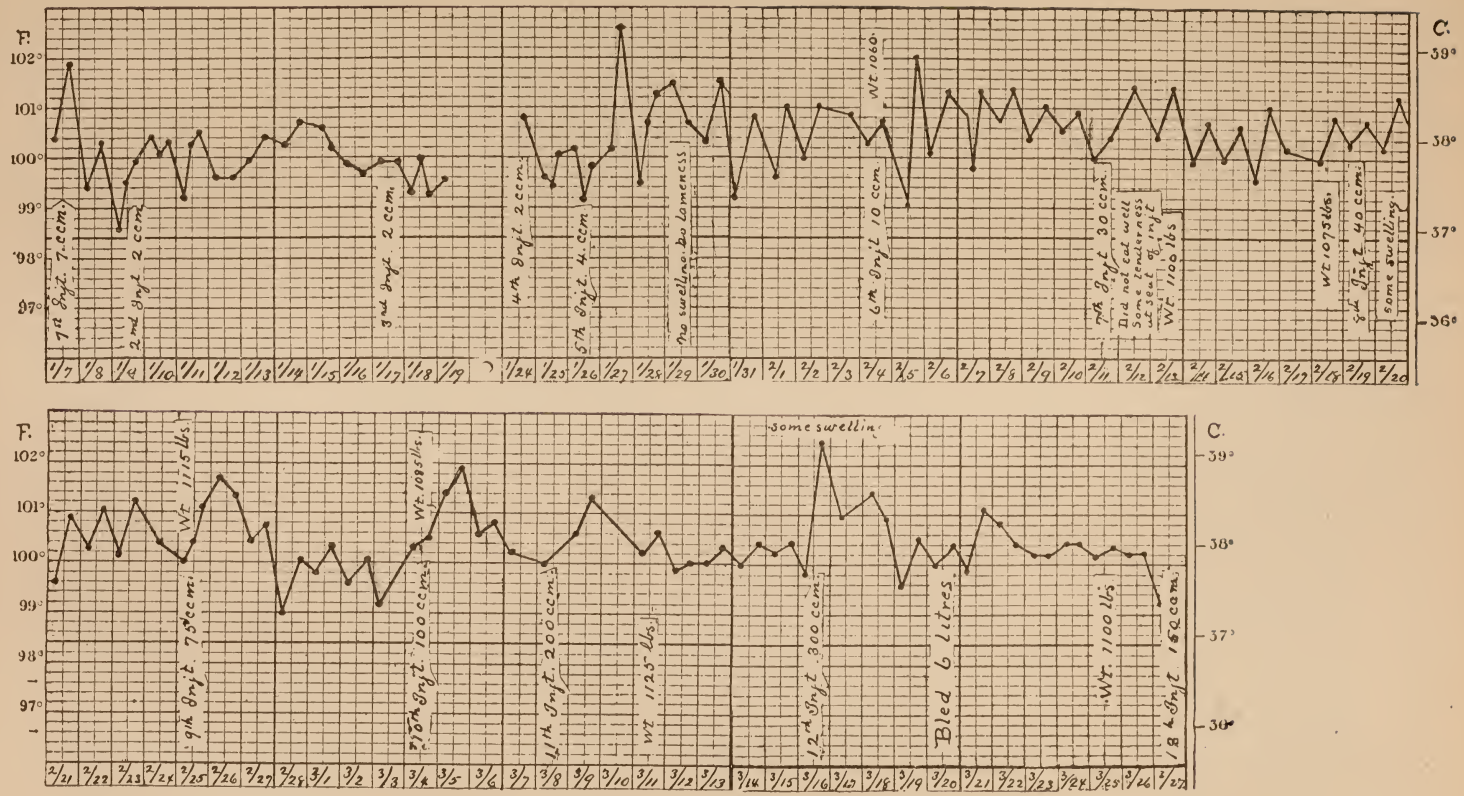


Bay gelding.

Careful autopsies have been performed upon all of my animals which died, but it is still too soon to attempt to describe the results of microscopical examinations of the tissues.

In all I have had sixteen animals—one goat, which died, and fifteen horses, of whom three died and one was rejected because of the reaction to mallein.

---

## 15. *The respiratory system.*

Read by Dr. J. P. Crozer Griffith.

Whether diphtheria is primarily a general systemic disease with local manifestation, or whether it is a local process with a secondary toxic systemic infection, is a question which has been much disputed and not even yet settled. Analogy to other infectious processes would certainly indicate that the former view is correct. So also the cases which have been reported during epidemics of the disease, in which the general symptoms were present yet without any local manifestations, tend to uphold this opinion. On the other hand, the second view is supported, among many other reasons, by the fact that sore-throats of different sorts are so prone to be attended by decided constitutional impression and by the fact that, as in pneumonia, more than one microbe appears to be able to produce a pseudo-membrane in the throat, with swelling of the glands and prostration. Which of the views is correct we cannot pretend to determine.

The pharynx is not, properly speaking, a part of the respiratory apparatus. At the same time it clearly falls to me to discuss the pathology of the disease as related to this part of the body, as well as to the respiratory apparatus, since it has been assigned to no one else. The gross appearances of the diphtheritic exudate in the pharynx are by no means entirely characteristic. If we examine the throat early in a case of diphtheria we may find a small amount of gray-white or yellow-white deposit upon one or both tonsils. To pronounce this to be diphtheria is by no means a safe thing to do, apart from the bacteriological examination of the membrane. In the first place, it may resemble closely the appearance of follicular tonsillitis. It is perfectly possible, as bacteriological studies have shown, for a diphtheria to start in the tonsillar crypts and to confine itself to them, never extending to other parts of the throat. Cases occur frequently which carry conviction regarding the truth of this statement, even though no bacteriologic study be made to

confirm it. I have more than once seen house epidemics of diphtheria in which certain cases, undoubtedly diphtheritic from the association with graver cases and from the existence of constitutional symptoms, exhibited only one or two follicles filled with the white secretion. These cases would certainly have been pronounced lacunar tonsillitis if seen alone. Such an experience as this is of every-day occurrence. Then, again, it is possible for the deposit of lacunar tonsillitis to spread beyond the follicles and to produce a membrane by the fusion of the secretion from different follicles. As a rule, however, the appearance in such cases differs from that in diphtheria. In the latter disease the membrane is rather tougher, and adheres more firmly to the mucous membrane of the pharynx and tonsils, so that efforts at its removal are apt to cause blood to appear. The false membrane is, in fact, not *on* the mucous membrane, but *in* it, *i. e.*, the natural lining of the throat becomes necrotic and forms a part of the so-called deposit. As time goes on the membrane of diphtheria shows its real nature by its tendency to spread to other parts of the throat, especially the uvula and the pillars of the pharynx. This is, perhaps, one of the safest clinical tests for the recognition of diphtheria as distinguished from tonsillitis, although the absence of this spreading is, as stated, not positive proof that the disease is not diphtheria. Apart from lacunar tonsillitis, there are other conditions which simulate diphtheria very closely.

In the eruptive fevers, and especially in scarlet fever, we may have a pseudo-membrane produced which is entirely indistinguishable from that in diphtheria. It not only appears like it, but, like it, need not limit itself to the tonsils. There is, in fact, no gross or fine pathological character, apart from its bacteriological nature, which serves to distinguish it. So, too, false membrane may be produced by corrosive substances. There are also various forms of pharyngitis, called ulcerous, pultaceous, aphthous, herpetic, etc., in which a form of pseudo-membrane develops, and which may in some instances be confounded with diphtheria. In some there are one or more small, shallow ulcers, with a thin, grayish membrane covering them, but the thick and extensive membrane of diphtheria is absent. In others there is a soft pultaceous substance in the pharynx, which can be removed easily without injury to the mucous membrane beneath. I have seen some cases, however, in which the diagnosis was extremely difficult or impossible. In fact, there seems to be a large number of cases in which a pseudo-membrane forms which cannot be distinguished from that of true diphtheria, and which may exhibit the same tendency to spread. In most of these cases the deposit is clearly of microbic origin, although some coccus, and not the Klebs-Loeffler bacillus,

is the active agent. The condition is variously described as pseudo-diphtheria, diphtheroid, streptococcus, diphtheria, etc. Like true diphtheria, it is capable of extending to the larynx.

The appearance of the pseudo-membrane in thoroughly well-developed cases of diphtheria is well known. It is usually very extensive, and covers the tonsils, the pillars of the pharynx, uvula, posterior pharynx wall, and epiglottis, and may extend to the lining of the cheeks and even to the skin outside of the mouth. Involvement of the nose is of very common occurrence. The exudate is at first grayish-white, but as it grows thicker it becomes darker or more yellowish and opaque. After four or five or more days in favorable cases it begins to disappear, sometimes slowly melting away and sometimes being cast off in distinct pieces. The length of time during which traces of the membrane may remain seems to bear no direct ratio to the amount originally present. I have seen small grayish patches persist almost unchanged for days during convalescence in cases in which the symptoms had been very slight and there had been but little membrane, while in other very grave cases with extensive membrane the rapidity of clearing up was sometimes remarkable.

In severe cases the membrane, instead of disappearing, shows a constant tendency to spread, both in superficial extent and depth. Sometimes extensive necrosis takes place. A vessel may be eroded or, as in a recent case under my observation, subcutaneous emphysema of the neck and upper part of the thorax may occur.

One of the most common and dangerous methods of extension is to the larynx. It is, however, not especially in the cases of very extensive pharyngeal involvement that the laryngeal complication is most apt to take place. Just as frequently there may be very little to be seen in the pharynx during the course of the attack. In one case, for instance, which I saw some time ago, membrane was seen upon the tonsil on the first day of observation, but this had disappeared by the next day, although marked laryngeal symptoms had developed which rendered tracheotomy necessary a short time later. There is reason to believe that such an occurrence as this is very frequent.

In this connection we pause a moment to consider briefly the pathology of diphtheritic laryngitis and its relation to the so-called group. The case to which I have just referred illustrates how easily mistakes may and do occur. Such a case might very readily have been considered one of primary laryngeal diphtheria except for the observation made at the first visit. It frequently happens that at autopsies of cases which seemed to have been purely laryngeal, and in which no membrane elsewhere could be detected at any time, some membrane is found in situa-

tions in the pharynx which were invisible during life. Primary laryngeal diphtheria is certainly comparatively uncommon. The use of the term "croup," as indicating a pseudo-membranous laryngitis which is not diphtheritic in nature, is most misleading and erroneous. While it is probably perfectly possible that a pseudo-membranous laryngitis may develop which is purely inflammatory in nature, not dependent upon microbic action, such an occurrence is certainly, in my opinion, of great rarity. There are no characteristic symptoms which would indicate that this had occurred, and which would serve to distinguish such an affection from a laryngeal diphtheria. In a recent case dying in the Children's Hospital of this city, with the symptoms of croup as described in earlier text-books, a pseudo-membrane, limited to the larynx, was found, but later study showed this to contain the Klebs-Loeffler bacillus. Certainly the great majority of cases of laryngitis of this sort are true diphtheria. At the same time it has been proved of late years that many cases of laryngeal membrane, although microbic, do not exhibit the diphtheritic bacillus. This is true, for instance, of the cases of streptococcus diphtheria whether the process spreads from the pharynx to the larynx or was primary in the latter locality.

The pseudo-membrane of diphtheria may spread downward below the larynx even into the lungs. In both larynx and trachea it is not as firmly attached as in the pharynx, and may be more easily stripped off.

The severity of the symptoms of laryngeal stenosis does not necessarily depend upon the amount of membrane present in the larynx. As a rule, the deposit on the cords is thin. I have repeatedly been struck by the fact that the condition of the larynx, as seen at the autopsy, did not seem to account for the death from laryngeal stenosis, very little membrane being visible.

Having run over briefly, as the time requires, some of the gross pathological characteristics of the lesions of the pharynx and larynx in diphtheria and their bearing upon symptoms and diagnosis, I must consider for a moment the histological changes to be found. There is, at first, hyperæmia of the mucous membrane, followed in a very short time by the production of pseudo-membrane. This latter consists of epithelial cells which have been killed by the action of the poison, and have then undergone hyaline transformation. Leucocytes pass through the blood-vessel walls under the influence of the inflammation, and then they too die and undergo the same hyaline transformation. The pseudo-membrane is thus made up of dead, altered cells, with, of course, numerous bacteria, chiefly the diphtheria bacillus. On the surface of the pseudo-membrane these bacilli are associated with other micro-organisms, espe-

cially cocci, while in the deeper parts there are few microbes of any kind.

There remains still to consider the condition of the lungs in diphtheria. Involvement of these organs is quite a frequent complication. At the autopsy we may find the membrane extending into the small bronchi. There are often atelectatic areas, œdema, bronchitis, and, especially, broncho-pneumonia. The latter is most apt to develop in the first week of the diphtheritic process. It is in many cases simply an extension of this process from the trachea; in others it may be of a septic nature. Various micro-organisms, including the diphtheria bacillus, have been found in the pneumonic lungs. Whether tracheotomy increases the liability to the development of pneumonia is a disputed point.

---

## 16. *Glandular and circulatory systems.*

Read by Dr. W. E. Hughes.

In considering the circulatory and glandular systems, the part of this discussion which has been assigned to me, I have thought that it will be more valuable if my remarks be based rather upon the clinical than upon purely pathological questions. Of these two systems the circulatory is much the most important clinically, seeing that many of the deaths in diphtheria are directly due to cardiac causes. Too much stress cannot be laid upon this. Death may take place through heart-failure in one of two ways—either the nervous supply of the heart is seriously interfered with, or there has been a profound degeneration of the muscular fibres. Often, doubtless, when neither one of these causes alone would be serious, their combination would be fatal. It is always to be clearly borne in mind that the effects of diphtheria on either the circulatory or the glandular apparatus are due, not to the bacilli themselves, but to their toxin, and, more, that in many—nay, most—cases of diphtheria there are associated with the pathogenic bacillus various cocci, which have themselves deleterious effects, and in many ways modify the effects of the bacillus. Sudden death in diphtheria may occur at any time after the disease has reached its height. When it is due to nerve-involvement it will be, as a rule, late, generally after convalescence has been well established. The heart-muscle here may, on examination, be found to be practically normal, nor is it necessary that there have been any distinct signs during life, previous to the sudden fatal ending, of

cardiac weakness. As a rule, however, suspicions may be aroused by causeless palpitation or irregularity of the pulse. It is scarcely necessary to point out here that the apparent virulence of the diphtheria has little to do with its ultimate toxic effects. Probably, through individual susceptibility, the mildest cases may have the most unfortunate terminations.

The commoner form of sudden death is brought about by degeneration of the heart-muscle. In all specific fever there is a certain amount of toxic muscular degeneration, but in no other is this so prominent as in the one under consideration. This degeneration begins with establishment of prominent systemic symptoms, and reaches its acme about the time of the beginning of convalescence. Deaths, then, are to be looked for comparatively early. Macroscopically, such a heart has its cavities dilated, its walls flabby and of a dead-leaf color, as in a case which I had the honor of presenting to this Society a few meetings back, when death had occurred within a week of the onset of diphtheria. Microscopically, the change has been well enough studied to make us believe that there is nothing peculiar in the degeneration. Individual fibres are attacked with varying intensity at different points, the process going on even to a coagulation necrosis. Clinically such a heart will present the usual signs of acute dilatation, especially on the right side. There will be altered areas of dulness, altered sounds and force, and the sphygmograph will now show characteristic failing heart-power, together with loss of elasticity in the arterial walls.

Endocarditis and pericarditis are probably never found associated with pure diphtheria. When they do occur their exciting cause is some of the various associated cocci.

Outside of the heart the vascular apparatus generally is affected. A widespread degeneration of the arteries, and even more of the capillaries, is found. This leads to a symptom very frequently associated with diphtheria—hemorrhage; and this may be a cause of sudden death through bursting of a vessel at a vital point.

The glandular system shows early and marked effects of the toxin. The first to be involved are the lymph-glands, and primarily those nearest the seat of local infection. The microscopic lesion here is an accumulation of lymph-cells, probably an example of phagocytosis, and to be associated with the leucocytosis so constantly occurring in diphtheria. When there is necrosis of the lymph-glands the cause is a coccus, and not the pathogenic bacillus. The salivary glands, and even the glands along the gastro-intestinal tract, show a degeneration of their epithelium, but not to a degree capable of producing prominent symptoms.

Though almost all pronounced cases have a certain amount of albuminuria, yet this is, as a rule, significant of no pronounced renal lesion, but due merely to the trifling degeneration of kidney epithelium common to all the specific fevers. In exceptional cases the lesion has progressed further, the epithelium is extensively involved, possibly even to the point of coagulation necrosis. The lesion is practically the same as that produced by Dr. Carter and myself in our experiments with uræmic serum, and is unquestionably the direct result of the local action of the toxin. Rarely is there degeneration of the Malpighian tufts, and never to the extent seen in the glomerulo-nephritis of scarlet fever. When the tufts are so involved it is probably the result of the general involvement of the circulatory apparatus rather than of any local process going on in the kidney. Clinically, the kidney involvement is of little importance unless it proves immediately fatal, as it will, as a rule, be recovered from and not lead to any chronic disease.

In the liver the effect is produced rather upon the interstitial tissue than upon the acinal cells. Though these cells are fatty, yet there is scarcely an actual degeneration. This condition of the liver suggests strongly the results of Dr. Flexner's experiments with abrine. It would suggest further that in diphtheria we may possibly find the starting-point of some cases of cirrhosis of this organ.

---

## 17. *The nose, ear, and eye.*

Read by Dr. B. A. Randall.

The occurrence of diphtheritic rhinitis is not among the frequent appearances of diphtheria; still less common are clearly defined clinical cases of the disease in the ear or eye. However, the number of cases is probably much greater than is commonly supposed, and further bacteriological investigation in this matter will make these cases more frequently recognized in the future. But it may be fairly stated that diphtheritic rhinitis, as a separate entity, is a condition that is exceedingly rare. No individual worker in the laboratory has gotten together more than a dozen *proved* cases as his contribution to the literature of the subject, and I know of no clinicians who have had more. Cases of croupous inflammation will come, as Dr. Griffith has said, to materially swell the number of those *suspected;* but bacteriological examination alone can settle the question. The cases that are clinically diphtheritic

rhinitis are decided rarities, and will probably so remain; yet the presence without any symptoms of the diphtheria bacillus in the nose, as in any part of the body, will probably be more and more frequently shown as examinations are more systematically made. The lesion in the nose is but slightly inclined to extend, and it is commonly confined largely or wholly to one side. Stenosis is generally more or less marked, and is due partly to swelling, as well as to the thick, pultaceous, and rather adherent membrane. The characteristic bleeding on detaching it may be found also in many cases of a strictly croupous condition, such as cauterization or a foreign body may give rise to.

Upon the conjunctiva the condition is one of rather extreme rarity, while the croupous formations here are very common, being found in almost every case of purulent inflammation, especially the gonorrhœal. But the rare cases where the diphtheria occurs strike the oculist almost immediately, and may be recognized long before he has made a close examination of the case. The puffing lids of the ordinary suppuration are almost lacking. The condition may seem one of anæmia, although the bleeding which often follows rough manipulation of the membrane or of the excoriations of the lids is commonly marked. With the nose, and particularly with the conjunctiva, the necrotic character of the process is a serious element. Even in non-diphtheritic cases the cornea is apt to suffer; and almost always it sloughs in cases of true diphtheria; yet the number of authentic observations is really rather too small for any sweeping conclusions. I have certainly seen two—perhaps three—cases among the ten thousand of my patients, and an equal number of those of others.

In inflammations of the external ear we frequently have false membrane, but it may or it may nor be diphtheritic. When there is diphtheria constantly present, and manifested locally elsewhere, we may yet find no trace of the bacillus in the false membrane of the ear. This generally forms on surfaces already excoriated, or at least inflamed, as in the nose. On the other hand, as in a case recently seen in my friend Dr. Cohen's practice, there may be no pseudo-membrane in the ear and only a little in the fauces, which showed absolutely no trace of diphtheritic bacilli in the cultures. But it was almost accidentally found that there was quite a virulent culture of the bacillus obtainable from ear discharge. Clinically, this may be wholly unimportant in the ear, the case going on to rapid and uneventful cure. Ordinarily, the attack of the disease upon the tympanum is accompanied by the streptococcus, and there is apt to be a very destructive process, destroying the drumhead and ossicles, attacking the labyrinth-wall, and penetrating, at times,

to the brain with fatal results. This brief statement presents these local aspects in about as full a way as I feel is necessary on this occasion.

---

## 18. *The nervous symptoms and lesions of diphtheria.*

Read by Dr. Charles W. Burr.

The time at our command is so limited, and the hour so late, that I will omit all references to authorities. To understand properly the mechanics of the nervous system of diphtheria—that is, what organs are affected and in what way—we must first consider the symptoms, for all nervous manifestations occurring in diphtheria are not necessarily diphtheritic.

The most common and most important symptom is paralysis of a peculiar and characteristic type. It is most apt to appear during convalescence, or, indeed, weeks after recovery from acute disease. It usually affects first, and often alone, the palate and the accommodative apparatus of the eye. The onset is slow and the march irregular, parts far distant from each other being attacked in succession. The knee-jerk is abolished (sometimes very early in the disease), even though there is no leg palsy, or even if there is no palsy at all. There is moderate wasting. The electrical reactions of the affected muscles vary greatly; often there is faradic diminution, much less frequently reaction of degeneration. The tendency is toward recovery.

The sudden hemiplegia which sometimes occurs is, properly speaking, not diphtheritic, but is due to the same causes which produce hemiplegia in other acute infectious fevers, viz., arterial rupture, embolism, or thrombosis.

Rarely there occurs a hemiplegia which, early in its course, mimics a peripheral palsy, and later shows all the signs of a cerebral origin. Thus, A. F., aged 5 years, came to the Infirmary for Nervous Diseases with the following history: He had diphtheria in May, 1890. During the acute stage there was palatal palsy, with nasal voice and difficulty in swallowing. Some time after, during convalescence, the left arm and leg rapidly grew weak, and finally became entirely paralyzed. On examination in July, 1890, he could swallow well; sat up with difficulty, the head falling forward on the chest and the back-muscles being very weak. At the same time there was absolute flaccid palsy of the left arm and leg, and partial palsy of the left face. There was general emaciation, but no distinct local atrophy. The knee-jerk was absent on both sides.

The plantar reflex was present. There was incontinence of urine and marked constipation. At the first examination there was faradic reduction, but at no time reaction of degeneration. When seen last, four years after the onset, the character of the hemiplegia had entirely changed. Instead of being flaccid, with absent knee-jerks, there was a spastic paralysis of the left side, with marked increase of the reflexes—a perfect picture of a cerebral palsy. Complex as this case appears at first sight, the explanation seems to me simple. I regard it as most probable that there was a true but slight general diphtheritic palsy; that later a vascular cerebral lesion occurred, the signs of which were for a time masked by the previous palsy, and that as the latter passed away the cerebral signs came to the front.

The extent to which diphtheritic paralysis may spread is well shown by the following case, also from the Infirmary: A. C., 22 years old, laborer; April, 1894, mild diphtheria. During the acute stage regurgitation of liquids through the nose. During convalescence, and after he had been out of bed some time, there appeared a gradually increasing weakness of the arms and legs, until finally he was bedridden and could not feed himself. There was never muscular nerve-pain, relaxation of the sphincters, nor anæsthesia. There was marked general emaciation. Faradic muscular reaction was somewhat reduced. The knee-jerks were abolished. When he recovered sufficiently to walk there was marked steppage-gait. After several months recovery was complete.

Much less attention has been paid to ataxia in diphtheria. Slight ataxia and choreiform and ataxiform movements are not uncommon in cases of palsy; but more than this, the ataxia may be the predominant symptom, as in the following case from my service at the Medico-Chirurgical Hospital: L. B., 5 years old, had diphtheria in October, 1894. No palatal palsy. During convalescence, and after he had been out of bed some days, his father noticed that he at times walked as if drunk. On examination his gait was markedly staggering. There was greater ataxia on movement of the hands. Station was very bad with eyes closed; with eyes open better, but still bad. The muscles supporting the head were paretic, so that it was held up with difficulty. There was no palsy of the arms or legs. The knee-jerk, the biceps-tendon jerk, and the chin-jerk were absent. The muscle-jerks in the forearms and the cremasteric jerks were present. The pupils were equal and reacted well to light, and with accommodation. Sensation was perfect. Complete recovery was established in four months. Beside the palsies noted above, there occurs sometimes a rapid paralysis of one cranial nerve, or, again, some time after the acute disease, a slow degeneration of a cranial nerve

may take place. Concerning the heart palsies, which are a so frequent cause of death, Dr. Hughes has spoken. The sensory symptoms are less patent than the paralytic and ataxic. There are often pharyngeal anæsthesia and curious patches of anæsthesia distributed in various parts—for example, the finger-tips. Pain and touch may both be involved, or touch alone.

Given the above data, the question before us is to discover the seat or seats of the nervous lesion and its nature. Many autopsies have been made and not infrequently have been fruitless. The earliest view held was that there was inflammation of the palatal nerves, which, ascending to the cord, produced disease in it which in turn caused all the symptoms. Advance in knowledge of the physiology of the nervous system has caused this theory—that is, that the cord is always at fault—to be abandoned. Reasoning backward from the symptoms, we should expect to find the seat of trouble in the peripheral nerve-trunks; and actually the most frequent lesion found has been a parenchymatous degeneration of the nerve-fibres. But why is there sometimes no lesion at all? We must accept the view that the primary cause of the symptoms is a poison or poisons produced during the life of the diphtheria bacillus. Now it is well known that toxic substances may cause alteration or abolition of function without visible lesion, and that when lesions are produced they are the products rather than the cause of the disturbance It is probable that in the future micro-chemistry will give us reactions that will make chemical changes in the composition of the nervous system visible. The very fact of the tendency of nervous diphtheritic troubles toward recovery makes it still more probable that usually there is no organic change.

A very remarkable fact in diphtheritic palsy is that in certain undoubted epidemics palsy has occurred without any evidence of a preceding diphtheria, which seems to prove that there is a distinct palsy-producing poison. Again, Martin has found an albumose in the blood which, injected into rabbits, causes palsy. The whole question, however, of what the poison is and how it acts falls rather within the domain of Dr. Abbott.

Finally, in some instances there is no nervous disturbance at all, but the palsy is due entirely to a degeneration of the muscles themselves.

*Special Meeting, March* 28, 1895.

## 19. *Trichomonas as a parasite of man.*

Read by Dr. George Dock, of Ann Arbor, Mich.

In 1836 Donné found a previously undescribed parasite in the vaginal secretions of women. These were described as roundish bodies about twice the size of pus-corpuscles and difficult to distinguish from the latter except by their independent motion. The motion was produced by certain organs, viz., a flagelliform appendage at the anterior end which worked with great rapidity, and a row of short cilia, at one side and near the flagellum, which kept up a sort of rotary motion. At the posterior end was a tail-like appendage of variable shape (Fig. 18). On account of the fact that the parasite resembled monads in having a flagellum, and "trichodines" (ciliata) in having cilia, Donné gave it the name trichomonas, with the specific name *vaginale* on account of the habitat. Although there were errors in Danné's description, it was remarkably good considering the methods of observation and the knowledge of micro-parasites then available. Certain details in the description will be mentioned later. Notwithstanding Donné's growing reputation as a microscopist, and the fact that his observations were controlled by such men as Dujardin, Milne-Edwards, Ricord, and others,[1] many microscopists (Vogel, Siebold, and Valentin) denied the parasitic nature of the bodies, and held them to be altered epithelial cells from the uterus. Later, however, Scanzoni and Kölliker,[2] Hennig,[3] Haussmann,[4] and Gasser[5] re-examined the organisms, mostly from the side of clinical microscopy. Still later Künstler[6] and Henneguy, in France,[7] and Blochman,[8] working under Bütschli, in Germany,[9] made investigations in the biology of the organisms, which, while differing in many respects, have added considerably to our knowledge. Within the last year Marchand[10] has examined the parasites, with results to be mentioned later.

On the whole, the parasites have been deemed of so little importance that scant notice is given them. The descriptions in most text-books on gynecology, microscopy, and pathology are inadequate or erroneous, and the same is true even of some recent works on animal parasites.

An extensive, but necessarily incomplete search of the American literature fails to reveal any reference to the occurrence of trichomonas vaginalis in this country. I have found it once only in the vaginal secretions of a pregnant woman in Galveston, Texas. Since my interest in the matter has been excited I looked for it, but without success. This may

be explained partly by the small number of persons examined, partly by the cleanliness of the subjects and the almost universal use of douches—the organisms being very senstitive to cold water.

Since the discovery of Donné, zoölogists have found parasites of the same kind, or closely related, in snails, frogs, ducks, etc.[11, 12, 13, 14] With the exception of Stein, however, none of these writers have influenced the study of the human parasite.

Flagellate organisms have been observed in stools since an early period. In many cases the organisms belonged to the kind first described by Davaine,[15] who found them in cholera and typhoid fever, and named by him cercomonas hominis. The efforts of some writers to deny the existence of these bodies, or to identify them with trichomonas, have not met with entire success. I[16] have encountered this same parasite in amœbic dysentery and typhoid fever and agree with Leuckart when he says that Davaine's observation, though one of the oldest, is still one of the best and most accurate. The same organisms have been found by Ekecrantz,[17] Tham,[18] Cunningham,[19] Grassi,[20] von Jaksch,[21] Müller,[22] Massiutin,[23] Kartulis,[24] Cahen,[25] Lutz,[26] Councilman and Lafleur,[27] Schuberg,[28] and others.* This parasite has to be considered at many points in studying trichomonas, as we shall see. We must leave it now to take up the history of some intestinal flagellates more closely related to the latter.

In 1875 Marchand[31] found large numbers of infusoria in the evacuations of a case of typhoid fever. He thought they might have been the same as those of Davaine and Lambl, but they had cilia, which the earlier observers did not mention, but had no flagellum as had Davaine's organism. The flagellum, however, Marchand thought might be extremely hard to see.

Soon after Zunker,[32] in the course of systematic examinations of stools, found parasites like those of Davaine in two cases and in seven others another form, which he thought similar to that found by Marchand. The description and the figures in this report differ from those of Marchand, and yet anyone familiar with such organisms would admit that it is possible. Both Marchand and Zunker found the same organism. Based on these two reports, the accuracy of which he doubted in some particulars, Leuckart erected the species trichomonas intestinalis, which has since been accepted by others.[33]

* The parasites found by Lambl[29] in the stools of children, and often spoken of as cercomonads, were really of a different genus, Megastoma or Lamblia. (Cf. Braun, 49. p. 111.) Lambl's cercomonas from the liver[30] cannot be definitely placed ; at all events it does not require further consideration now.

Grassi (*loc. cit.*) found parasites which he considered identical with cercomonas Davaine and trichomonas intestinalis Leuckart, and placed these together in a genus named by him monocercomonas. It is almost certain that some of Grassi's organisms belong to trichomonas intestinalis Leuckart, and differ considerably from cercomonas.

Under the novel name of cercomonas coli hominis, May[34] described an organism discovered in the stools of a patient with carcinoma of the stomach and chronic intestinal catarrh. This, also, from the description and figures (see Figure 23 of this article) appears to be a trichomonas, and Schuberg is, no doubt, right in saying that it is one. Why he gave it the name May does not say.

Roos[35] found flagellate parasites in the stools in a number of cases, and supposed they represented a number of distinct varieties, some being like those of Davaine, others like those of Marchand, others still like those of Zunker, and, again, after reading May's article, like the bodies described by that observer. This seems to have been caused by an indistinct knowledge of what the earlier observers had described. Some of Roos's figures represent typical trichomonads; his Figure 5, for example, is almost precisely like Miura's Figure 2 of the trichomonas found in the urethra, yet Roos calls this cercomonas Davaine. Altogether the *naïvetë* of the account is remarkable.

Epstein[36] has made extensive observations of flagellate protozoa found in the stools in twenty-six cases of infantile diarrhœa. Although Professor Hatchek determined these to belong to the genus monocercomonas Grassi, the full description and the figures in Epstein's excellent paper show certain differences as compared with those of Grassi. As the parasites seem common in Prague, we can, no doubt, expect further valuable results from their study in future. Some important clinical and pathological data of Epstein's will be mentioned later.

This short summary includes all the material available regarding flagella in the human intestines or their excretions. Diverse and contradictory as the original documents often are, a careful study of them makes it certain that some species of trichomonas, or, in other words, some organism closely related to the parasites so named by Donné, are parasites at times in the human intestine. A consideration of the possible effects of the organism must be postponed.

Organisms identical with some of those just mentioned (cercomonas mostly) have been found in the mouth (Steinberg, quoted by Leuckart, *loc. cit.*, p. 304); in abscess of the tonsil (Lenhartz[37]); in the nose (*ibid.*); in gangrene of the lung and in pleurisy (Kannenberg,[38,39] Streng,[40] Litten,[41] Lenhartz, *loc. cit.*; and Roos, *loc. cit.*). Important in connection with this

subject of flagellate parasitism, these reports are not of a kind to detain us longer at this time.

Observations on flagellates in the urine or bladder are few, but of great interest, and permit a critical examination much more readily than those relating to the intestines.

The first observation on flagellates in the urine is usually said to be that of A. Hill Hassall.[42]* An examination of Hassall's paper, however, makes it clear that his observations do not belong here at all. Hassall described the organism he found under the name of *bodo* Ehrenberg. The members of this genus have certain resemblances to trichomonas, but there are weighty reasons for believing that Hassall did not confuse the genera. In the first place, he was familiar with Donné's figure, having copied it in his well-known work on *Microscopic Anatomy* (vol. i. p. 3 ; vol. ii. plate xii. fig. 6).[43] In the latter article he does not speak of trichomonas, as he would have been likely to do had he thought, as later authors have done, that he had found the parasite in the urine. More important still is his testimony regarding the vital characteristics of the so-called bodo urinarius. Hassall said this was "generated in urine which is alkaline, contains much animal matter, and which is, moreover, freely exposed to the air." The organisms appeared under the above conditions in three or four days, by which time trichomonads would have disappeared had they been present in the beginning. It is most probable that Hassall saw some infusorial monads, of no present importance whatever, and having no relation to human pathology.

In 1868, Salisbury[44] stated that "trichomonas *vaginæ* [*sic*—this form was used by some of the early writers] occurs occasionally in the bladder." Exact details are wanting.

Künstler, of Bordeaux, in 1883,[45] reported the first case in which flagellates were found in freshly passed urine. The case was one of pyelitis following cystotomy. In the copious sediment were bodies which Kunstler thought might be cercomonads or the bodo urinarius of Hassall, although he remarked that they did not agree with Hassall's description. The bodies, he said, had two flagella, although at times it seemed as if three or four might be present. Künstler laid stress on the fact that the parasites came from the interior of the patient's body, where they lived in company with various bacteria. From the classification of Braun[49] (p. 108), it appears that Künstler at a later date assigned the

* This refers to human urine. From the time of Leeuwenhoek flagellates have been described, usually very vaguely, in the urine of lower animals.

parasites to the genus Plagionmonas Grassi. I cannot find a reference, and from the original description can see no reason for such a classification. Braun's statement that Blanchard called Künstler's parasite cystomonas urinarius, I am also unable to verify. It remains doubtful whether Künstler's parasites were really trichomonads.

Dr. F. Tilden Brown presented specimens and photographs of "ciliated infusoria in the urine" before the section of Genito-Urinary Surgery of the New York Academy of Medicine, December 12, 1893.[16] Dr. Brown has not yet reported the case in full, but from letters he was kind enough to write me it appears that the organisms belong to the ciliata, and therefore do not come under consideration here. The observation is extremely interesting, inasmuch as it widens the horizon of the protozoan parasites of man.

The first undoubted case of trichomonas in the urinary tract of man is that of Marchand.[10]

The host was a man aged 60 years, who had a fistula in the perineum. The fistula followed suppuration in the pelvis, of seventeen years' duration, thought to be tuberculous. Pus appeared suddenly in the urine without symptoms of cystitis, so that rupture into the bladder was suspected. The general condition improved, but the urine remained turbid and was sent to Marchand for examination. It was acid and albuminous, with a copious, dirty-yellow sediment. In the sediment were numerous whitish particles, made up of epithelial cells of different kinds, hyaline casts, and red blood-corpuscles. Among the epithelial cells were curious hyaline bodies, larger than leucocytes, which proved on closer examination to be flagellates. The urine was examined daily for some time, but the occurrence and condition of the parasites were variable, so that it was with great difficulty that their nature could be made out. The fresh urine always contained numerous bacilli and cocci. Tubercle bacilli could not be found. The flagellates were almost always exclusively in loose epithelial cell masses.

Marchand's description and figures leave no doubt that the parasites he found in this case are identical with those I found and reported later. As the result of comparative examinations of the parasites from the bladder and those in the vagina, Marchand concludes that there is at least a great resemblance if not identity. The former he found more hyaline, less plainly vacuolated, smaller, and more amœboid than trichomonas vaginalis. He doubted, with a caution unusual in the history of the intestinal flagellates, whether these differences suffice to prove different species, and thought they depended on the different media in which the organisms live. In a note to Miura's article, Professor Mar-

chand says he thinks it probable the parasites lived in the urethra. From the history given it seems more probable there had been a rupture into the bladder, as supposed at first.

By a curious coincidence, a short time after publishing his own account, Professor Marchand received from Dr. K. Miura, of Tokio, the account in manuscript of another case in which trichomonads were found in the urine of a man.[47]

The patient was a Japanese, aged 52 years, with bronchitis and slight tenderness in the left renal region. The freshly passed urine, of yellow color and acid reaction, contained several thread-like particles and small bits. These were composed of round cells, colorless mucus, different kinds of epithelial cells, and flagellates. Miura examined the bodies with inadequate instruments, and his description of them is imperfect for that reason. He did not see all the flagella, although he was certain about the undulating membrane. He gave, however, other evidence as to the identity of the parasites. He found that most of the particles were passed with the first part of the urine, and by putting in a self-retaining catheter convinced himself that the organisms came from the urethra and not the bladder. The source of infection thus made probable was confirmed by examining the patient's wife, and finding in the vagina flagellate organisms resembling in form and size those in the urine of the man.

The next case, and only other, so far as I can learn, was one observed by myself and reported in a preliminary note.[48]

The history is as follows: A. B., aged 27 years, student. Father living and well. Mother died in childbirth. Patient was born in Illinois, and lived there eleven years. Then lived near Gainesville, Texas, for thirteen years; in Oklahoma one year and a half; and Bryan, Texas, one year. Since then has lived in Ann Arbor, with the exception of two months in Florida. As a child had measles, whooping-cough, and scarlatina, without sequelæ.

For about nine years, while living in Texas, had malarial fever, usually of tertian type, sometimes quotidian. About 1884 had a "congestive chill" and was unconscious several days. Ever since then has had frequent urination. In the spring of 1892, while living at Bryan, Texas, had pneumonia. During convalescence painful and difficult urination came on, and after two days the urine became very bloody. This attack was considered one of malarial hæmaturia, and treated by quinine. The bleeding stopped, but difficult and painful urination continued. The symptoms became worse at irregular periods; they were made worse by "catching cold," by drinking whiskey in more than very

small quantity, or by a change of drinking water. During the attacks patient has to urinate about every two hours. There is then pain in the left lumbar region and in the right groin, and at times pain radiating to the urethra. At the end of urination whitish particles are passed with the urine. They are more numerous two or three days after the attacks begin, but can be seen in the urine at all times. The urine has never had an ammoniacal color.

Patient denies venereal disease and coitus entirely. Smokes a good deal, drinks whiskey occasionally. Appetite good, bowels regular. Now feels fairly well, aside from the symptoms mentioned. Has lost about eight pounds in the last year. The patient has consulted many physicians, some of whom have examined the urine. They have usually made the diagnosis of gleet, and advised instrumental treatment, but, as the patient knew he could not have gleet, he has always declined. A few days before I saw the patient his urine was examined by a colleague, who informed me that there was in it a good deal of blood and pus. Boric acid and salol were prescribed.

*Status præsens.* Man of tall and slender frame; muscles small, but firm; panniculus scanty; no œdema. Skin dark and sallow; extensive capillary nævi on face and body; mucous membranes healthy looking. Examination of lungs, heart, and abdomen negative. No enlargement of spleen or liver. Examination by rectum negative.

Patient passes 2 c.c. of urine without difficulty, and in full stream. This is pale yellow, clear, but with a number of small whitish flakes about the size of pin-heads, and a small amount of clear mucus in the last part. The urine is acid, sp. gr. 1020; no sugar nor albumin. The particles mentioned look like caseous bits, but are less opaque. Microscopically they are made up of pus-corpuscles, bladder epithelium of all kinds, and a number of bodies slightly larger than pus-corpuscles, of a peculiar amyloid appearance.

It was very soon apparent (at the first examination) that these were animal parasites, and, as I propose to describe them in full later, I omit the notes made at the time, as well as the full notes taken from time to time after that.

*October 25th.* Examination of blood: Blood flows freely, of good color and consistence. Hæmoglobin (Fleischl), 100 per cent.; red blood-corpuscles (Thoma-Zeiss), 5,860,000; leucocytes, 8333. Red corpuscles are of normal appearance and form good rolls. Leucocytes show normal differential count. No parasites found in the fresh or stained blood.

From this time the patient remained comparatively free from symptoms, though the particles were passed as before. From gratitude at

the improvement, and scientific zeal, he enabled me to examine his freshly passed urine at frequent intervals, sometimes daily, and to make all the necessary examinations, inoculations, etc.

I discovered very early that the particles are of two kinds. Some are small, or rarely long and narrow; opaque, with distinct outlines. These are made up of pus-corpuscles (polynuclear neutrophile cells, with a few eosinophiles). They rarely contain parasites. The others vary in size, sometimes being two or three millimetres in diameter. They are less opaque than the others, sometimes quite gelatinous looking. They are composed of large squamous epithelial cells, transition cells of various sizes, a few leucocytes, and parasites in variable numbers. Once I counted three hundred and fifty parasites in a single particle, which, when spread under the cover-glass, measured about 3 mm. in diameter.

November 15th the patient caught cold at a foot-ball game. That night he had pain in the back and frequent urination. Next day the parasites were more numerous than they had been for some time. In the night of November 19th the patient went out to urinate. He felt a sharp pain in the penis, and on returning to the house found some blood on his shirt. The next morning I found two or three blood-spots on the shirt. The urine contained a few red blood-corpuscles; parasites as before.

From this time the history of the case has been much the same. There have been no severe attacks of pain. The patient rarely has to get up at night. He has gained fifteen pounds, and says he feels better than at any time for ten years. The urine usually contains a few small particles, nearly always with parasites, but sometimes without any for several days at a time.

After a mild attack of influenza, during which the patient took salol and phenacetin, the parasites were more numerous, but the symptoms were not so severe as they had been after previous temporary illnesses.

When I first found the organisms I thought I had discovered a new species. The characteristic features of the bodies I saw were not mentioned as belonging to trichomonas in the hand-books in my laboratory, and I was not familiar with the recent and more accurate investigations. Fortunately, I was able to demonstrate the first specimen found to my colleague, Dr. J. Playfair McMurrich, who at once determined the genus. This has been amply confirmed since then by the observations I have made and the examination of the literature of the subject. I have been able to demonstrate the parasites to a large number of my colleagues in the medical department and the department of animal morphology, and to exhibit them alive at a meeting of the Journal Club (biological) of the University.

As regards the species I am in the same position as Marchand. The parasites I have studied agree with his descriptions more than with any others. He found slight differences as compared with tr. vaginalis, but not enough to lead him to give a new specific name. I have not been able since I found the bladder parasite to make examinations of tr. vaginalis. I think it better for that reason to describe the parasites as fully as possible, leaving the question of classification to other observers or the result of future comparative examinations.

My own examinations have been very numerous, and included the observation of the parasites alive under various conditions for hours at a time, almost daily for long periods, the study of the effects of reagents, staining, cultures, and inoculations. My microscopic observations were all made with Zeiss D.D. and one-twelfth-inch oil-immersion lenses.

Zoölogical Classification. Trichomonas belongs to the flagellate infusoria. In the classification of Bütschli, one of the most rational which has been attempted as regards the form we are now considering, it is placed in the sub-order Isomastigoda and family Tetramitina. This family includes the closely related *cercomonas* Davaine and *trichomonas intestinalis* Leuckart, which Bütschli includes under the generic name *monocercomonas* Grassi. According to the same author, about three species of trichomonas are known. All are parasitic, living in the intestines of frogs, snails, and other lower animals, and in the human vagina. Grassi, as mentioned before, includes some of the species in his genus *Monocercomonas;* others in that of *Cimœnomonas. Trichomonas vaginalis,* with which he was not familiar, he thought might belong in the family he called Trichomonadidea; this, and his description of that family, give conclusive evidence that his statements regarding his unfamiliarity with tr. vaginalis are true.

In the latest classification, that of Braun (*loc. cit.*, p. 108), the genus *Trichomonas* includes *tr. vaginalis* Donné and *trichomonas hominis* Davaine. The latter includes *cercomonas hominis* Dav.; *cerc. intest.* Lambl (1875), Marchand; *trichomonas intest.* Leuckart; and *monocercomonas resp. cimœnomonas* Grassi.

Evidently what is needed concerning the flagellate parasites is not so much classification and nomenclature as objective study. Braun deserves credit for restoring Donné's term, and is justified by the rule of priority, notwithstanding the imperfect description and etymological incorrectness of the French observer. The wisdom of including cercomonas in the same genus may be questioned.

Size, Form, and Structure of the Parasites. Trichomonas vaginalis is said by all who give measurements to be from 15 to 25

m.mm. in length, 7 to 15 m.mm. in width. The organisms found by Marchand and Miura in the urine were about the same size. A number of measurements in my own case showed that most of the bodies are from 15 to 22 m.mm. in length and 10 to 15 m.mm. in width, but a few are considerably larger and some smaller.

The form of the organism also agrees with the description of others. The commonest or typical form is a pyriform or broad spindle with one end rounded, or the shape of an apple-seed or almond-kernel. Sometimes the broad end is in front, sometimes behind. Sometimes the bodies are elliptical or oval; sometimes irregular (see figures). Donné early described changes of form like those in a leech. Without knowing that, I had compared the appearance to that of a garden slug. Occasionally, as will be described later, the form is altered as the result of special motion. Usually the smaller specimens are more typical in shape than larger ones. The bodies appear to be flattened from above downward.

The general appearance of the organisms is sometimes peculiar, so that they can be distinguished by tint or refraction before the characteristic organs are seen. Light and amplification have much to do with these things; in general the bodies are difficult to distinguish from leucocytes or other cells of similar size in the preparation until the motion of their peculiar organs is recognized. The outlines are usually sharp, the structure finely granular, sometimes hyaline and homogeneous, rarely coarsely granular.

The protoplasm is not easy to differentiate into separate parts. Künstler claims for tr. vaginalis the existence of a cuticular layer,[6] in addition to an ectoplasm. Marchand also describes a similar layer in the bladder parasite. I have never been able to demonstrate this, and the occurrence of pseudopods, to be described below, seems incompatible with a true cuticle. A differentiation into ecto- and endoplasm can, however, be made out, and the ectoplasm may in some cases simulate a cuticle. I have found the difference between the two layers well brought out by treating the organisms with (Gram's) iodine solution. The endoplasm retracts slightly in some places, and stains deeply after considerable time, leaving a thin and faintly stained membranous layer outside. Both in unstained and stained specimens the inner layer of protoplasm has a finely vacuolated appearance when examined by high powers.

Small vacuoles or highly refracting granules can sometimes be seen in the bodies, but there is no contractile vesicle. This agrees with the statements of all who have exained tr. vaginalis. In the parasites I have examined I have never been able to recognize any particular inclusions

such as bacteria, which others have found in tr. vaginalis. This may be due to the fact that the urine in my case seldom contained bacteria while under examination or while the parasites were still alive.

Effects of Stains and Reagents. The parasites are difficult and unsatisfactory to stain. The best results are obtained by staining alive or by staining specimens recently killed by sublimate. Placed alive or after being killed by sublimate in methylen-blue solution, the parasites remain as clear bodies long after all other cells are deeply stained. Afterward the bodies become stained, and look coarsely granular or finely vacuolated according to the degree of amplification. In such preparations the nucleus appears as described below. Neutral-red is not as satisfactory as methylen-blue in staining live specimens. In dried preparations, fixed by heat, alcohol and ether, osmic acid, bichloride, or formalin, stains of all kinds are very unsatisfactory for the protoplasm and usually also for the nucleus. In preparations fixed on the cover-glass, and stained by methylen-blue, a spiral line can sometimes be seen, extending from the insertion of the flagellum or near it, a variable distance backward. This has been noticed by others. I think it is an artefact, as it is extremely rare.

Strong sublimate solution (5 per cent.) has the effect of rendering the organisms motionless at once and making their protoplasm more granular, no doubt as the result of coagulation. It often produces contraction in the bodies, and especially causes the appearance of two highly refracting lines nearly or quite parallel, and in a direction similar to that of the nucleus. These lines I am quite confident are the result of contraction. They appear also under the influence of acetic acid. Similar appearances have probably led to the idea of internal organs, or of a "rib," or "keel" in or on the body.

Acetic acid, besides bringing out the nucleus, clears up the protoplasm. Later the bodies become round, and numerous granules can then be seen. They are often in rows or lines, but do not have a definite arrangement, as some authors have described in tr. vaginalis.

In unstained specimens the nucleus cannot be seen. Sometimes, with low powers, a bright or dark spot, depending on the focus, can be seen near the front of the body, as is also the case with cercomonas. This I think is only the effect of the refraction of the body. By the use of reagents, however, the nucleus can be plainly seen, and its characteristics examined. The nucleus is always in the anterior part, usually lying somewhat obliquely. Acetic acid brings out in this part a round or oval, highly refracting body, which comparative examinations prove to be the nucleus. It appears some time later than the nuclei of leucocytes or

1
2
3
4
5
6
7
a
b
8
9
10
11
12
13
14
15
16
17
18
19
20
21
22
23
24
25

epithelial cells in the same preparation. Sometimes the highly refracting nucleus is enclosed by two lines, as mentioned in speaking of the protoplasm (Fig. 16).

In preparations stained with methylen-blue alive or after killing with sublimate, an oval area appears, sometimes with a dark vesicular outline, sometimes with a diffuse stain deeper than that of the protoplasm, but less granular. At other times a clear vesicle appears, and in it a long deeply stained body, the nucleolus of many writers, more properly spoken of as the chromatin-body. Around this is a clear area.

The nucleus is best demonstrated by staining live parasites in acetic carmine. This clears up the protoplasm, brings out the nuclear-membrane, and stains the chromatin-body deeply and distinctly. It then appears as a long and narrow, somewhat irregular body. The lines on both sides of the nucleus are present in the beginning, but after a few hours the bodies become round, the contents clear, with the nuclear membrane and chromatin-body, as in Fig. 17. The nucleus is about one-fourth to one-third the length of the body of the parasite.

At the anterior end of the organism are the flagella, concerning the history of which a few words are necessary. Donné described only one of these, but said it was sometimes bifurcated. Scanzoni and Kölliker saw two or three. Künstler was the first to claim that four was the constant number. This was denied by Blochmann, and Bütschli, but confirmed by Henneguy, and Marchand found this number in both the vaginal and bladder parasites, but agrees with Künstler in saying that it is not always easy to recognize all four. After very extensive observations on this particular point I agree with Künstler. Often only one, two, or three flagella can be seen, even in a prolonged observation on the live organism. This is especially the case when the parasites are active. If, however, they are suddenly killed, as with saturated sublimate solution, four flagella can be distinctly seen. In specimens which die naturally, or sometimes in those killed with iodine, it can be seen that one flagellum is thicker than the other one or two, as is not the case when all four are seen.

---

Figs. 1–13. Trichomonas from the bladder. Drawn from different live specimens as seen with Zeiss 1–12th inch immersion objective and No. 2 ocular. Drawn approximately to the same scale and enlarged in the plate. For details see text.

Fig. 14. As stained alive in watery methylen-blue solution. Fig. 15. After fixing with sublimate and staining with methylen-blue. Fig. 16. Fixed by sublimate; stained with acetic. carmine. Fig. 17. Late stage after treating with acetic-carmine. Fig. 18. Trichomonas vaginalis as depicted by Donné. After HASSALL. Fig. 19. Cercomonas hominis. After DAVAINE. Fig. 20. Marchand's parasite from typhoid stool, 1875. Fig. 21. Zunker's parasite. Fig. 22. Trichomonas hominis. After GRASSI. Fig. 23. Cercomonas coli hominis. MAY. Fig. 24. Trichomonas intestinalis (Marchand). After ROOS. Fig. 25. Cercomonas hominis (Davaine). After ROOS. Figures 18–25 are reproduced as nearly as possible in the sizes of the originals.

The length of the flagella in my examples varied from one to three times the length of the body. Usually these organs are about one and a half to twice the length of the body. The flagella seem to taper slightly from their insertion to the tips. Blochmann and Künstler have carried on an argument about the tapering of the flagella of tr. vaginalis, and Künstler, who asserts that they taper, admits that the appearance may be the result of transparency. (See Bütschli, *loc. cit.*, p. 673.)

The flagella usually rise so close together that they seem adherent at the base, or to arise from a common pedicle. That they do not do this I am convinced by finding them separated at the base by a short pseudopod (Fig. 7) in one instance. Künstler held that the flagella arise from a sort of "rostral prolongation" of the body, a view which Marchand seems to support. In my own case I could find no evidence of it. The flagella have very clear outlines and a fine homogeneous structure. I could never see any evidence that they are sticky, as are the flagella of some other protozoa. I have made many efforts to stain the flagella, but without satisfactory results.

The posterior end of the body is sometimes prolonged into a long tail-like process. Donné no doubt saw this, as he said that the organisms fix themselves to the cover-glass, "not by suckers, but by a sort of viscous material which leaves a trail behind it." This appearance I have often seen. It seems to be due to the formation of a thin, soft, adhesive pseudopod. At other times a sharply outlined tail is present, which may resemble a flagellum, but usually differs in its more granular structure and its less distinct outline, and also by its lack of flagellar motion. It is, moreover, capable of marked change of form, and is often retracted, or contracted and expanded, showing its close relation to pseudopodial structures. The tail is likely to be adherent to various objects in its vicinity—leucocytes, other parasites, or granules of broken-down leucocytes. Not infrequently one can see two parasites attached by the tails, which often show curious changes of shape. This has led some to think the organisms undergo transverse division, but I have never been able to find evidence of the earlier stages of such a process. The most remarkable thing about the tail is that it may be absent from all the organisms examined for many days, and then be found on almost all examples in another specimen, so that when one finds one parasite with a long tail it is safe to predict that most of them will have them. In such cases a preparation containing a number of parasites presents a curious appearance, as if full of gigantic spermatozoa. It may be necessary to add that no error can be made between these two objects if one has other guides to the size of the organisms, as leucocytes in the field, or famil-

iarity with the microscope, so that the grotesque figures in a recent work on *Medical Jurisprudence* are not necessary to avoid confusion.

The most interesting part of the parasite, in many ways, is the undulating membrane. Donné thought the organism he discovered had a row of short cilia on one side, near the anterior end, and this error was handed down from one observer to another, until Künstler confirmed Stein's assertion, based on the relations in the trichomonas of the frog, that the so-called ciliary comb was an undulating membrane. The discovery of Künstler was confirmed by Blochmann and Bütschli. In my own case, although usually visible, in some examples the undulating membrane could never be seen, so that I think it can be temporarily absent. I found it absent usually in those parasites which exhibited most marked change of form, and it seems probable that there may be some relation between the two things, so that one function can replace the other under certain circumstances. Stein was of the opinion that the undulating membrane of trichomonas is not a permanent structure, in fact not a true membrane, but is due to the alternate projection and retraction of a part of the body; but this is denied by Bütschli. Opinions differ as to the extent and insertion of the membrane in tr. vaginalis. Künstler claimed that the membrane passes around the body of the parasite in a spiral line, being inserted in a sort of rib, but he admitted that it is only by a "lucky chance" that one can see the whole membrane. Blochmann, however, thought the membrane half as long as the body, and in this Marchand agrees with him. I have never found the membrane more than two-thirds the length of the body, extending from the insertion of the flagella backward; often it is much shorter. The membrane is sometimes on one side of the body, sometimes the other. It may extend out from the side of the body or be turned over or under it, or it may arise from a straight or spiral line on the anterior surface of the body facing the observer. No distinct line, ridge, or depression can be seen at its origin, and it often gives the impression of a gradual thinning out of the side of the parasite. The membrane varies much in width, and this variation is independent of the shape of the body. The outer edge of the membrane is sometimes thickened and so resembles a flagellum, but this is not constant. Very rarely have I been able to see the membrane prolonged to a point. Usually the posterior end tapers gradually to the side of the parasite. Owing to the fact that the outer edge is much longer than the insertion, the undulating membrane is always more or less zigzag, fluted, or scalloped, so that from the folds and the zigzags the appearance of a row of cilia is often very closely simulated. The membrane does not stain well.

The organisms I have seen have no signs of mouth or other digestive organs. Donné thought there probably was a mouth, but did not assert it as a fact, as has been claimed. Blochmann and Bütschli could not find one. Künstler claimed to find mouth and œsophagus, and claims that Gasser (*loc. cit.*, p. 35) described the mouth as a *cavité cupuliforme.* Marchand could not find it in live specimens, but in stained ones he saw tubular structures extending forward from the nucleus. I believe that some observers have mistaken the appearance produced by the undulating membrane, as it plays along the middle of the body, for the mouth. In such a case a narrow clear space appears to be in the body at that part. Another thing which Donné perhaps thought was the mouth I have often seen. This is a shallow depression or cleft near the insertion of the flagella, which no doubt has the function of a mouth. At times one side keeps up a nibbling motion, which is very suggestive of a mouth. The appearance is not permanent, however, and is rather uncommon.

Physiological Characteristics. The phenomena of motion presented by trichomonas are extremely interesting. The simplest is due to contractions of parts of the body, with change of form, as Donné mentioned. This enables the organisms to change their position to a considerable extent, so that in a few minutes one may move across the field. Such extensive motion, however, is unusual, and the process is generally limited to jerking movements of the body in different directions.

Another process consists in the projection of lobes, usually combined with contractions, so that amœboid motion is simulated. True amœboid motion, in which, along with a projection of the ectosarc there is a flowing in of the endosarc, I have not seen, and the changes of form and position are never so great as in typically amœboid organisms. That this function indicates the existence of a cuticular membrane is not a necessary conclusion, as some zoölogists have claimed, but it can be brought about by contractions of the outer layer of the plasma or of the plasma as a whole (Bütschli, *loc. cit.*, 849). I have also seen another process, mentioned by Blochmann and by Künstler. This consists in the appearance of a scalloped edge on one side of the body, with a wave-like motion running along it. I have only seen this in dying organisms and take it to be peculiar to that stage.

Another function exhibited by trichomonas consists in the formation and motion of pseudopods. My observations indicate that this is an important function. Künstler and Marchand seem to be the only observers who have noticed pseudopodial formation in trichomonas, but I have been fortunate in seeing it oftener and more specialized than they seem to have done. It can occur in any part of the body. In the simplest

form short knob-like projections appear on the body. (Fig. 7.) Much more frequently a long narrow process is formed, usually becoming fixed to something in the vicinity. (Figs. 6, 8, and 10.) Pseudopods of this kind often serve as organs of support. So in the parasite from which Fig. 12 was taken, the end of the process was fixed to the cover-glass like a sucker. The animal then made rapid and abrupt bobbing movements, resembling a duck diving for food. The pseudopod at such times bent at an angle, always in the same place. The body of the parasite at the same time changed its shape considerably, so that undulating membrane, which, at first, ran down over the back, came to be in front. At times a tail was present. At the anterior end a cleft often formed, and exhibited the nibbling motion in its sides, as mentioned above. The flagella and membrane were in active motion all the time. The narrow pseudopods expand and contract at times in different parts. The most remarkable pseudopodial action I have seen is depicted in Fig. 8. A similar process was seen several times. Here a pseudopod was passed over or under the side of an epithelial cell. The end then expanded and became branched, resembling a very irregular minute amœba. The lobules of the extremity then kept up a constant and somewhat rapid amœboid motion, resembling precisely that of an endoglobular malarial parasite. Sometimes the ends kept up rhythmic motion, giving a revolving effect. This pseudopodial function seems to be an important one in the nutrition of the parasite, especially when for any reason the flagella and undulating membrane cannot act.

The motion of the flagella is whip-like usually, but, at times, spiral, the waves always running from the insertion to the tip. Motion is not directed always in the same direction, as claimed by some in the case of trichomonas vaginalis. Sometimes the motion is toward the side of the undulating membrane, again toward the opposite side. Usually it is directly forward. Sometimes one flagellum has a different direction from the rest, bending down along one side, or across the body. Sometimes a flagellum turns down along one side, and, without touching anything, acts as a point from which the whole body moves, apparently as the result of a powerful action of the flagellum. By their ordinary motion the flagella produce a current toward their insertion, causing granules in the fluid to shoot with great velocity against the anterior end of the body. At such times the appearance of a mouth is often produced, the granules apparently being taken in by stomata which form and disappear.

The motion of the undulating membrane is usually a waving one from before backward, due to the ciliary motion of the edge; sometimes the

motion is apparently spiral. The rapidity of the motion varies very much, and this, with the difference in the width of the membrane, gives great variety to the appearances presented. Sometimes close folds are produced, sometimes zigzags advance and retract along the edge, and often the membrane seems to be actually revolving, like the arms of a windmill. Sometimes the general direction of the membrane is greatly altered, as shown in Fig. 7, *a* and *b*.

The membrane also produces a current which runs toward the anterior end, carrying floating granules with it.

That the membrane, as well as the flagella, acts as an organ of locomotion seems likely, but I have never seen it. Even in the hanging-drop on the warm stage I have never seen the parasites swimming freely. In this respect they offered a marked contrast with cercomonas Davaine. According to Künstler the undulating membrane acts as a locomotor organ when the parasites are closely surrounded, enabling them to move as a serpent does.

The trichomonas, as I have found it, is extremely sensitive to external conditions. Kept in an incubator, in the urine as passed, the parasites remain alive and active for six or seven hours. In the usual room-temperature they die an hour or two earlier. Organisms dying in this way often show a few short, straight, hair-like processes on various parts of the body. These are not bacteria, but are most probably like the similar processes sometimes present on dead or dying cells of various kinds.

If a preparation containing parasites is examined from time to time without allowing it to evaporate the organisms completely disappear, and nothing remains that can be recognized as derived from them. The same is true of specimens kept in an incubator for twenty-four hours or more.

Cold is injurious to the organisms, so that on the slide in a cold room little or no motion is seen; but if the room is warmed, or the preparation put on a warm stage, motion soon becomes active. All the phenomena of motion are marked at a temperature of 80° F., more active still at 98°, but cease in a few minutes if the warm stage is heated up to 120°. When the organisms are becoming sluggish from long stay out of the body they cannot be revived by heat. The addition of dilute alkalies, which stimulates some protozoa, has no effect on them, but stronger solutions are injurious.

The organisms occur always, as I have said before, in acid urine. Künstler has called attention to the fact that trichomonas vaginalis also lives in an acid medium, a fact on which Donné laid considerable stress,

and which seems to have few exceptions, Haussmann saying they occur in alkaline secretions, though not in large numbers.

As the parasites are anaërobic—as Künstler showed tr. vaginalis to be—I made an effort to grow them in that condition. I was fortunate in getting my friend, Dr. F. G. Novy, to make some trials with the admirable apparatus devised by him (*Centralblatt für Bakt. und Parasit.*, 1893, Bd. xiv. p. 581). We tried urine, as well as numerous culture solutions, but without effect. The parasites disappeared just as they did when exposed to the air.

Mercuric chloride kills the motion and at the same time fixes the organisms. Compound solution of iodine also stops motion of all kinds at once.

When the bodies are dropped into saturated solution of sulphate of quinine the motion of the flagella and of the undulating membrane stops at once. In a few (three) minutes the bodies swell out and become clear, with bright granules scattered through them, sometimes arranged in lines. The bodies are very soft, as shown by the indentation produced by other bodies pressing on them. A little later the flagella and undulating membrane begin a spasmodic jerking motion. The bodies become larger and larger, the undulating membrane very narrow. Hyaline vesicles break out from the sides of the swollen bodies. The motion of the flagella sometimes lasts for an hour, by which time, however, the bodies are usually only large collections of clear vesicles. The process here seems partly poisonous, partly due to inhibition as the result of paralysis. Water alone does not produce the vesicular change so rapidly.

Salicylic and boric acids cause similar changes. No appreciable difference in rapidity can be seen in the action of these various drugs.

Efforts to grow the organisms in the bodies of animals failed. I first tried the vagina and bladder of guinea-pigs and rabbits. As the urine of these animals is very alkaline I used a large bitch. After the first trial under chloroform it was possible to catheterize the animal without an anæsthetic, so that the experiment was quite simple. Although a vaginitis and mild cystitis occurred from intentional irritation with the end of the (glass) catheter, no flagellates appeared as the result of numerous injections of epithelial bits containing active parasites. The dog's urine, however, though acid, is not identical with that of man, so that I do not consider the experiments very conclusive. Experiments on man could not be made.

Reproduction. It is generally admitted that all flagellates multiply by longitudinal division, although some have other methods besides. Künstler and Marchand have observed longitudinal division in tr. vagi-

nalis, the latter finding frequent evidence of it. In my experience the process has been very rare. I have seen it only twice, once in a preparation stained by acetic carmine, and once in a live specimen. (Fig. 13.) In the latter, a very large body, there were two sets of flagella and two undulating membranes, one being between the sets of flagella. In trying to stain the organism alive I lost it. (It might be thought that this figure represents a copulation-process. From what we know of this among the flagella, however, such is not the case.)

Of the formation of "dauer" spores, etc., in trichomonas, nothing is known, but from the number of parasites often present in my case and the scarcity of dividing bodies it seems there must be some other method of reproduction than that by division.

Mode of Infection by Trichomonas. From our present knowledge of the distribution of trichomonas it is impossible to explain its mode of entrance in man. The most probable explanation is that it exists in some other form, perhaps in water or on plants, and gains entrance to various animals in that way. The theory of Cunningham that both cercomonads and trichomonads are nothing but zoöspores of amœbæ, inviting as it is, has not been confirmed. Perroncito,[50] who has made a special study of cercomonas, claims that it becomes encysted, forming "dauer" forms, which are more resistant to external influences than the active forms, and are readily transported, and so enters the human body. May thought his patient had been infected by drinking-water, and Epstein brings almost conclusive proof that the organisms found by him entered the body in the drinking-water. He noticed, for example, that sucklings who never drank water never had the protozoan diarrhœa. At one time three children in one room got the disease simultaneously. A fourth child in the same room, by reason of his condition, drank no water. After demonstrating that the stools of this child were free from flagellates, he was given in the course of twenty-four hours 250 c.c. of water from the pump from which the other children were supplied. On the same day flagellates appeared in the stools, which soon became watery, were forcibly ejected, and later showed large numbers of parasites. The so-called monocercomonads could not be found in the water, nor any form with which they could be supposed to have relationship. (It is an interesting fact that the water in question came from the pump used by the patients with amœbic dysentery reported some years ago by Hlava.[51] Epstein makes the important statement that amœbæ have been found in that water.)

It is, of course, possible that the water contained organisms in numbers too small to enable them to be discovered. Whether that is true,

or that the organisms existed in the water in another form, their prompt appearance in the stools of Epstein's patient is a noteworthy fact, indicating rapid reproduction under favorable circumstances. It is easier, however, to imagine how organisms of this kind can enter the intestine than to explain how they enter the vagina, especially since injections of ordinary water kill the developed forms. Balbiani (cited by Henneguy) thinks that the flagellates may be swallowed in water, set free in the intestine, and wander from the anus along the perineum into the vagina, as does oxyuris. If Schuberg is correct in thinking the flagellates almost constant inhabitants of the intestine, this theory would have much in its favor.

In the cases in which flagellates were found in the urine of men the question as to mode of entrance is extremely interesting. In Künstler's case one can suppose the organisms came from the intestine and gained entrance to the bladder through the perineal wound. If in Marchand's case there was really a rupture of the intestine into the bladder, as the history makes probable, we should have important evidence regarding the intestinal flagellates, as well as a ready explanation of the mode of infection. If, on the other hand, as Marchand thinks, there was an infection of the urethra, as happened in Miura's case, the manner of infection is clear, but the question arises why such urethral infection is not more frequent in places where trichomonas vaginalis is as frequent as some authors have found it. (Scanzoni and Kölliker in more than half, Haussmann in as many as 40 per cent. of women examined, Künstler in nearly all women who had leucorrhœa and did not use injections.)

In my own case the relations seem to be unique. Not only the assertions of the patient, but also the characteristics of the urine, exclude infection by the urethra, and I think we must admit that the parasites reached the urinary tract indirectly. Such an event is, of course, no more remarkable in itself than many well-established facts in pathology.

Pathological Importance of the Flagellates. The question remains, have the organisms under discussion any pathogenic powers or are they simple "commensals?"

When Donné first reported the existence of trichomonas vaginalis he thought it characteristic of venereal blennorrhagia, though he did not commit himself to the belief in its causal relation. Later, he thought the organism had no specific importance, as he found it in muco-purulent discharges due to irritants of all kinds, *e. g.*, pessaries. Scanzoni and Kölliker thought the parasites had no specific action, but believed they were never found in the normal vaginal secretions. Künstler thought they must have pathogenic action, but not of a specific kind. The prev-

alent opinion among recent writers is that the organisms are accidental parasites in the vagina and mere "commensals." Here, of course, the organisms are never alone, but always accompanied by bacteria, many of which are pathogenic, so that it is impossible at present to assert that the animal parasites produce the disease with which they are associated. This does not imply that they have no pathogenic action.

As regards the intestinal parasites, the general opinion is that at the most the flagellates can by their presence keep up a diarrhœa which furnishes favorable conditions for their development. Many writers, especially Cunningham, Grassi, and Schuberg, think the organisms common parasites of the intestine. The clinical observations of Epstein, however, show that at least some of the intestinal flagellates can produce diarrhœa in man, and Perroncito (*loc. cit.*) claims that a species of intestinal cercomonas causes a fatal disease in guinea-pigs.

In the cases of Künstler, Marchand, and Miura the flagellates were associated in the urine with bacteria, so that no conclusion can be drawn as to their relation to disease.

In my own case the conditions were simpler and seem to me to require a revision of the whole subject.

The patient has had for some months, while under observation, a peculiar pathological process in the urinary tract, presumably in the bladder. It is probable the condition has existed for many years. This process is distinguished by an exudation of leucocytes and a desquamation of epithelial cells such as occurs in many cases when there is local disease in the organs concerned. So, for example, a tubercular nodule, a localized gonorrhœal infection might have such results. In this case, however, there is no sign or history of stone and no signs of bacterial infection. Culture experiments, repeated under various conditions, aërobic and anaërobic, show no bacteria at all, and bacteria are invariably absent from cover-glass preparations when pains are taken to exclude contamination from the outside of the body. I am therefore forced to the conclusion that the parasites have produced the anatomical alterations, the evidence of which is so clear.

There is another feature which deserves consideration—the hæmaturia. Although this has not been excessive since the patient came under my observation, it has at least been at times out of proportion to the exudation. It must be remembered that since the patient has been under my care remedies have been used more or less regularly, which must have a harmful effect on the parasites and lessen their activity.

I have in another place (Hare's *System of Practical Therapeutics*, vol. ii. p. 356) expressed my doubt regarding the malarial nature of certain

cases of hæmaturia occurring in the Southern States. When in Texas, besides cases of undoubted malarial hæmaturia, I saw others which showed no evidence of malaria. It is well known that there is an apparently endless controversy regarding the treatment of such cases, a fact in striking contrast to the conditions in other malarial diseases. I did not see these cases under circumstances favorable for investigation, however, and often had to be satisfied with the examination of specimens sent a long distance. I suggested that some of these cases might be due to filaria or to Bilharzia, although I could find no positive evidence. In the light of the case now reported I do not think trichomonas can be left unconsidered in future investigations on this important subject.

In connection with this it is interesting to recall the cases in which amœbæ were found in the urine, reported by Baelz,[52] Jürgens,[53] Kartulis,[54] and Posner.[55] These are important clinically and anatomically because in three cases there was hæmaturia, and in the fourth (Jürgens), the clinical details which are wanting, hemorrhagic lesions in the bladder. This was the only case in which an autopsy was obtained. (Posner's case was the only one remaining alive.) Jürgens found small cysts in the thickened bladder-wall full of amœbæ. In Posner's case there were evidences that the kidney was affected, without signs of disease of the bladder. Posner thought the amœbæ had become encysted in the kidney, and so caused hæmaturia and nephritis. In this case, the only one observed for more than a short time, the patient had five attacks of hæmaturia in the course of several months. In the case of Baelz, a girl with tuberculosis of the lungs and genito-urinary tract, amœbæ were found in the vagina, and the observer thought they had entered that organ in washing, increased there, and then gained entrance to the urethra and bladder. In Jürgens's case, also a woman, bodies were found in the vagina, which seemed to be earlier forms of the parasite. Posner thought that in his patient, a man, the parasites had entered the urethra and travelled up.

Two things must be borne in mind in considering the pathological relations of trichomonas. In the first place, we cannot assume that this is a harmless parasite always, because of its occurrence in comparatively mild diseases of the vagina and intestine, for organisms innocuous on such surfaces might in the bladder, ureter, or kidney set up severe or dangerous processes. Here I recall the finding of several hundred parasites in one small bit of epithelium on one occasion, strongly suggestive of cysts such as Jürgens found in his amœba case.

In the second place we must remember that this parasite is not necessarily as rare as the few cases reported might seem to indicate. The

history of the amœba coli and that of the malarial hæmatozoon show the need of caution in this respect, and the trichomonas, like the other organisms just mentioned, can only be found if the substance containing it is examined under favorable conditions. That I found the bodies I attribute to the effort I always make to examine urine as soon as passed, a practice of great value in many ways. Experienced microscopists had examined the same case, but without taking that precaution, and without success.

The precise place of trichomonas in pathology can, of course, be fixed only by further observation and experiment. If I am wrong in attributing to it a pathogenic power it does not possess, I feel that my observations on it have at least some value as a contribution to the biology of the flagellate protozoa.

## Bibliography.

1. *Donné, L.:* Animalcules existant dans certaines matières purulentes. Comptes Rendus de l'Académie des Sciences, 1836, tome iii. p. 385.

—— Recherches microscopiques sur la nature des mucus, etc., Paris, 1837.

—— Cours de Microscopie, Paris, 1844.

2. *Scanzoni and Koelliker:* Das Secret der Schleimhaut der Vagina und des Cervix Uteri. Beiträge zur Geburtskunde, Bd. ii. 1855.

3. *Hennig:* Der Catarrh der inneren weiblichen Sexualorgane, Leipzig, 1862.

4 *Haussmann:* Die Parasiten der weiblichen Geschlechtsorgane, Berlin, 1870.

5. *Gasser:* Les parasites des organes génitaux de la femme, Paris, 1874.

6. *Künstler, J.:* Comptes Rendus de l'Académie des Sciences, 1883, tome xcvii. p. 755.

—— Journal de Micrographie, Paris, 1884, vol. viii. p. 317.

7. *Henneguy:* Dictionnaire encyclopédique des Sciences médicales, 1885, tome 97. *Art.* Trichomonas.

8. *Blochmann:* Zeitschrift für wissenschaftliche Zoologie, 1884, Bd. xl. p. 42.

9. *Bütschli:* Bronn's Klassen und Ordnungen des Thierreichs, Bd. i. Protozoa ; Abtheilung ii. p. 676, etc.

10. *Marchand, F.:* Ueber das Vorkommen von Trichimonas im Harne eines Mannes, nebst Bemerkungen über Tr. vaginalis. Centralblatt für Bakteriologie und Parasitenkunde, 1894, Bd. xv. p. 709.

11. *Dujardin:* Histoire naturelle des Zoophytes Infusoires, 1841.

12 *Perty:* Zur Kenntniss kleinster Lebensformen nach Bau, etc., Bern., 1852.

13. *Davaine:* Traité des Entozoires, Paris, 1877.

14. *Stein:* Die Organismus der Infusionthiere, Leipzig, 1878.

15. *Davaine:* Comptes Rendus de la Société de Biologie, Paris, 1854 ; 2 serie, tome i. p. 129.

16. *Dock:* Observations on Amœba Coli in Dysentery and Abscess of the Liver. Texas Medical Journal, April, 1891.

17. *Ekecrantz:* Virchow-Hirsch's Jahresbericht, 1869, Bd. i. p. 202.

18. *Tham:* Ibidem, 1870, Bd. i. p. 314.

19. *Cunningham:* On the Development of Certain Micro-organisms Occurring in the Intestinal Canal. Quarterly Journal of Microscopic Science, 1881, vol. xxi.

20. *Grassi:* Sur quelques Protistes endoparasites, etc. Archives Italiennes de Biologie, 1882, vol. ii. p 402 ; 1883, vol. iii. p. 23.

21. *Von Jaksch:* Ueber das Vorkommen von thierischen Parasiten in den Fæces der Kinder. Wiener klin. Wochenschrift, 1888. No. 25.

22. *Müller:* Centralblatt für Bakteriologie und Parasitenkunde, 1890, Bd. viii. p. 592.

23. *Massiutin:* Ibidem, 1889, Bd. vi. p. 451.

24. *Kartulis:* Zur Ætiologie der Dysenterie in Ægypten. Archiv für path. Anatomie, etc., 1886, Bd. cv.

25. *Cahen*: Ueber Protozoen im kindlichen Stuhle. Deutsche med. Wochenschrift, 1891, No. 27.

26. *Lutz:* Zur Kenntniss der Amœben-Enteritis und -Hepatitis. Centralblatt für Bakt. und Parasitenkunde, 1891. Bd. x. p. 242.

27. *Councilman and Lafleur:* Amœbic Dysentery. The Johns Hopkins Hospital Reports, December, 1891, vol. ii. Nos. 7, 8, 9.

28. *Schuberg:* Die parasitischen Amœben des menschlichen Darmes; Kritische Uebersicht. Centralblatt für Bakteriologie und Parasitenkunde, 1893, Bd. xiii.

29. *Lambl:* Mikroscopische Untersuchungen der Darm-Excrete. Vierteljahrschrift für die praktische Heilkunde, 1859, Bd. 61.

30. —— Cercomonas et Echinococcus in hepate hominis. Russian Medical Reports (Russian), 1875, No. 33.

31. *Marchand:* Ein Fall von Infusorien im Typhus-Stuhl. Archiv für path. Anat., etc., 1875, Bd. lxiv. p. 293.

32. *Zunker:* Ueber das Vorkommen des Cercomonas intestinalis im Digestionscanal, etc. Deutsche Zeitschrift für praktische Medicin, 1878, No. 1.

33. *Leuckart:* Die Parasiten des Menschen, 2 ed., Bd. i. p. 315.

34. *May, Richard:* Ueber Cercomonas coli hominis. Deutsches Archiv für klinische Med., 1892, Bd. 49, p. 51.

35. *Roos:* Ueber Infusoriendiarrhœ; Ib. 1893, Bd. 51, p. 505.

36. *Epstein, Alois:* Beobachtung über Monocercomonas hominis (Grassi) und Amœba coli (Loesch) bei Kinder-Diarrhœn. Prager med. Wochenschrift, 1893, Nos. 38, 39, 40.

37. *Lenhartz:* Mikroscopie und Chemie am Krankenbette, p. 61.

38. *Kannenberg:* Ueber Infusorien im Sputum. Archiv für path. Anatomie, 1879, Bd. lxxv. p. 471.

39. —— Ueber die Infusorien in den Sputis bei Lungengangrän. Zeitschrift für klin. Med., 1880, Bd. i. p. 228

40. *Streng:* Infusorien im Sputum bei Lungengangrän. Fortschritte der Medicin, 1892, Bd. x. p. 757.

41. *Litten:* Ueber Hydropneumothorax und das Auftreten von Cercomonaden im lebenden Lungengewebe Verhandlungen der Congress für innere Medicin, 1886, p 417.

42. *Hassall, A. Hill:* On the Development and Significance of Vibrio Lineola, Bodo Urinarius, etc. The Lancet, London, 1859, ii. p. 503.

43. —— The Microscopic Anatomy of the Human Body in Health and Disease, London, 1849.

44. *Salisbury:* The American Journal of the Medical Sciences, April, 1868, p. 377.

45. *Künstler:* Analyse microscopiques des urines d'un malade atteint de pyélite consécutive à une opération de taille. Journal de Médicine de Bordeaux, 1883–4, vol. xiii. p. 249.

46. *Brown, F. Tilden:* Ciliated Infusoria in the Urine. Journal of Cutanéous and Genito-Urinary Disease, 1894, p. 81.

47. *Miura:* Trichomonas vaginalis im frischgelassenen Urin eines Mannes. Centralblatt für Bakt. und Parasit., 1894, Bd. xvi. p. 67.

48. *Dock:* Flagellate Protozoa in the Freshly-passed Urine of a Man. The Medical News, 1894, ii. p. 690.

49. *Braun, Max:* Die thierischen Parasiten des Menschen, 2 ed.

50. *Perroncito:* Ueber die Art der Verbreitung des Cercomonas intestinalis. Centralblatt für Bakteriologie und Parasitenkunde, 1888, Bd. iv. p. 220.

51. *Hlava:* Centralblatt für Bakt. und Parasit., 1887, Bd. i.

52. *Baelz:* Ueber einige neue Parasiten des Menschen. Berliner klinische Wochenschrift, 1883, p. 237.

53. *Jürgens:* Verhandlungen des Vereins für innere Medicin. Deutsche med. Wochenschrift, 1892, p. 454.

54. *Kartulis:* Ueber pathogene Protozœn bei dem Menschen. Zeitschrift für Hygiene, 1893, Bd. xii. p. 1.

55. *Posner:* Ueber Amœben im Harn. Berliner klin. Wochenschrift, 1893, p. 674.

*April* 25, 1895.

### 20. *Oestrus humanus Humboldt.*

Exhibited by Dr. Joseph Leidy.

This specimen I present through the courtesy of Dr. Foster, of Texas, who forwarded it to me with the report "that he had under his care a patient who had passed the worm from the intestines." On examination it is proved to be the larvæ of the œstridæ, or bot-flies, which are frequently found upon the human body as well as upon the lower animals, particularly sheep and horses. This specimen coming from the intestines suggests that the female laid her eggs somewhere about the anus, and in the course of development the larvæ dropped to the ground during the effort of straining at stool. The above name was given to it by Humboldt, as he believed that a special variety infected man. However, the specimen here presented shows nothing characteristic to distinguish it from the œstrus as noted in the lower animals, except in size.

In the south of America this parasite is by no means rare upon man. It occurs especially upon the arms, the back, the scrotum, and abdomen. The prognosis is favorable; incision and removal all that is necessary.

*May* 9, 1895.

---

### 21. *The bacillus of bubonic plague.*

Exhibited by Dr. Augustus A. Eshner.

The slide that I have the pleasure to present shows a section of tissue from an inguinal gland of a case of bubonic plague at Hong Kong. It was received from Dr. James E. Reeves, of Chattanooga, Tenn., into whose hands it came through a medical officer of the United States Navy stationed in China. I quote from a letter by Dr. Reeves:

"The section . . . shows considerable fragmentation in certain parts, partial thrombosis—fibrin and leucocytes—and well-marked fibrinous and leucocytic infiltration in the periglandular adipose tissue, with plugging of the lymphatic vessels. It is here, in the periglandular tissue, that the greater masses of short bacilli with rounded ends are found; and along with them the accumulation of more or less fibrin. In some of the densely packed fields it is difficult to make out the forms of the

bacteria, whether cocci or rods; but they are seen to be rods when a good view of them can be had."

According to Lawson,[1] the bacterium of bubonic plague resembles the bacilli found in the hemorrhagic septicæmias, except that the ends are somewhat more rounded, and that when lightly stained it presents the appearance of encapsulated diplococcus, and when more deeply stained that of an ovoid bacillus with a somewhat lighter centre.

According to Kitasato,[2] the bacilli are to found in the blood, in the buboes, in the spleen, and in all other internal organs of the victims of the disease. They are rods with rounded ends, which are readily stained with the ordinary aniline dyes, the poles being stained more deeply than the middle part, especially in blood preparations; they present a capsule, sometimes well marked, sometimes indistinct. The bacilli found in the spleen are best stained by a solution of methylen-blue. The bacilli show very little movement; those grown in beef-tea and kept in the incubator make the medium somewhat cloudy. The growth of the bacilli is most active on blood-serum at the temperature of the human body; under these conditions they develop luxuriantly and are moist in consistence, and of a yellowish-gray color; they do not liquefy the serum. On agar-agar jelly (the best is good glycerin-agar) they also grow freely. The different colonies are of a whitish-gray color, and by reflected light have a bluish appearance; under the microscope they appear moist and in rounded patches with uneven edges. At first they appear everywhere, as if piled up with "glass wool," later as if having dense, large centres. A cover-glass preparation made from a cultivation on agar-agar, and stained, shows under the microscope long threads of bacilli which might, by careless inspection, be mistaken for a coccus-chain, but are recognized with certainty as "threads of bacilli" upon closer observation. The growth on agar-gelatin is similar to that on agar-agar; in a puncture-cultivation at the ordinary temperature the colonies are, after a few days, found growing as fine dust in little points alongside the puncture, but with very little growth on the surface. On potatoes, at a temperature of from 28° to 30° C., there was no growth after ten days' observation, but at a temperature of 37° C. the bacilli developed sparingly after a few days; they were whitish-gray in color, and exsiccated. The bacilli grow best at a temperature of from 36° to 39° C.

It may not be inopportune to refer briefly to the clinical aspect of the disease as detailed by Kitasato. After a period of incubation lasting from three to five days, the patient complains of high fever and swelling

[1] Lancet, August 11, 1894, p. 325.
[2] Ibid., August 25, 1894, p. 428.

of one or more lymphatic glands. The glandular enlargement may antedate, coincide with, or follow the rise in temperature, and is attended with severe pain. The gland most commonly affected is one of the femoral chain; next in frequency an inguinal gland, then an axillary, and sometimes a cervical. The tongue is coated with a grayish-white or dark-brown fur. There is commonly headache and also delirium. Occasionally vomiting and diarrhœa are present, usually as the forerunners of a fatal issue. In patients who survive the temperature does not fall before the lapse of a week, and convalescence is slow. Both sexes and all ages are equally attacked. Characteristic bacilli are to be found in the blood during life. It is believed that they gain entrance through the respiratory or intestinal tract, or through an external wound.

*May* 9, 1895.

# INDEX.


ABBOTT, A. C., a review of some of the disputed points in connection with diphtheria, and some of the conditions with which it has been confounded, 237
discussion, 53, 168, 249
the bacillus diphtheriæ and some of the characteristics by which it may be recognized, 253
Abdominal tumor, ovarian origin (?), 129
Abscess of cerebellum, 167
of kidney, 141, 147
of liver, 15, 40
amœbic, 38
of peritoneum, 42
Addresses of Presidents, Annual, 1, 3
Adenoma of stomach, 50
Allyn, H. B., mucus casts of bowel, 50
Amœbic abscess of liver, 38
Anæmia, pernicious, 75
Aneurism, arterio-venous, of arm, 105
of aorta, 71, 72, 74, 87, 89
of heart, 86, 105, 112
Antitoxin of diphtheria, preparation of, 263
Aorta, aneurism of, 71, 72, 74, 87, 89
Aortic obstruction, 65, 84, 99, 100, 133
Appendicitis, 40
Ashton, T. G., tricuspid stenosis with mitral and aortic stenosis, 100

BACILLUS diphtheriæ, 253
mallei, 253
of bubonic plague, 312
Bacteriological case, 209
Baldy, J. M , fibroids of uterus, 127
Ball, M. V., carcinoma of stomach and liver, 26
Barton, J. M., arterio-venous aneurism of arm, 105
Bile-duct, dilatation of, 10
obstruction of, 69
Bladder, ulcer of, 147
Blood from case of sarcomatosis, 82
Bowel, mucus casts of, 50
rupture of, 42
Brain from case of fracture at base of skull, 160
tumor of, 161
Breast cancer of, 125, 138, 152
fibroma of, 157
Bronchitis, fibrinous, 115
Bubonic plague, bacillus of, 312
Burr, Chas. W., discussion, 84
nervous symptoms and lesions of diphtheria, 284
spinal cord from a case of Pott's disease, 163

CÆCUM, cancer of, 10
Calcareous concretion from tonsil, 59
Calculi of kidney, 141
Cancer of breast, 125, 138, 152
of cæcum, 10
of colon, 52
of gall-bladder, 9, 56
of larynx, 119
of mediastinum, 179
of œsophagus, 18, 28
of pancreas, 61
of stomach, 12, 55, 58
and liver, 26, 35
and pulmonary tuberculosis, 26
Carcinoma (*see* Cancer).
Caries of odontoid process of axis, 7
Carter, W S., discussion, 82
enlarged prostate, cystitis, nephritis, 123
gallstones, 22, 37
Meckel's diverticulum, 24
Casts, mucus, of bowel, 50
Cattell, K. W., cancer of œsophagus, 18
discussion, 80
encysted and organized empyema, 119
large abscess of liver secondary to dysentery, 15
old hemorrhagic cyst situated in both caudate nuclei and bilateral psammomata of the choroid plexus, 159
pustules from a case of variola, 209

Cattell, K. W., section of nodule of glanders from the lung of a horse, showing bacillus mallei, 253
Caudate nuclei, cyst of, 159
Cerebellum, abscess of, 167
tuberculoma of, 168
Cerebral hemorrhage, 164
tuberculosis, 145
Choroid plexus, psammomata of, 159
Circulatory system (in diphtheria), 280
Cirrhosis of the liver, 27, 69
in a boy, 19
Cohen, S. Solis-, a case of primary sarcoma of the spleen with extensive metastasis, 250
discussion, 204, 212
Colitis, acute infections, 24
Colon, carcinoma of, 52
Congenital absence of gall-bladder, 30
disease of heart, 83
Conjunctiva, sponge-grafting of, 246
Coplin, W. M. L., aneurism of heart, 105, 106
discussion, 52, 80, 82, 87, 162
enlarged uterine veins, 151
stomach from a case of creosote-poisoning, 23
Craig, A. R., aneurism of the aorta, 89
Creosote, stomach from a case of poisoning by, 23
Curry, G. E., cancer of cæcum, 10
endocarditis, 76
Cyst of caudate nuclei, 159
of liver, hydatid, 53
of ovary, 147, 155
Cystitis, 123

DALAND, J., alcoholic purpura hemorrhagica associated with chronic interstitial nephritis, 235
aneurism of heart, 86
blood from a case of sarcomatosis resembling leukæmia, 82
cancer of the stomach and pulmonary tuberculosis, 26
discussion, 164
dissecting aneurism of aorta, 87
disseminated tuberculosis, 231
fatty degeneration and infiltration of the heart, 92
spleen from a case of miliary tuberculosis, 210
Davis, G. G., discussion, 80, 82
Deaver, J. B., discussion, 9, 10, 147
Detweiler, Dr. discussion, 25
Dilatation of biliary ducts, 10
Diminutive liver from an infant, 53
Diphtheria antitoxin, preparation of, 263
Diphtheria, a review of some disputed points in connection with, 237
glandular and circulatory systems in, 280
respiratory system in, 276
the bacillus of, 253
the nose, eye, and ear in, 282
the pathology of, 253
Dock, Geo., trichomonas as a parasite of man, 287
Dougherty, S. W., two cases of ruptured tubal pregnancy, 146
Duodenum, ulcer of, 68
Dysentery, abscess of liver secondary to, 15

EAR in diphtheria, 282
Emphysema of lungs, 114
Empyema, 119
Endocarditis, 76
ulcerative, 84
Endothelioma of pleura, 185, 199
Eshner, A. A., congenital absence of gall-bladder, 30
diminutive liver from infant, 53
the bacillus of bubonic plague, 312
Eye in diphtheria, 282

FIBROMA of breast, 157
of receptaculum chyli, 204
of skin, 209
of stomach, 50
of uterus, 127, 132
Flexner, S., the pathological changes caused by certain so-called toxalbumins—an experimental study, 212
Fracture of base of skull, 160
Fussel, M. H., brain from a case of fracture of base of skull, 160
carcinoma of larynx, 119
hydrocephalus preventing delivery, 162
impacted gallstone—dilatation of biliary ducts, 10
laryngeal perichondritis complicating typhoid fever, 120
mediastinal sarcoma, 202
retroperitoneal sarcoma, 172
sarcoma of uterus, 142
tubercular tumors of cerebellum, 168

GALL-BLADDER, congenital absence of, 30
primary cancer of, 9, 56
Gallstones, 10, 22, 37
Gibbons, Dr., chronic nephritis, with great aortic stenosis, 133

Glanders of lung, 253
Glandular system in diphtheria, 280
Goitre, cystic substernal, 188
Griffith, J. P. C., aortic stenosis, 84
discussion, 203
the respiratory system (in diphtheria), 276
ulcerative endocarditis, 84
Guitéras, John, discussion, 37
metastasis of cancer of breast, 138

HAMILL, S. M., bronchial moulds from a case of bronchitis, 115
primary tuberculosis of the kidney in an infant, 136
Hand, Alfred, Jr., aneurism of arch of aorta, 72, 74
Heart, aneurism of, 86, 105, 106, 112
congenital disease of, 83
fat y degeneration and infiltration of, 92
from case of stenocardia, 113
hypertrophy of, 93
polyp of, 85
thrombosis of, 90
valvular disease of, 71, 72, 74, 87, 89, 100, 112, 133
Henry, F. P , thoracic aneurism, 87
Hughes, G E., series of ovarian and uterine specimens, 131
W. E., apical phthisis and double tubercular pleurisy in an infant, 114
atrophic nephritis, 151
carcinoma of the colon, 52
of the stomach, 58
cerebral tuberculoma, 145
discussion, 25, 41
fibroid liver and pancreas, 69
glandular and circulatory system (in diphtheria), 280
hydatid cyst of the liver, 53
pernicious anæmia, 75
primary cancer of the gall-bladder, 9
sarcoma of kidney, 135
Hydatid cyst of liver, 53
Hydrocephalus, 162

IMPACTED gallstones, dilatation of biliary ducts, 10
Intermittent fever, specimens from a case of, of hepatic origin, 65
Intrathoracic tumors, series of, 173, 188
Intussusception, 42

JAMISON, W. B., discussion, 212
Jurist, Lewis, discussion, 203

KELLEY, A. O. J., chronic nephritis and tubercular pyelitis, 153
duodenal ulcer, 68
heart from a case of stenocardia, 113
primary cancer of gall-bladder, 56
Kidney, abscess of, 141
calculi of, 141
sarcoma of, 135
"single," 141
tuberculosis of, 142
of, primary, 136
Kirkbride, T. S., Jr., phlebitis of ascending vena cava, 107
Kyle, D. B., physicians' and surgeons' bacteriological case, 209

LAINE, T. M., discussion, 25
heart of a child two weeks of age, with a patulous foramen ovale, a triangular opening in the ventricular septum, and a small and contracted aortic opening in which no valves could be detected, 83
ileum and colon from a case of acute infectious colitis, 24
Larynx, carcinoma of, 119
perichondritis of, 120
Leidy, Jos., discussion, 106
oestrus humanus Humboldt, 312
Leonard, Chas., discussion, 99
Lincoln, C. W , cerebellar abscess, 167
Liver, abscess of, 15, 40
carcinoma of, 26, 35
cirrhosis of, 19, 27, 69
cyst of, hydatid, 53
diminutive, from infant, 53
Lloyd, J. H., appendicitis caused by lodgement of a pin in the appendix, with secondary multiple abscesses of liver, 40
brain tumor in postero-parietal region, 161
Lung. abscess of, 29
emphysema of, 114
glanders of, 253
sarcoma of, 182, 184

McFARLAND, abscess of cerebellum, 167
discussion, 15, 28, 126, 249
fibrous tumor of the receptaculum chyli, 204
preparation of the diphtheria antitoxin, 263
ulceration of the vagina and cervix, the latter carcinomatous, 138

McKee, J. H., organs from a case of general tuberculosis in a child, 232
Meckel's diverticulum, 24
Mediastinum, cancer of, 179
sarcoma of, 180, 202
tumors of, series. 173, 188
Meigs, A. V., aneurism of arch of aorta, 71
discussion, 18, 22
president's annual address, 1
Metastasis of cancer of breast, 138
Miller, D. J. M, carcinoma of œsophagus, abscess of lung, pyopneumothorax, 29
cirrhosis of liver, 27
discussion, 52
primary cancer of pancreas with hour-glass constriction of the stomach, simulating during life pyloric stenosis, 61
Mills, C. K., two cases of spinal hemorrhage and a case of cerebral hemorrhage. 164
Miner, C. H., intussusception, rupture of bowel, abscess of peritoneum, 42
Mitchell, J K., uterus and ovaries from a case of peritonitis from rupture of an ovarian cyst, 147
Mitral disease, 99, 100
Mucus casts from bowel, 50
Musser, J. H., cancer of cæcum, 10
of liver and stomach, 35
discussion, 11, 24, 41, 44, 52, 53, 59, 80, 99, 204, 210
president's annual address, 3

NEPHRITIS, 65, 111, 123, 134, 151, 153, 235
in typhoid, 23
Neuritis, 169
Nervous symptoms and lesions of diphtheria, 284

ODONTOID process of axis, caries of, 7
Œsophagus, cancer of. 18, 28
Oestrus humanus Humboldt, 312
Ovary, cyst of, 147, 155
from case of peritonitis, 147
sarcoma of, 131
series of specimens of, 131
tumor of (?), 129

PACKARD, F. A., cancer of stomach, 55
cardiac polyp, 85
discussion, 41
Packard, F. A., intermittent fever of hepatic origin, aortic obstruction, chronic nephritis, 65
rheumatic pericarditis, 71
three cases of intrathoracic tumor; cystic substernal goitre; sarcoma of anterior mediastinum; primary endothelioma of pleura, 188
F. R, ulcer of the bladder in a patient dying with some of the symptoms of Raynaud's disease, 147
Pancreas, cancer of, 61
cirrhosis of, 69
Pearce, F. S., cancer of the breast, 125
further report of an intercanalicular fibroma of the right mammary gland, 157
"single" kidney the seat of abscess and multiple calculi, 141
thrombosis of femoral artery, 80
tubercular pleurisy, 116
Pericarditis, 71, 77, 95, 111
Peritoneum, abscess of, 42
Phlebitis of ascending vena cava, 107
Pleura, endothelioma of, 185, 199
Pleurisy, tubercular, 114, 116
Pneumonia, 114
Polyp, cardiac, 85
Pott's disease, spinal cord from case of, 163
Pregnancy, tubal, 146
Price, Jos., series of ovarian and uterine specimens, 131
Prostate, enlargement of, 123
Psommomata of choroid plexus, 159
Purpura hemorrhagica, 235
Pyelitis, tubercular, 153
Pyopneumothorax, 29
Pyosalpinx, 131

RANDALL, B. A., the nose, eye, and ear (in diphtheria), 282
Raynaud's disease. 147
Receptaculum chyli, tumor of, 204
Respiratory system in diphtheria, 276
Riesman, D, a case of primary sarcoma of the spleen with extensive metastasis, 250
calcareous concretion from the tonsil, 59
cancer of breast of unusually long duration, 152
discussion, 162
organs from a case of general tuberculosis in a child, 232
perforating gastric ulcer in a man of fifty years, 45
sections of multiple neuritis, 169

SARCOMA of kidney, 135
of lung, 182, 184
of mediastinum, 180, 193, 202
of ovary, 131
of spleen, 250
of thymus, 175
of uterus, 142
retroperitoneal, 172
Scott, J. A., discussion, 18, 41, 60, 82, 87, 127
miliary tuberculosis, 210
Sedgwick, Dr., fibroid liver and pancreas, obstruction of bile-duct, 69
Skin, fibroma of, 207
Skull, fracture of base, 160
Spinal cord from case of Pott's disease, 163
hemorrhage, 164
Spleen, miliary tuberculosis of, 210
sarcoma of, 250
Sponge-grafting, conjunctival, 246
Steele, J D., amœbic abscess of liver, 38
carious odontoid process of axis and ulcerative destruction of transverse ligament, 7
pericarditis with effusion, 79
Stengel, Alfred, adenoma and fibroma of stomach, 50
cirrhosis of liver in a boy; malarial origin (?), 19
discussion, 99
pulmonary emphysema with pneumonia, 114
series of cases of intrathoracic tumors, 173
thrombosis of left ventricle, 90
valvular disease and beginning aneurism of the heart, 112
Stenocardia, heart from case of, 113
Stomach, adenoma of, 50
carcinoma of, 12, 26, 35, 55, 58
fibroma of 50
from case of creosote-poisoning, 23
hour-glass constriction of, 61
ulcer of, 45
Swan, J. M., abdominal tumor, probably of ovarian origin, 129
cardiac hypertrophy, 93
fibroma of skin from back of neck, 207
tubercular kidney, 142
typhoid fever with nephritis, 23

THOMAS, W. H., papillomatous ovarian cyst, 155
pericarditis with nephritis, 111
Thompson, A. G., a case of accidental sponge-grafting on the conjunctiva of eighteen months' duration, 246
Thrombosis of femoral artery, 80
of left ventricle, 90
Thymus gland, sarcoma of, 175
Tonsil, calcareous concretion from, 59
Toxalbumins, pathological changes caused by certain so-called—an experimental study, 212
Transverse ligament of axis, ulcerative destruction of, 7
Trichomonas as a parasite of man, 287
Tricuspid disease, 100
Typhoid fever with nephritis, 23
Tuberculosis, general, 232
miliary, 210, 231
of cerebellum, 168
of kidney, 136, 142, 153
of pleura, 114, 116
pulmonary, 26, 114

ULCER of bladder, 147
of cervix uteri, 138
of duodenum, 68
of stomach, 45
of vagina, 138
Ulcerative endocarditis, 84
Uterus, carcinoma of, 138
enlarged veins of, 151
fibroid of, 127, 132
from case of peritonitis, 147
sarcoma of, 142
series of specimens of, 131

VAGINA, ulceration of, 138
Valvular disease of heart, 71, 72, 74, 87, 89, 100, 112 133
Vandervort, C. A., two cases of spinal hemorrhage and a case of cerebral hemorrhage, 164
Van Sant, E. L., cancer of pylorus, 12
Variola, pustules from case of, 209
Veins, enlarged uterine, 151
Vena cava, phlebitis of, 107

WESTCOTT, T. S., discussion, 18
traumatic pyopericardium in a child of six months, 95
Willard, De Forest, appendicitis caused by the lodgement of a pin in the appendix, with secondary multiple abscesses of the liver, 40
Wolff, Lawrence, discussion, 23, 28

ZIMMER, JOHN, carcinoma of liver and stomach, 35

This Book is due on the last date stamped below. **No further preliminary notice will be sent.** Requests for renewals must be made on or before the date of expiration.

| DUE | RETURNED |
| --- | --- |
| NOV 23 1937 | NOV 18 1937 |

A fine of twenty-five cents will be charged for each week or fraction of a week the book is retained without the Library's authorization.